



DR. SAMUEL HAHNEMANN
GERMANY

FEMALE RELATED PROBLEMS

Vision of Impossible to Possible

**Treatment of
Incurable Diseases
Like Cancer, Kidney
Failure, Coma, Surgical,
Autoimmune, Life Style
& Life Threatening
Diseases**

PROF. DR. ARPIT CHOPRA JAIN

**M.D Homoeopathy
Critical and Surgical Disease Specialist (India)**

**INVENTOR OF
AAROGYA SUPER SPECIALITY MODERN HOMEOPATHY**

COMPLETE, EASY SAFE, FAST & COST-EFFECTIVE CURE



Dr. Arpit Chopra Jain M.D Homeopath

Critical and Surgical Disease Specialist

Dr. Arpit Chopra Jain: Transforming Global Healthcare with Aarogya super Speciality Modern Homeopathy.

Dr. Arpit Chopra Jain, a pioneer in advanced homeopathic medicine, is set to present groundbreaking clinical data comprising over 3,000 successfully treated cases of critical and surgical diseases — all cured without the need for surgery. This revolutionary treatment approach, developed and practiced exclusively by Dr. Jain, utilizes high-potency homeopathic medicines formulated by him, offering fast, safe, and side-effect-free results.

With over 21 years of experience, Dr. Jain has dedicated his life to providing an alternative yet powerful medical solution that not only preserves the body's original organs but also ensures deep, lasting cures. **His work has gained national and international recognition. He has been honored by India's Vice President, Defense Minister Shri Rajnath Singh, Health Minister Shri J. P. Nadda, and several other dignitaries.** In acknowledgment of his contributions, he has also received a prestigious honorary doctorate from the USA.

Dr. Arpit Chopra Jain proudly represents India on the international stage as the **Homeopathic Representative for BRICS (Russia)** and continues to raise the global profile of homeopathy through his one-of-a-kind center based in Indore, Madhya Pradesh, India. From this single center, he has reached and treated patients from over 19 countries, offering remote consultations and delivering life-changing results globally.

Recently, **Dr. Jain was invited as the Guest of Honor at the highly esteemed United Nations Global Excellence Awards held at the UN Headquarters in New York, hosted by the United Nations Global Peace Council.** This momentous occasion was a testimony to his relentless commitment and global vision for homeopathy.

His work is supported by real, verifiable patient testimonials, including pre- and post-treatment reports, available on his official website and YouTube channel. These authentic stories reflect the effectiveness and rapid healing power of his treatment.

This book is a humble attempt to introduce Dr. Jain's extraordinary journey and his mission — to make the world healthier without surgery, promoting natural healing through scientifically advanced homeopathic medicine. His goal is to create a safer, more cost-effective, and organ-preserving healthcare alternative for patients across the globe.





The identity of any person is his real wealth.

INTRODUCTION

Inventor of Aarogya Super Speciality Modern Homoeopathy, revolutionized treatment for complex diseases

Professor Dr. Arpit Chopra Jain

Professor Dr. **Arpit Chopra Jain**, with over 20 years of medical experience and research, has revolutionized classical homeopathy by developing a future-oriented, super-speciality modern homoeopathy treatment system. His innovative approach has given new physical, mental, and social life to thousands of patients who were once considered incurable, including those suffering from nearly 300 different diseases such as cancer, kidney failure, coma, aplastic anemia, and other serious conditions requiring surgical intervention. In doing so, he has also fulfilled the World Health Organizations (WHO) belief that true health encompasses physical, mental, and social well-being.

Originally from Chhattisgarh, Dr. Arpit Chopra Jain received his primary education in his home state before moving to Indore to pursue a Bachelors degree in Homeopathy. After completing his BHMS, he earned an MD in Homeopathy from DKMM Homoeopathic Medical College in Aurangabad, Maharashtra. During his studies and career, he worked alongside many renowned allopathic doctors in Indore and other locations, acquire practical experience and contributing to medical advancements.

Currently, Dr. Arpit Chopra Jain is providing medical services through the Aarogya Super Speciality Modern Homoeopathy Clinic, located at Janjirwala Square in Indore, where he leads a team of experienced professionals. In addition to his clinical work, Dr. Arpit Chopra Jain plays a pivotal role in shaping homeopathic education as an educator at RN Kapoor Homoeopathic Medical College. His research focuses on complex blood-related diseases, including aplastic anemia and sickle cell anemia.. Driven by a commitment to innovation, Dr. Jain has been nationally and internationally recognized for his groundbreaking contributions to the treatment of complex and incurable diseases. His exceptional service during the COVID-19 pandemic further highlights his dedication to advancing modern homeopathic medicine.

Many of Dr. Arpit Chopra Jain's patients regard him as a godsend, praising his unwavering commitment to serving humanity. Beyond his medical practice, Dr. Arpit Chopra Jain, who hails from a family of 19 physicians, is making significant contributions to society and the Nation.

He firmly believes that Aarogya Super Speciality Modern Homoeopathy - instant, effective, affordable, and without side effects is the future of homoeopathy. While homoeopathy may have originated in Germany, Dr. Arpit Chopra Jain is confident that India's revolutionary modern homoeopathic medical system will one day be recognized globally, inscribing India's name in golden letters on the world health chart. He and his team are making every possible effort to achieve this vision and will continue to do so.



Golden India's Revolutionary Discovery: Pioneering the Future of Healthcare with Advanced Homoeopathy

Homoeopathy, a system of alternative medicine established over 200 years ago by German physician Dr. Samuel Hahnemann, has experienced widespread adoption across various countries, including India. However, over time, it faced criticism and was even banned in certain regions due to persistent myths and misconceptions, such as its alleged placebo effect. Critics claimed that homoeopathic remedies were ineffective, slow to act, and not backed by scientific evidence, leading to widespread skepticism among both the public and the scientific community.

One significant issue was that classical homoeopathy relied heavily on treating patients based on symptoms alone, without extensive clinical documentation or diagnostic reports. This absence of empirical evidence made it challenging to validate its effectiveness through conventional medical research methods.

In response to these challenges, Dr. Hahnemann later developed a more potent form of homoeopathic medicine, known as the 50 millesimal potency, or 5 million power. However, by the time this advancement was introduced, classical homoeopathy had already established deep roots, and the lack of continued research, documentation, and clinical validation led to its gradual decline in some regions.

Recognizing the need to address these limitations, Professor Dr. Arpit Chopra Jain, with over 20 years of clinical and hospital experience, pioneered a groundbreaking approach known as Super Speciality Modern homoeopathy. Utilizing the powerful 50 lakh potency homoeopathic medicines, along with mother tinctures, biochemic treatments, and dilutions, Dr. Jain's revolutionized the practice by effectively treating severe autoimmune conditions, including cancer, kidney failure, aplastic anemia, sickle cell anemia, rheumatoid arthritis, ankylosing spondylitis, and many other life-threatening illnesses. This innovative treatment approach has produced remarkable results, enabling patients suffering from complex and incurable diseases to recover without any side effects or lifelong medication dependency. Dr. Jain's method has proven particularly effective in cases previously deemed untreatable, such as patients in comas, those with brain tumors, or those in the terminal stages of illness.



His success extends beyond India, benefitting patients in countries such as Pakistan, Dubai, Bangladesh, the United States, and the United Kingdom.

A key differentiator of Super Speciality Modern Homoeopathy is its integration of clinical pathology alongside traditional symptom-based diagnosis. Dr. Jain's has meticulously collected pre- and post-treatment test reports from over 3,000 successfully treated patients, along with their written testimonials and interviews, both online and offline. This substantial body of evidence aims to secure recognition for his treatment methodology within the broader medical community, ensuring future generations of homoeopathic practitioners can offer hope to patients who might otherwise remain hopeless.

Dr. Jain's innovative work continues to shape the future of homoeopathy providing a new path forward for both patients and healthcare providers worldwide.



Complete Cure, Permanent, Easy, Safe, Fast, Cost Effective.

Aarogya Super Specialty Modern Homoeopathy -

It is a modern medical science which incorporates the basic nature of homoeopathy and keeps it as its basis and includes many other new features.



Easy Method -

In Aarogya Super Speciality Modern Homoeopathy, a variety of homoeopathic medicines are utilized, including decimal potency, centesimal potency, 50 millesimal potency, mother tinctures, biochemic medicines, The method of administering these medicines is straightforward and can be easily followed in the prescribed dosage under the guidance of a qualified homoeopathic doctor. One of the unique aspects of Aarogya Super Speciality Modern Homoeopathy is that it does not work with the traditional restrictions often associated with homoeopathic treatment, such as avoiding strong-smelling substances during medication. Due to the high quality and potency of the medicines used, these minor misconceptions hold no relevance in this advanced system of treatment. This approach allows for effective treatment without the need for strict dietary restrictions, making it more accessible and easier for patients to adhere to. Aarogya Super Speciality Modern Homoeopathy excels in providing top-tier treatment with minimal medication, even for complex and difficult-to-treat conditions. In this system, various diseases are treated directly and comprehensively, whether through homoeopathic medicines alone or in combination with supportive medicines from other medical systems, depending on the patients condition and the nature of the disease. This holistic approach ensures that patients receive the most effective and personalized care

Harmless Medical Method -

One of the most remarkable aspects of Aarogya Super Speciality Modern Homoeopathy is its safety profile, even when high potencies are used. Unlike conventional treatments where the risk of side effects increases with the dosage of active ingredients, homoeopathic medicines are carefully prepared through a process called potentiation. In this process, the original substance is diluted while simultaneously increasing its potency. This unique method ensures that only a minimal amount of the chemical or raw material remains in the final product. As a result, Aarogya Super Speciality Modern Homoeopathy offers highly effective treatments without the risk of harmful side effects. The approach is practically unmatched in other branches of medical science, where larger doses of active substances can often lead to adverse reactions. In this way, modern homoeopathy provides a safe and natural healing method, making it an ideal option for individuals seeking a harmless yet potent solution to their health issues.

Fast Aggressive Treatment -

One of the most remarkable aspects of Aarogya Super Speciality Modern Homoeopathy is its fast and aggressive healing process, setting it apart from conventional homoeopathy. In this advanced system, medical expertise is combined with cutting-edge technology, including computerized software, to ensure rapid, accurate diagnosis and treatment. Doctors utilize a vast array of over 4,000 potent medicines, with strengths ranging from zero potency to an astonishing 50 lakh potency, making the treatment scientifically robust and effective for a wide range of diseases. The precision of this method allows doctors to quickly gather and analyze detailed information about a patients condition, helping them select the most suitable remedy. This tailored approach ensures that even severe, surgical, or seemingly incurable conditions are addressed efficiently and effectively. What makes this treatment truly revolutionary is its ability to provide fast relief without any side effects, transforming it into a powerful, unique, and highly reliable branch of medical science.

Complete cure of diseases from the root -

Aarogya Super Speciality Modern Homoeopathy aims to heal the patient completely body, mind, and soul ensuring not only recovery from current ailments but also preventing the recurrence of diseases throughout life. This holistic approach to treatment is a crucial aspect of any effective medical science.

This fast and aggressive treatment approach embodies the future of homoeopathy, offering hope to patients facing complex diseases while maintaining the core principles of safety, simplicity, and efficacy.

Cost-Effective Treatment with Aarogya Super Speciality Modern Homoeopathy

Despite its advanced and multifaceted approach, Aarogya Super Speciality Modern Homoeopathy remains highly affordable and accessible, making it a preferred choice for many. Compared to other medical systems, it offers a cost-effective solution while providing complete, safe, and test treatment. This affordability, combined with its ability to deliver immediate results without harmful side effects, has contributed to the growing global popularity of modern homoeopathy. Today, homoeopathy is trusted by millions, with affordable medicines available to those in need. Every fourth person in the world now benefits from homoeopathy in some form, relying on its holistic and comprehensive approach to healthcare.



Dr. Arpit Chopra Jain, M.D. in Homoeopathy and the inventor of Aarogya Super Speciality Modern - Homoeopathy, has been instrumental in making this revolutionary treatment accessible to people from all walks of life. His commitment to providing effective, affordable, and harmless treatment has redefined the landscape of healthcare, offering hope and healing to thousands.



Dr. Arpit Chopra (Jain)
 M.D. HOMOEOPATHY
 Inventor of Aarogya Super Speciality Modern Homoeopathy



Aarogya Super Speciality Modern Homoeopathy



Successful Treatment of Critical Health Conditions

Dr. Jain's innovative treatment method has shown exceptional results in managing and curing serious health conditions, including:

- Cancer
- Kidney Diseases
- Coma
- Blood Disorders such as sickle cell anemia and aplastic anemia
- Arthritis
- Autoimmune Diseases
- Neurological Disorders
- Heart Diseases
- Skin Conditions like psoriasis and dermatitis

Through a deep understanding of the body's internal balance, Aarogya Super Speciality Modern Homoeopathy targets the root causes of these diseases, promoting natural self-healing without the need for invasive procedures or lifelong medications.

Revolutionizing Disease Treatment

Aarogya Super Speciality Modern Homoeopathy, developed by Dr. Arpit Chopra Jain, has introduced a groundbreaking, holistic approach to treating a wide range of complex and chronic diseases. This method offers a comprehensive, harmless, cost-effective, and permanent solution, achieving remarkable success where conventional treatments often fall short.

Efficacy Across a Wide Range of Diseases

With a proven record of success in treating nearly 300 different diseases, Aarogya Super Speciality Modern Homoeopathy offers relief from conditions that affect various aspects of health. Patients suffering from:

- Allergies
- Womens Health Issues
- Urological and Gastric Problems
- Rheumatoid Arthritis
- Pediatric Conditions
- Spinal Cord Disorders

have all experienced life-changing results through this pioneering method.



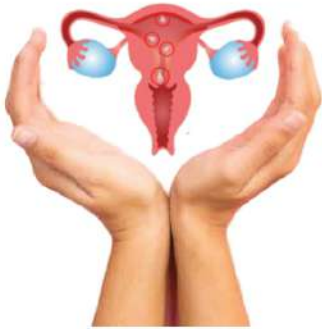A New Lease on Life

What truly sets this treatment apart is its ability to provide lasting and permanent relief. Patients who were previously dependent on lifelong medication or faced invasive surgeries have regained their health, returning to a normal, medication-free life. Aarogya Super Speciality Modern Homoeopathy continues to transform lives, offering a new, holistic approach for those suffering from complex and chronic diseases.

Female related Diseases

Women: The Pillars of Society and Their Health Challenges

Women are the cornerstone of our society, forming the foundation around which homes, families, and communities are built. Often described as the source of strength for the human race, when a woman's health is compromised, it impacts not just her family but the entire fabric of society. A woman's well-being is essential to ensuring the strength and stability of her home, family, and community.



Conventional Treatments and Their Limitations

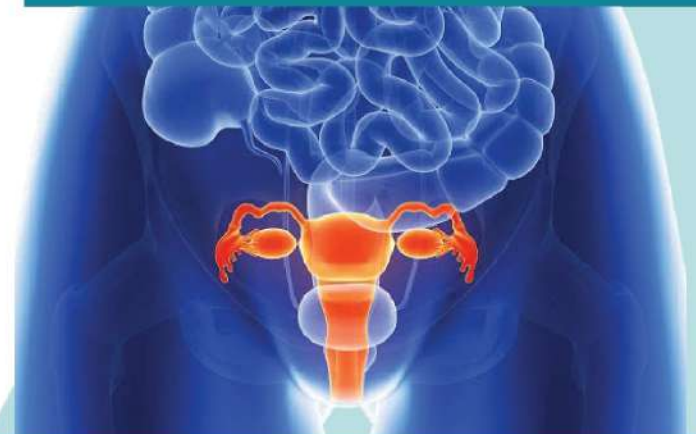
In conventional allopathic medicine, these conditions are typically treated with medications, steroids, chemotherapy, radiotherapy, or surgical interventions. While these treatments can be effective, they often come with significant side effects, leaving patients physically and emotionally drained. Women may feel disheartened by the invasiveness of these treatments and the potential for complications or incomplete recovery. Taking care of women's health is essential not just for individual well-being but for the strength and vitality of the entire community.



Health Challenges Unique to Women

While anyone can face health issues, women often experience more complex and challenging conditions compared to men. Despite their resilience, many women tend to prioritize family responsibilities over their own health, sometimes ignoring early warning signs. As a result, minor health concerns may develop into serious, complex diseases. Some of the most common and serious conditions affecting women include:

- Breast Cancer
- Ovarian Cysts
- Infertility
- Uterine Fibroids and Polyps
- Cervical Cancer
- Fallopian Tube Blockages
- Ovarian Cancer
- Enlarged Uterus
- Polycystic Ovary Syndrome (PCOS)





Dr. Arpit Chopra Jain's Aarogya Super Speciality Modern Homoeopathy: A Beacon of Hope

Dr. Arpit Chopra Jain offers an alternative through his Aarogya Super Speciality Modern Homoeopathy treatment. His approach has brought new hope to women who have struggled with these debilitating conditions. Through his extensive experience and innovative methods, Dr. Arpit Chopra Jain has successfully treated many women who had previously been left frustrated and without options. His treatment not only addresses the root causes of these complex diseases but also restores health and happiness, allowing these women to lead fulfilling lives.



Conclusion

Women play a crucial role in the strength and stability of our society. When their health is compromised, it affects not just them but everyone around them. Dr. Arpit Chopra Jain's Aarogya Super Speciality Modern Homoeopathy offers a promising path to healing for women suffering from complex and serious conditions. His approach not only cures but also revitalizes, allowing women to reclaim their health, happiness, and place as the pivotal force in their families and communities.

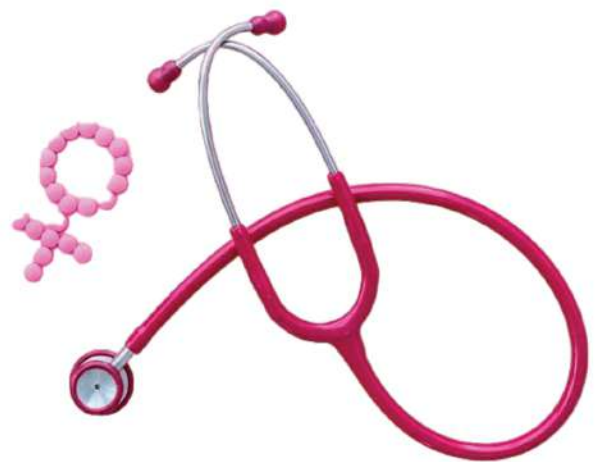Key Benefits of Dr. Arpit Chopra Jain's Treatment

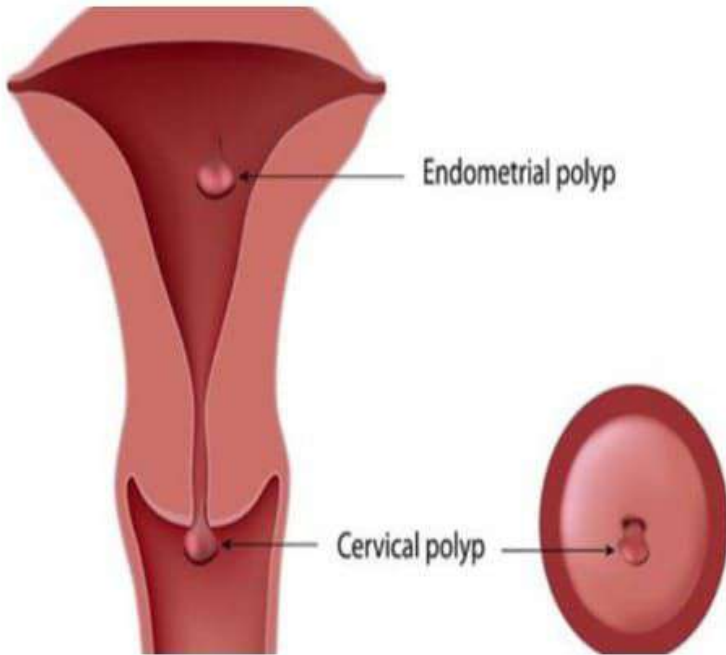
Holistic Healing: Dr. Arpit Chopra Jain's modern homoeopathy focuses on treating the underlying causes of diseases rather than just managing symptoms.

Non-Invasive: Unlike conventional treatments that often require surgery or harsh therapies, homoeopathy is gentle and non-invasive.

Empowering Women: By restoring health, Dr. Arpit Chopra Jain's treatment empowers women to regain control over their lives and families, helping them to fulfil their roles in society with renewed strength and vitality.

Long-Term Results: Patients treated with Dr. Arpit Chopra Jain's methods have reported lasting improvements, reducing the likelihood of recurrence and improving overall quality of life.





आरोग्य सुपर स्पेशलिटी
 माडर्न होम्योपैथिक क्लिनिक (कम्प्यूटाईज्ड)

26 **CERVICAL POLYP**

मम कविता मुंद्रा
 Mobile: 872 06 32530
 Address: 201, Sakate, Indore
 Regd.

I am Kavita Mundra. I have the problem of Cervical Polyp from three months. I met lady doctor vidhya parikhaji. She suggest me the laser. then I met Nitish Dashore. She suggest me to operate Polyp. then I met Dr. Anurag Chandra. He he give me medicine for 1 month. Still get positive. I did Sonography. there was no Polyp in Sonography.

27
 I am happy without operate polyp dissolved. Thanks to Dr. Anurag Chandra
 Cured
CERVICAL POLYP



Central Diagnostic Center
 (KOTWARI DIAGNOSTIC PVT. LTD.)
 Yashwant Plaza, Opposite Railway Station, Indore - 452001 | Call 78699-57952

DEPARTMENT OF RADIOLOGY & IMAGING

Name Of Patient: MRS. KAVITA MUNDRA
 Age/Sex: 42 Y/F
 Date: 06.09.2019
 LHID: 19091700125/3538
 Ref By: DR. SALONI DASHORE, MBBS

USG PELVIS

Uterus is of normal size (measures about 7.9x5.2x4.4cms in dimension) and is normal in shape. The uterine outlines are smooth and regular. The myometrial echopattern is normal. Endometrial echoes are central & 8.5mm in thickness. Cervix is bulky & there are few, (3) tiny 3-5mm nabothian cysts seen in it. A 14x8x8mm echogenic image is seen in cervical canal extending up to the external os (finding are consistent with clinical diagnosis of Cervical Polyp) No intra uterine extension is seen.

Both ovaries are normal in size, shape and echostructure.

No adnexal / pelvic mass.

No localized / free pelvic collection.

Dr. Sonita Sullere, DMRD
 RADIOLOGIST
 Dr. Sonita Sullere
 MRFD, INRD
 Radiologist
 Reg. No. 11230

Central Diagnostic Center
 (KOTWARI DIAGNOSTIC PVT. LTD.)
 Yashwant Plaza, Opposite Railway Station, Indore - 452001 | Call 78699-57952

DEPARTMENT OF RADIOLOGY & IMAGING

Name Of Patient: MRS. KAVITA MUNDRA
 Age/Sex: 42Y/F
 Date: 25/12/2019
 LMD: 5712-19
 Ref By: DR. ANIT CHOPRA

USG FINDINGS:

USG ABDOMEN

LIVER: Measures 15.3cm, normal in size. Parenchyma echo-anatomy is homogenous. Intrahepatic biliary radicals are undilated.

GALL BLADDER: Normal distension, thin walled no calculi seen. CBD and Portal vein is normal in caliber.

SPLEEN: Measures 7.6cms in size. Parenchyma is normal. Spleen hila vessels are undilated.

PANCREAS: Normal in size, all segments show normal parenchyma echo-anatomy. Pancreatic duct is undilated.

RIGHT KIDNEY: Reveal normal size (10.6cms), shape and position. Cortical thickness and echo-anatomy are normal. C/M differentiations fair. Pelvi-calyceal systems are undilated. Right ureter is undilated.

LEFT KIDNEY: Reveal normal size (11.3cm), shape and position. Cortical thickness and echo-anatomy are normal. C/M differentiations fair. Show 4mm calculus in mid calyx. Pelvi-calyceal systems are undilated. Left ureter is undilated.

LMP: 06/12/2019.

URINARY BLADDER: Thin walled, normal distension and no calculus is visualized.

UTERUS: Measures 8.0 X 4.0cms in size, myometrium shows normal echioanatomy. Endometrial thickness is 11mm, cervical canal and vagina are normal.


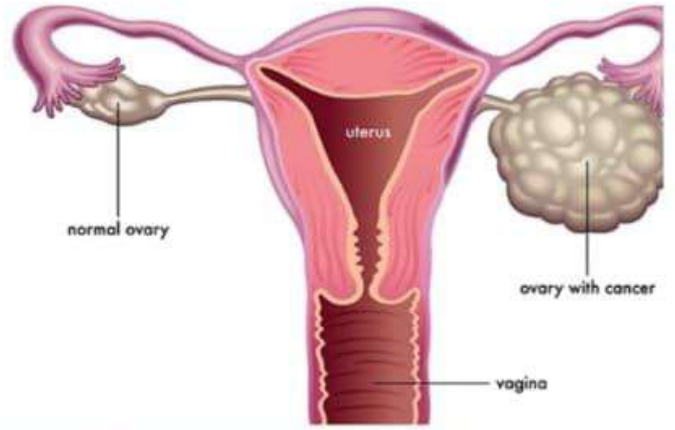
RIGHT OVARY: normal in size. No dominant follicle is seen.

LEFT OVARY: normal in size. No dominant follicle is seen.

Cul-de-sac is clear.

USG INTERPRETATION: (1) LEFT RENAL CALCULUS.

Dr. Jagdish Kumar Gupta
 M.D. (IMCologist)
 Reg.No.5254



Ovarian cancer

OVERVIEW SYMPTOMS TREATMENTS SPECI

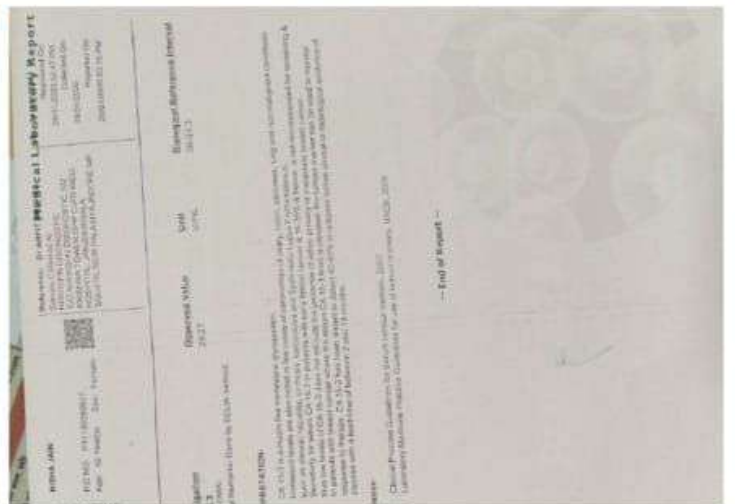


A cancer that begins in the female organs that produce eggs (ovaries).

Ovarian cancer often goes undetected until it has spread within the pelvis and stomach. At this late stage, ovarian cancer is more difficult to treat and can be fatal.

Rare

Fewer than 1 million cases per year (India)

- Treatable by a medical professional
- Requires a medical diagnosis
- Lab tests or imaging always required



Polycystic ovary syndrome

Also called: PCOS

OVERVIEW SYMPTOMS TREATMENTS SPECIAL

A hormonal disorder causing enlarged ovaries with small cysts on the outer edges.

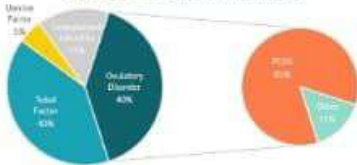The cause of polycystic ovary syndrome isn't well understood, but may involve a combination of genetic and environmental factors.

Common

More than 1 million cases per year (India)

- Treatment can help, but this condition can't be cured
- Requires a medical diagnosis
- Lab tests or imaging always required
- Chronic: can last for years or be lifelong

Causes of Female Infertility



PCOS is the primary cause of hyperandrogenism and oligo-anovulation at the reproductive age and is often associated with infertility³ and clinical and metabolic disorders⁴. The prevalence of infertility in women with PCOS varies between 70 and 80%.

Also, conditions common to PCOS like metabolic syndrome and increased androgens may increase the risks affecting infants. Pregnancy complications related to PCOS include: Miscarriage or early loss of pregnancy. ... Some research shows that metformin may reduce the risk of miscarriage in pregnant women with PCOS. Jan 31, 2017

AAROGYA SUPERSPECIALITY MODERN HOMOEOPATHIC CLINIC

Dr. Arpit Chopra (Jain)
(MD HOMOEOPATHY)
CRITICAL & SURGICAL DISEASES SPECIALIST
Reg. No. 14367

Phone : 0731-4977076
Mobile : 97130-92737, 97130-37737
79999-78894, 99075-27914

Website : www.homoeopathyure.com / in
www.aarogyahomoeopathyindore.com

102, First Floor Krishna Tower
In Front of Curewell Hospital
Janjeer Wala Square, INDORE (M.P.)

Time : Morning : 10 am to 3 pm
Evening : 05 pm to 10 pm
Sunday : 12 am to 3 pm

Email : arpit Chopra23@gmail.com
www.aarogyahomoeopathyindore.com

Complete, Easy, Safe, Fast & Cost-effective Permanent Modern Homoeopathy Cure With Advanced Lifestyle

Name _____ Address _____

Dr. Arpit Chopra (Jain)
M.D. HOMOEOPATHY
(Critical & Surgical Diseases Specialist)

Complete, Easy, Safe, Fast & Cost-effective Permanent Modern Homoeopathy Cure With Advanced Lifestyle
102, First Floor Krishna Tower in front of Curewell Hospital
Janjeer Wala Square, INDORE (M.P.)
Time : 10 am to 3 pm & 5 pm to 10 pm, Sunday : 12.00 am to 2.00 pm
Please Take Appointment Before Consultancy as Possible, Ph:- 0731-4977076
www.homoeopathyure.com, Email - arpit Chopra23@gmail.com

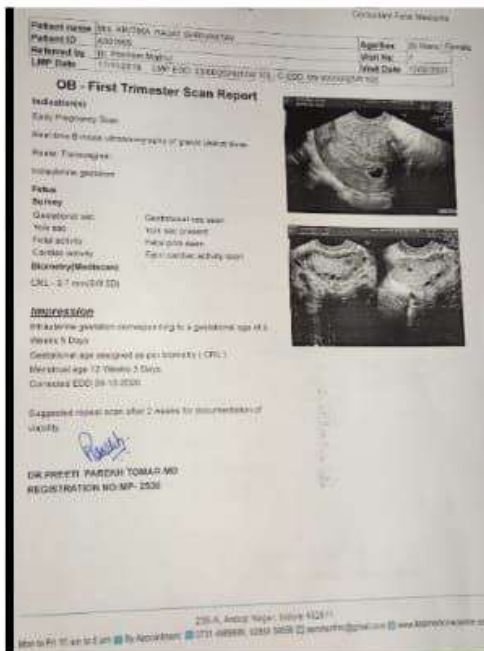2020 FEBRUARY

Name - Kartika Shrivastava

I started identifying the symptoms of PCOD and monthly cycle delay immediately after my marriage. The size of cysts was not higher. Then I came to know about Dr. Arpit Chopra. I started taking medicines from him and also went for sonography on regular intervals. The cysts went down rapidly & also my monthly cycle started coming on time. Few positions changed also met me regarding my health and today I am happy with pregnant Kartika 9009/99992 (Bopal, Indore)

PCOD/PCOS with pregnant using Infertility
REP. - 0731-4977076

Appointment



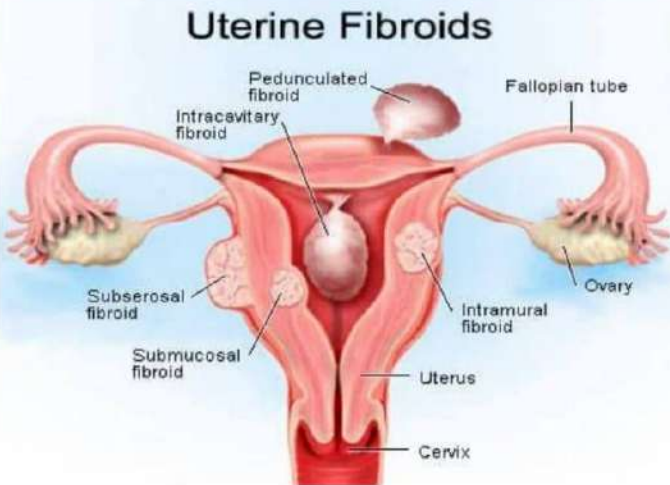
Fibroids

Also called: Uterine myoma

OVERVIEW SYMPTOMS TREATMENTS NEWS

Non-cancerous growths in the uterus that can develop during a woman's childbearing years.

The cause of fibroids isn't well understood. Risk factors include a family history of fibroids, obesity or early onset of puberty.



Dr. Arpit Chopra (Jain)
M.D. HOMOEOPATHY
 (Critical & Surgical Diseases Specialist)

आरोग्य
 MODERN
 HOMOEOPATHY

9907527914, 9713037
 9713092737, 799997

AAROGYA SUPER SPECIALITY MODERN HOMOEOPATHIC CLINIC

Complete, Easy, Safe, Fast & Costeffective
 Permanent Modern Homoeopathy Cure With Advance Lifestyle
102, First Floor Krishna Tower In front of Curewell Hospital
Janjeer Wala Churaha, INDORE (M.P.)
Time : 10 am to 3pm & 5 pm to 10 pm, Sunday : 12.00 am to 2.00 pm
Please Take Appointment Before Consultancy as Possible, Ph.: 0731-4977
 www.homoeopathy.cure.in, Email - arpitchopra23@gmpil.com

Aarogyahomoeopathyindore.com

down town hospital ltd.
 (Sankardev Path, Dispur, Guwahati) 781006, Assam (India)
 Ph. (0361) 2331033, 76707761, 2-3, 94356 12999, 134 82801 2331024
 E mail: dth@downtownhospitals.org, Visit: www.downtownhospitals.in

DEPARTMENT OF RADIOLOGY

SI No	R/217844	Patient No	Report Date	13/01/2020
Scan No	932	OPD695741	Age/Sex	52Y / Female
Patient Name	MRS RUPA HAZARIKA	Cabin / Orgn	/ ESCHS	
Ref. By	DR. Munindra Sharma	Film No	532	
Inv. Time	11/01/2020 02:20 PM	Report Time	13/01/2020 10:51 AM	TAT 1 day 20 hour 30 min 59 sec

CEMR PELVIS

- PROTOCOL:** MR imaging of the Pelvis was performed and T1 and T2 weighted serial sections obtained in the sagittal, axial and coronal planes using a 8 channel dedicated torso-array surface coil and respiratory compensation on a 1.5 T scanner.
- The uterus is enlarged and shows large well capsulated SOL in the anterior body and fundus showing heterogeneous signal intensity with predominant T2 hypointensity. The lesion measures 117x85x85 mm (craniocaudal x AP x transverse dimensions)—suggests intramural myoma. On administration of contrast there is heterogeneous enhancement. The endometrial lining is thin and displaced posteriorly. No intraluminal collection is seen. Peri-uterine areas are clear. Cervix is normal without any focal signal intensity alteration is seen.
- Both ovaries are normal in size and signal intensity. The right ovary is adherent. The left ovary is normal in size. No solid or cystic lesion is seen in the ovaries. Right ovary measures 27x16 mm. Left ovary measures 24x19 mm.
- Adnexal areas show normal structures and signal intensities. No adnexal mass lesion seen.
- Intervening fat planes are maintained.
- Urinary bladder is normal.
- No adenopathies are appreciable. No free fluid is seen.
- Parietal soft tissue structures appear normal.

Impression:

- Features are suggestive of large intramural uterine leiomyoma with intact periuterine fat planes. No free fluid or pelvic lymphadenopathy.

Radiologists:

DR. V RAJCONWAR, MD Consultant
 DR. B.J. SARMAH, MD Consultant
 DR. P. K. SARMA, DMRD Consultant
 DR. INDRANI DEORI, MD Consultant
 D.E.C. ARIFA ISLAM

DR. M. K. BINGHA, MD Consultant

Before treatment report

STARLAB
 CHRISTIAN PATTY, NEAR CHURCH, A.D.P. ROAD, HOGAON - 782061
 Phones : 03672 - 235842 ; 236247 (Clinic) 237727 (999)

Ms. Rupa Hazarika
 Ref by: Dr. M Sarman
 Port scanned: USG abdomen + TVS
 May 5, 2020

REPORT:

The liver is normal in size. The echotexture and echotenuities of liver are normal. The intrahepatic biliary ducts are normal. The portal and hepatic veins are normal. No SOL is seen in liver.

The Gall bladder is well distended. The wall thickness of Gall bladder is normal. No calculi are seen in Gall bladder.

The extra hepatic biliary ducts are normal. The CBD measures 3.9 mm. No calculi detected in CBD.

The echotexture of pancreas and spleen are normal.

The size of right and left kidneys are normal. The peri-calyceal systems of both kidneys are normal. No Calculi are seen in kidneys.

No axillar nor paraxillar lymphadenopathy seen.

PELVIC ORGANS (For abdominal & TVS)

The uterus is bulky measures approx 148.2 mm X104.9 mm X 78.6mm. Normal endometrial strip is not visualized. A hypoechoic lesion measuring approx. 89mm X 50 mm is centrally inside uterus. A thick hyperechoic capsule like structure seen around the hypoechoic lesion.

Ovaries are not visualized.

No free fluid is seen in P.O.D.

The urinary bladder is normal.

PROVISIONAL IMPRESSION: UTERINE MASS (D/D: 1. FIBROID; 2. ENDOMETRIAL GROWTH WITH HEMATOMA / INFLATED MATERIALS INSIDE)

Advised: Ca125.

Post Modern Homoeopathy Treatment Report

Dr. B. K. Hazarika, Consultant Radiologist

Discrepancy in typing error if detected should be sent for correction.

SODANI DIAGNOSTIC CLINIC ISO: 9001:2008
 HQ.: L.G.-1, Morya Centre, Opp. Basket Ball Club, 161, Race Course Road, Indore (M.P.) ☎ 0731-682-0281

Patient's Name: **Mrs. Indu Verma**
 Age / Sex: 50 Years / FEMALE
 Referred By: Dr. Chopra Arpit (Jain) MD(Honors)
 Company: NA

Visit #: 1016149096
 Reg Date: 30/07/2016
 Reported: 30/07/2016 17:48

WHOLE ABDOMEN SONOGRAPHY

Hepatic contour is smooth & span is normal. Parenchymal echotexture is normal. No focal lesion is seen. Intrahepatic biliary radicles are undilated.

Gall bladder is normally distended. Walls are thin. No sludge & calculi seen. No peri GB collection is noted.

Portal vein & CBD are normal in caliber.

Pancreas is not visualized due to gases.

Spleen is normal in size. No focal lesion seen.

Both kidneys are normal in position & size. Right kidney is 10.0 x 3.2 cm & left is 10.5 x 4.0 cm in size. Renal contour is smooth. Cortical echoes are normal. Pelvic/ureteral system is undilated. Both ureters are undilated. No calculi seen at PUJ & UVJ.

Urinary bladder shows normal walls & echofree lumen. No intra luminal lesion or calculi seen.

Uterus is anteverted & enlarged in size. It measures 10.7 x 6.5 x 8.2 cm. A large 5.2 x 4.8 cm sized fibroid seen at fundus. Endometrium is thin.

Both ovaries are normal in size.

No free fluid seen in cul-de-sac.
 No significant Ascites. No pleural effusion. No significant lymphnodes are noted.

[Impression]:
 - No hepatobiliary lesion seen.
 - Normal renal echoanatomy with undilated collecting system.
 - Enlarged uterus with large fibroid.
 - Normal ovaries.
 Clinical correlation / followup suggested

DR.S. MAITRA MD
 DR.R.K.SODANI MBBS DMRD

Printed on: 30/07/2016 17:48
 Authorized by: SONI CHACKO
 e-mail: sodani@sampumadiagnostics.com - www.sampumadiagnostics.com

RANCHES: Indore • Ujjain • Dewas • Sanwer • Khandwa • Khargone • Badwani • Dhar • Mhow • Shujalpur

SODANI DIAGNOSTIC CLINIC ISO: 9001:2008
 HQ.: L.G.-1, Morya Centre, Opp. Basket Ball Club, 161, Race Course Road, Indore (M.P.) ☎ 0731-682-0281

Patient's Name: **Mrs. Indu Verma**
 Age / Sex: 50 Years / FEMALE
 Referred By: Dr. Chopra Arpit (Jain) MD(Honors)
 Company: NA

Visit #: 1016149096
 Reg Date: 30/07/2016
 Reported: 12/11/2016 11:50

WHOLE ABDOMEN SONOGRAPHY

Hepatic contour is smooth & span (12.2 cm) is normal. Parenchymal echotexture is normal. No focal lesion is seen. Intrahepatic biliary radicles are undilated.

Gall bladder is normally distended. Walls are thin. No sludge & calculi seen. No peri GB collection is noted.

Portal vein & CBD are normal in caliber.
 Pancreas is normal in shape & size. Parenchymal echoes are normal.
 Pancreatic duct is undilated.

Spleen is normal (7.0 cm). No focal lesion seen.

Both kidneys are normal in position & size. Right kidney is 9.0 x 4.7 cm & left is 9.6 x 5.3 cm in size. Renal contour is smooth. Cortical echoes are normal. Pelvic/ureteral system is undilated.

Both ureters are undilated. No calculi seen at PUJ & UVJ.

Urinary bladder shows normal walls & echofree lumen. No intra luminal lesion or calculi seen.

Uterus is anteverted & bulky. It measures 10.0 x 5.8 x 6.2 cm. Myometrium is heterogeneous. Cervix is normal. Endometrium is 8 mm.

Bilateral adnexa appears clear.

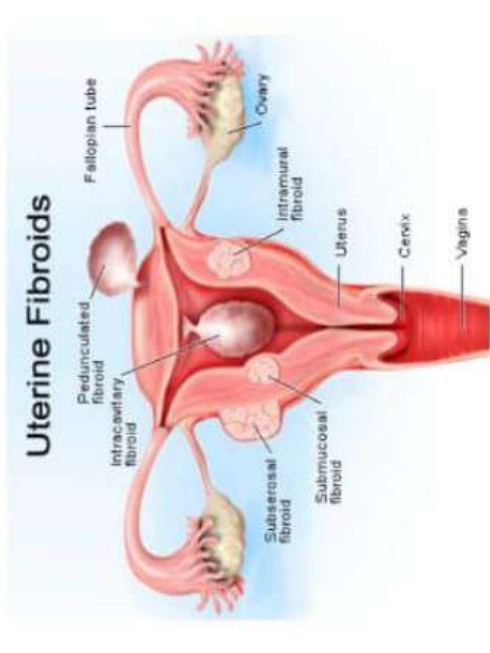
No free fluid seen in cul-de-sac.
 No significant Ascites. No pleural effusion.
 No significant bowel wall thickening / dilatation or lymphnodes are noted.

[Impression]:
 - No hepatobiliary lesion seen.
 - Normal renal echoanatomy with undilated collecting system.
 - Bulky uterus with heterogeneous myometrium (7 isoechoic fibroid occupying whole uterine body). (old H/o fibroid)
 Clinical correlation / followup suggested

DR.R.K.SODANI MBBS DMRD
 DR. SANAT MUKHERJEE MBBS DMRD

Printed on: 13/11/2016 11:50
 Authorized by: VARSHNA
 e-mail: sodani@sampumadiagnostics.com - www.sampumadiagnostics.com

RANCHES: Indore • Ujjain • Dewas • Sanwer • Khandwa • Khargone • Badwani • Dhar • Mhow • Shujalpur




Dr. Arpit Chopra (Jain)
 M.D. HOMOEOPATHY
 (Critical & Surgical Diseases Specialist)

AAROGYA SUPER SPECIALITY MODERN HOMOEOPATHY

Complete, Easy, Safe, Fast & Costeffective
 Permanent Modern Homoeopathy Cure With Advance L
 102, First Floor Krishna Tower in front of Curewell H
 Janjeer Wala Churaha, INDORE (M.P.)

Time : 10 am to 3pm & 5 pm to 10 pm, Sunday : 12.00 am
 Please Take Appointment Before Consultancy as Possible. Ph
 www.homeopathycure.in Email - arpit@arpit23@gmail.com

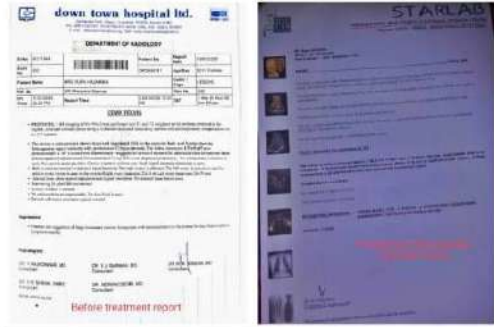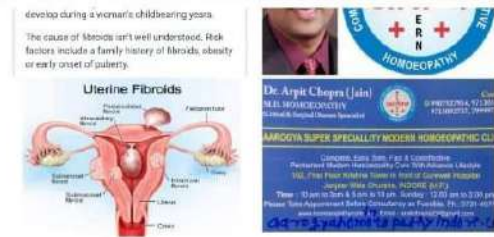99075227
 97130927



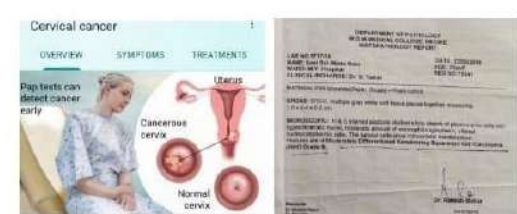
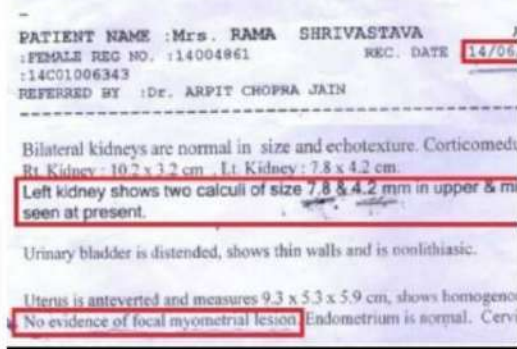
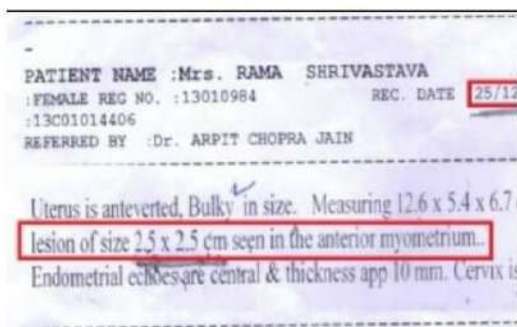
5.2 x 4.8 CM UTERINE FIBROID LARGE SIZED ANOTHER SURGICAL ADVISED CASE CURED & dissolved successf... Read more



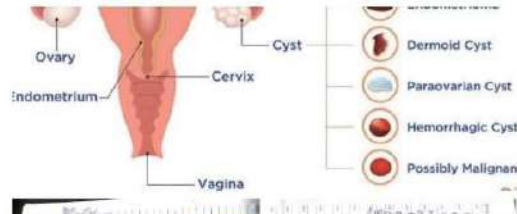
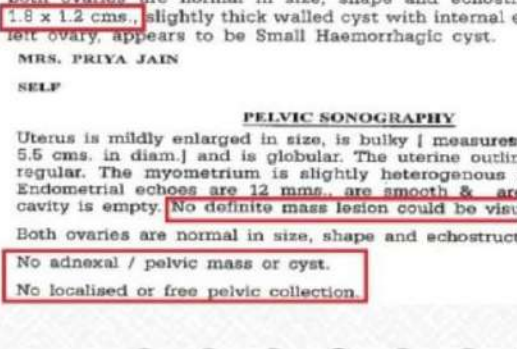
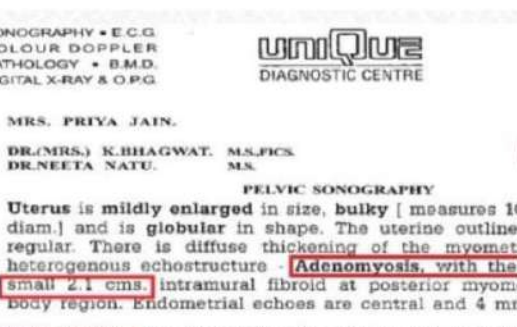
CERVICAL POLYP OF 14 x 8 x 8 MM ANOTHER CASE CURED & RESPONDED successfully by Modern Homo... Read more




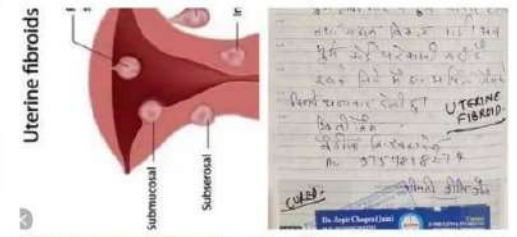
UTERINE FIBROID 117 x 85 MM VERY LARGE SIZED ANOTHER SURGICAL ADVISED CASE RESPONDED ... Read more



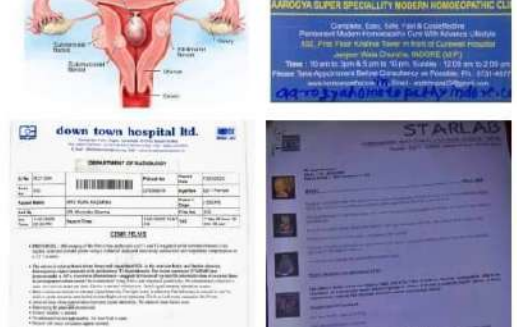UTERINE FIBROID 15 x 6 MM & 12 x 6 MM (INTRAMURAL) WITH BULKY UTTERUS AND PID ANOTHER SURGERY... Read more



OVARIAN CYST OF LARGE SIZE MULTIPLE DIFFERENT SURGERY ADVISED CASES CURED & dissolved su... Read more



UTERINE FIBROID 117 x 85 MM VERY LARGE SIZED ANOTHER SURGICAL ADVISED CASE RESPONDED ... Read more



UTERINE FIBROID 117 x 85 MM VERY LARGE SIZED ANOTHER SURGICAL ADVISED CASE RESPONDED ... Read more

PATIENT NAME :Mrs. MAYA TANK
 : FEMALE REG NO. :16005316
 :16C01006727
 REFERRED BY :Dr. ARPIT CHOPRA JAIN

AGE :40 Y 0 M 0 D SEX
 REC. DATE :05/08/2016 REC NO.

Before Treatment

Follow up case of left breast collection. Previous details not available.

- Left breast low kV high MAS CR (Digital) X-Ray mammography performed.
- Both Medio - lateral 45 - degree oblique and CC views taken. Compression applied.
- Size and shape of left breast is normal.
- Radio-density is mixed type normal for her age.
- Illdefined radio density noted in the inner lower quadrant with no abnormal calcification.
- Skin, Nipple - areola and axilla free. Vasculature is normal.
- Complimentary screening USG reveals a well-defined thick walled irregular collection of size approx 4 x 2.2 cms suggesting benign fluid collection.

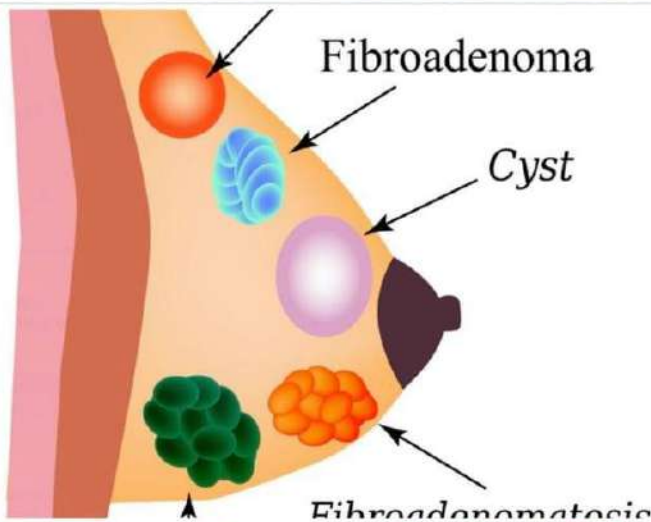
IMPRESSION :- X-Ray Mammographic appearance & complimentary USG screening of left breast in concern falls in BI-RADS Assessment Category 2 (Fluid collection). Most category 2 breast are benign & have 2/10000 chances of cancer. Continue annual screening mammography.

PATIENT NAME :Mrs. MAYA TANK
 : FEMALE REG NO. :16004126
 :16C01009028
 REFERRED BY :Dr. ARPIT CHOPRA JAIN

AGE :40 Y 0 M 0 D SEX
 REC. DATE :18/10/2016 REC NO.

After Treatment

IMPRESSION:- Dense breasts thus mammographic sensitivity is poor, however no evident spiculated mass or suspicious pleomorphic micro calcification seen. Category I (ACR-BIRADS) Negative.



मॉडर्न होम्योपैथी
 Modern Homeopathy - Complete, Permanent, Easy, Safe, Fast & Cost Effective Cure

कसर, कडना फालयर, अस्पताल भ गभार रुप स
 भर्ती मरिजों का उपचार, कोमा, शल्य चिकित्सा योग्य रोग,
 ऑटो इम्यून रोग, जीवनभर दवाई लेने वाले रोगो की रोकथाम एवं
 300 प्रकार के असाध्य जटिल रोगों की चिकित्सा।

अर्पित चौपड़ा (जैन)
 एच. बी. होम्योपैथी
 जटिल, असाध्य एवं
 शल्य रोग विशेषज्ञ

आरोग्य सुपर स्पेशलिटी मॉडर्न होमियोपैथी
 कम्प्लिट, परमानेन्ट, ईजी, सेफ, फास्ट एण्ड कॉस्ट इफैक्टिव

102, प्रथम मंजिल, कृष्णा टॉवर, क्योरवेल हॉस्पिटल के सामने, जंजीरवाला चौराहा, न्यू पलासिया, इन्डिया

Dr.Arpit Chopra (Jain) AAROGYA SUPERSPECIALITY MODERN HOMEOPATHY
 (MD) HOMEOPATHY Complete, Safe, Fast & Cost-Effective Permanent Modern Homeopathy Cure with Advanced Lifestyle
 CRITICAL & SURGICAL DISEASE SPECIALIST Phone : 0731-4977076, Mobile : 97130-92737, 97130-37737, 99999-78894
 Inventor Of Super Speciality Modern Homeopathy
 Gas, Constipation, Piles, Eissure, Fistula, Gastric Ulcer, Worms, Asthma & Respiratory

मॉडर्न होम्योपैथी
 Modern Homeopathy - Complete, Permanent, Easy, Safe, Fast & Cost Effective Cure


Mrs. Maya Tank

Dr. Arpit Chopra (Jain) AAROGYA SUPERSPECIALITY MODERN HOMEOPATHIC CLINIC
 (MD) HOMEOPATHY Complete, Safe, Fast & Cost-Effective Permanent Modern Homeopathy Cure with Advanced Lifestyle
 CRITICAL & SURGICAL DISEASE SPECIALIST Phone : 0731-4977076, Mobile : 97130-92737, 97130-37737, 99999-78894, 99075-27914
 Inventor Of Super Speciality Modern Homeopathy

मॉडर्न होम्योपैथी
 Modern Homeopathy - Complete, Permanent, Easy, Safe, Fast & Cost Effective Cure

Dr. Arpit Chopra (Jain) AAROGYA SUPERSPECIALITY MODERN HOMEOPATHIC CLINIC
 (MD) HOMEOPATHY Complete, Safe, Fast & Cost-Effective Permanent Modern Homeopathy Cure with Advanced Lifestyle
 CRITICAL & SURGICAL DISEASE SPECIALIST Phone : 0731-4977076, Mobile : 97130-92737, 97130-37737, 99999-78894, 99075-27914
 Inventor Of Super Speciality Modern Homeopathy

Cancer (Any Type) / Stage, Anorexia, Leucorrhoea, PCOD, Menstrual disorders, Chronic Disorders, Excessive Sweating



before treatment



after Modern Homoeopathy treatment cured

Many Women have
PCOS & ACNE:
 My Top Treatments



पता : 102, प्रथम मंजिल कृष्णा टॉवर, कन्यावेल हॉस्पिटल के सामने, कर्नावला चौराहा, न्यू परासिया, इन्डिया
 सोम से शनि-सुबह : 10 से 3 बजे तक एवं शाम 5 से 10 बजे तक, रविवार : सुबह 12 से 3 बजे तक

डॉ. अर्पिता चौपड़ा (जेन)
 M.D. HOMOEOPATHY (GENERAL & SURGICAL DISEASES SPECIALIST)
 0731-4977076, 7999978894, 9907527914
 arpitchopra23@gmail.com
 www.homoeopathy.cure.in/com

"PCOD/PCOS WITH ACNE (PIMPLES)"
 Monday 30th MARCH 2020
 ३० मार्च २०२०

My name is Vidhya Menon from Durgam
 I was suffering from PCOD due to which I was having face pimples and black spots. After taking 2 months of treatment from Dr. Arpita Chopra I have been totally recovered with my face pimples as well as my skin disease PCOD. I have visited many doctors but there was no cure but now I am totally recovered with my problem.

Firstly I thought homeopathy medicine did not cure and I have much but it did a miracle and made me believe. Thanks to Dr. Arpita Chopra and Modern Homeopathy for dealing with such a great issue.

VED
 Vidhya Menon
 Durgam (M.P.)
 Phone No - 9179334664.

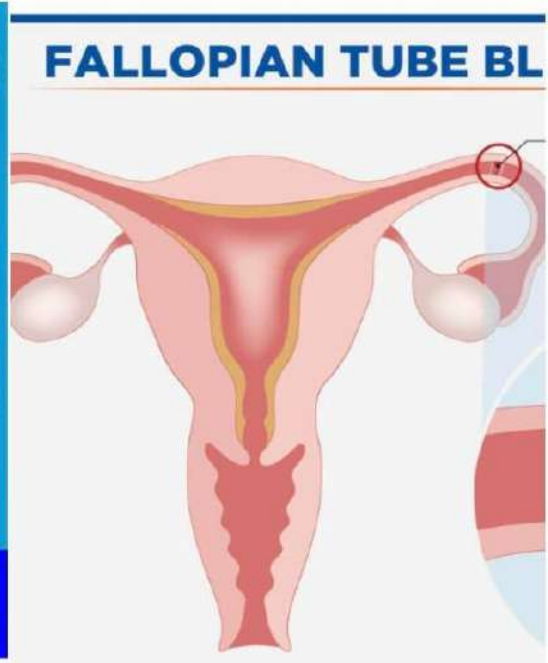

घोषैथी
Safe, Fast & Cost Effective Cure

आरोग्य

Babita Karma

MODERN HOMEOPATHIC CLINIC
Permanent Modern Homeopathy Cure with Advanced Lifestyle
92737, 97130-37737, 79999-78894, 99075-27914



CHL-Hospitals
- Inspiring Health -

OB - 2/3 Trimester Scan Report

Indication(s)
ANOMALY SCAN LEVEL 1
Real time B mode ultrasonography of gravid uterus done

Estimated fetal weight according to BPO AC - 311 ± 31.1 FL AC - 334 ± 1 - 33.4 gms.

Convenient Hospitals Ltd.

CHL-Hospitals
- Inspiring Health -

LOW LYNOX PLACENTA

Estimated fetal weight according to BPO AC - 311 ± 31.1 FL AC - 334 ± 1 - 33.4 gms.

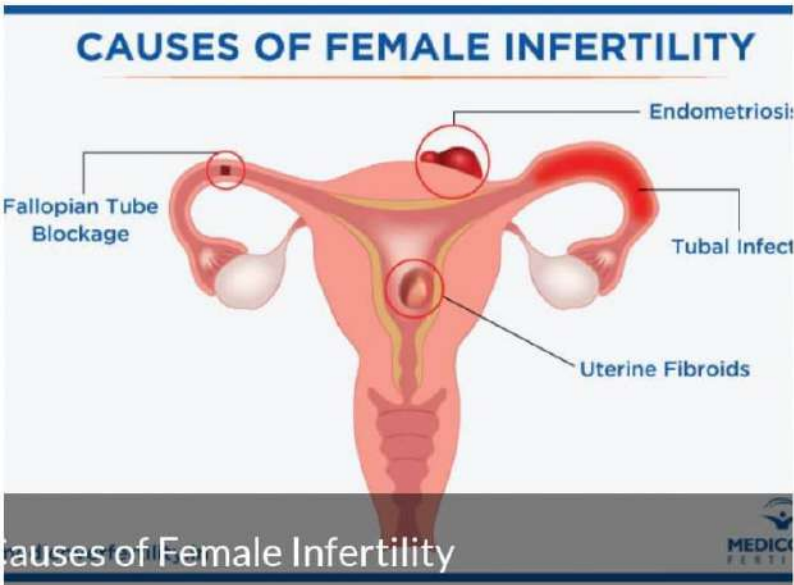
Convenient Hospitals Ltd.

operation र दुग्धने के बाद मे
1 से 2 years के समय चलो काफ़ी
Doctors को सवाल की शोर इलाक
मे चलो फिर भी कोई लम्बे
नली दुग्ध फिर हमारी मरीजी
ने अति बलवा को आप
से मिलिए तो किन्तु लम
सर से मिले और सम्म
सर ने हमको समझाया कि
तो हमले सर से इलाक लिया
लाह दुग्ध मरिने हवाई ली आके
वहाँ मेरी पत्नी को निह

month को रत ए और
इसलिए मे सर को नली व
बहुत - बहुत धन्यवाद देना
चाहता हूँ

कमलेशी का, सतवास से

Mobile No. - 9575172962



COMPLETE CURE, EASY, SAFE, FAST & COST EFFECTIVE

MODERN

आरोग्य

ERN

HOMOEOPATHY

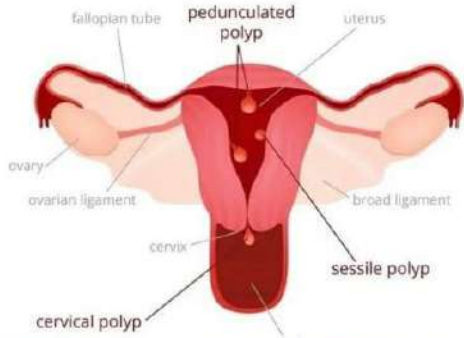
Causes of Female Infertility

Causes of Female Infertility

Dr. Arpit Chopra (Jain)
M.D. HOMOEOPATHY
(Critical & Surgical Diseases Specialist)

9907527914, 9713037
9713092737, 7999978

UTERINE POLYPS (endometrial Polyps)



Endometrial polyp

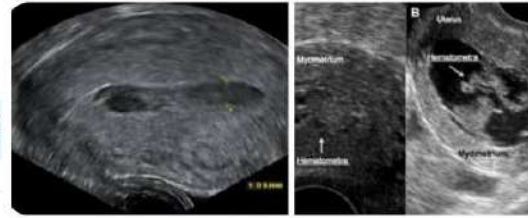
Overview

Symptoms

Treat

A usually non-cancerous growth attached to the inner wall of the womb (uterus).

Endometrial polyps are common in women undergoing or have completed menopause and their size varies.



Hematometra is a medical condition involving collection or retention of blood in the uterus. It is most commonly caused by an imperforate hymen or a transverse vaginal septum.

ukund IMAGING AND DIAGNOSTICS
 Patient Name - Jamila Bee Qureshi 75 Y/F
 Ref By - Dr. Mahendra Chouhan MD
 Date - 22-08-2020
MRI - ABDOMEN & PELVIS

Technique:-
 Ultrafast multiplanar mult. Echo sequences were obtained through the abdomen and pelvis.

Imaging Findings and remarks:-
 Haemorrhagic fluid filled cavity is noted in the endometrial cavity showing hyperintense signal on T1 and T2 sequences. This cavity measuring 5.1 x 4.2 x 4.0 cm (approximately 40 mL volume). Left lateral aspect of this fluid filled cavity shows an irregular soft tissue lesion measuring 2.5 x 2.2 cm. This lesion appears endometrial polyp. Nature: The fluid collection in the endometrial cavity appears encysted with the apparent stenosis in the cervical endometrial canal possibly caused by chronic cervicitis. No obvious mass lesion is noted in the region of uterine cervix. The uterine myometrium appears thinned out due to distension of the endometrial cavity.

The vagina appears normal. Both ovaries are normal for age. Bilateral parametrial structures appear unremarkable.

The liver is normal in size and intensity - no focal lesion is seen.

The gall-bladder, biliary tree and pancreas are normal.

The portal vein, splenic vein and spleen are normal.

Both adrenals are normal. Both kidneys, ureters and urinary bladder are normal.

No ascites is seen. No adenopathy is seen. The bowel loops are unremarkable.

Dr. Manish Lodha MD
 Consultant Radiologist
 8, Freearg Road, Near Do Batti, RATLAM(M.P.) Ph: 07412-224444, 408408
 M: 96300 80408 (24x7) Email: sky@healthcare@gmail.com

ukund IMAGING AND DIAGNOSTICS
 Patient Name - Jamila Bee Qureshi 75 Y/F
 Ref. By - Dr. Dinesh Jadav / DR. ARJIT CHOPRA JAIN (MD Hemato)
 Date - 25-02-2021
USG ABDOMEN AND PELVIS

Uter shows normal size, shape and morphology with normal echogenecity. Portal vein and strabehaptic portal venous radicals are normal. CBD and IHSR appear normal.

Sall bladder shows normal size and morphology with echo free Lumen. No wall edema or calculus noted. Pancreas appears normal in morphology and size.

Spleen appears normal in morphology, echogenecity and size. It measures 7.3 cm.

Right Kidney measures 8.4 x 4.0 cm. Left kidney measures 9.2 x 4.1 cm.

Both kidneys are normal in size, shape, position and cortical echogenecity with normal cortico-medullary differentiation.

Excess bowel gases are seen. Bowel loops are showing normal peristalsis. No evidence of any bowel wall thickening noted. No significant lymphadenopathy or ascites.

Few small internal echoes are seen in urinary bladder. Urinary bladder is (partially) distended with normal wall thickness. No significant post void residue noted.

Uterus and ovaries are normal for age.

IMPRESSION:-
 Few small internal echoes are seen in urinary bladder -> Mild UTI/Sediments.
 Excess bowel gases are seen.
 No other significant abnormality is seen in USG Whole Abdomen.

Dr. Manish Lodha MD
 Consultant Sonologist
 8, Freearg Road, Near Do Batti, RATLAM(M.P.) Ph: 07412-224444, 408408
 M: 96300 80408 (24x7) Email: sky@healthcare@gmail.com

Endometrium Uterine polyp with Hydrometra
 Wednesday FEB 21 24
 2021

मेरी दादी को 50x5x4x2x4cm का एक 2.5x2.2cm का जोड़ी कैंसर के बाद से 2-3 महीने से ब्लीडिंग हो रही है जो कि बहुत खतरनाक है।
 डॉक्टरों से कई बार चिकित्सा कराई है लेकिन कोई फायदा नहीं हुआ।
 मैंने डॉ. अरजित चोपड़ा जी से सलाह ली है।
 मैंने डॉ. अरजित चोपड़ा जी से सलाह ली है।
 मैंने डॉ. अरजित चोपड़ा जी से सलाह ली है।

Dr. Arpit Chopra (Jain)
 MD, HOMOEOPATH
 Mob: 97130 37737

CONSULTANT HOMOEOPATH & BIOCHEMIC
AAROGYA SUPER SPECIALITY MODERN HOMOEOPATHIC CLINIC (COMPUTERISED)
 Complete, Easy, Safe, Fast & Cost-Effective
 Permanent Modern Homoeopathy Centre with Laboratory
 102, First Floor Krishna Tower in front of Cuneent Hospital
 Jangpore Wada Chauraha, INDORE (M.P.)
 Time: 5.00pm to 9.30pm Sunday: 11.00am to 2.00pm
 Please Take Appointment Before Consultancy
 www.homoeopathyinindore.com, Email: arpitchopra23@gmail.com



आरोग्य सुपर स्पेशलिटी मॉडर्न होम्योपैथिक क्लीनिक

कम्प्लिट * परमानेंट * ईजी * सेफ * फास्ट एंड कॉस्ट इफैक्टिव

* कैंसर * किडनी फेलियर * अस्पताल में गंभीर रूप से भर्ती मरिजों का उपचार * कोमा *
 * शल्य चिकित्सा योग्य रोग * आँटो इन्फ्यूजन रोग * जीवनभर दवाई लेने वाले रोगों की रोकथाम
 एवं 300 प्रकार के असाध्य जटिल रोगों की चिकित्सा।

102, 104, प्रथम मंजिल, कृष्णा टॉवर, ब्योरवेल हॉस्पिटल के सामने, जंजीरवाला चौराहा, न्यू पलासिया, इन्दौर (म.प्र.)
 फोन : 0731-4977076, मो. : 97130-92737, 97130-37737, 79999-78894, 99075-27914
 www.homoeopathyinindore.com, www.aarogyahomoeopathyindore.com Email : arpitchopra23@gmail.com

कैंसर, किडनी फेलियर, अस्पताल में गंभीर रूप से
 भर्ती मरिजों का उपचार, कोमा, शल्य चिकित्सा योग्य रोग,
 ऑटो इम्यून रोग, जीवनभर दवाई लेने वाले रोगों की रोकथाम एवं
 300 प्रकार के असाध्य जटिल रोगों की चिकित्सा।



डॉ. अर्पित चौपड़ा (जैम)
 एच. बी. होम्योपैथी
 जटिल, असाध्य एवं
 शल्य रोग विशेषज्ञ

आरोग्य सुपर स्पेशलिटी माईन होमियोपैथी

कम्पलिट, परमानेन्ट, ईजी, सेफ, फास्ट एण्ड कॉस्ट इफैक्टिव

102, प्रथम मंजिल, कृष्णा टॉवर, क्योरवेल् हॉस्पिटल के सामने, जंजीरवाला चौराहा, न्यू पलासिया, इन्दौर म.प्र.

📞 99075 27914 संपर्क : 0731-4977076, 79999 78894

www.homoeopathyucure.in, www.aarogyahomoeopathyindore.com Email : arpitchopra23@gmail.com

Dr. Vinod Choudhari
 M.D. (Homoeopathy) M.F.O.
 443/101, Malkapur
 Ph: 07267122396, 226504

Dr. Archana V. Choudhari
 M.D. (Homoeopathy)
 443/101, Malkapur
 Ph: 07267122396, 226504

Aishwarya Hospital
 Digital X-Ray & Sonography Clinic
 & Eye Hospital

Plot No. 67, 40 Digha, Near Kalla Hospital, MALKAPUR - 443 101. Ph: 07267122396, 226504

Name : MRS. SWATI MAHAJAN Age/Sex : 40 YEARS/F
 Ref By : DR. SELF Date : 09 Mar 2021

PELVIC USG STUDY.

URINARY BLADDER:- Normal. No e/o calculus.

Uterus :- Ante-verted, BULKY, Measures 113 x 76 x 56 mm.

E/O ROUD HYPOECHOIC LESION OF 31 MM IN ANTERIOR WALL IN FUNDUS.
 ROUND HYPOECHOIC LESION OF 50 MM DIAMETER IN POSTERIOR WALL.

A SMALL HYPOECHOIC LESION OF 19 MM IN ANTERIOR WALL IN SUBSEROSAL REGION.

Endometrial cavity is empty.

Cervix is normal.

Both ovaries are normal.

No solid or cystic adnexal mass.

No fluid in POD.

IMPRESSION :- BULKY UTERUS WITH MULTIPLE FIBROIDES IN UTERUS.

Please correlate clinically.

Dr. Vinod Choudhari
 M.D. (Homoeopathy) M.F.O.
 443/101, Malkapur
 Ph: 07267122396, 226504

Dr. Archana V. Choudhari
 M.D. (Homoeopathy)
 443/101, Malkapur
 Ph: 07267122396, 226504

Hospital
 Digital X-Ray & Sonography Clinic
 & Eye Hospital

Plot No. 67, 40 Digha, Near Kalla Hospital, MALKAPUR - 443 101. Ph: 07267122396, 226504

Name : MRS. SWATI ROSHAN MAHAJAN Age/Sex : 40 YEARS/F
 Ref By : DR. SELF Date : 27 Apr 2021

ABDOMINAL USG STUDY

LIVER:- Normal size, Normal echo pattern. No focal lesion. No e/o dilated biliary radicals. Hepatic veins are normal.

Gall Bladder:- Well distended, No e/o calculus, Normal wall thickness.

PANCREAS:- Normal in size and echo pattern.

SPLEEN:- Normal in size, Normal echo pattern. No focal lesion.

Rt. Kidney:- 100 x 38 mm, Lt. Kidney:- 109 x 50 mm.

Both kidneys are Normal in size shape and echo pattern.

Normal corticomedullary junctions.

NO E/O CALCULUS. NO HYDRONEPHROSIS.

Ureters could not be traced.

URINARY BLADDER:- Partially distended. No e/o calculus. No e/o cystitis.

Uterus :- Ante-verted, BULKY, MULTIPLE INTRAMURAL FIBROIDES OF 20 MM, 15 MM AND 14 MM IN UTERUS. Cervix is normal.

Both ovaries are normal. no solid or cystic pelvic mass.

AORTA & IVC are normal. No adenopathy.

No e/o any bowel mass or free fluid in abdomen and pelvis.

No pleural or pericardial effusion.

IMPRESSION:- S/O MULTIPLE INTRAMURAL FIBROIDES IN UTERUS.

Please correlate clinically.

THANKS WITH REGARDS

Fibroids

Also called: Uterine myoma

Overview

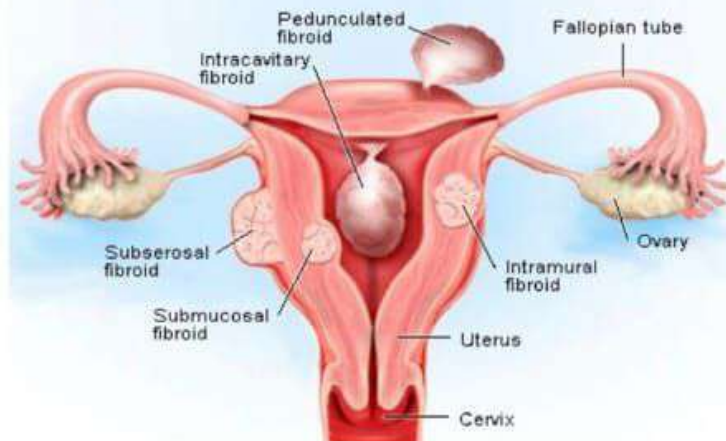
Symptoms

Treatments

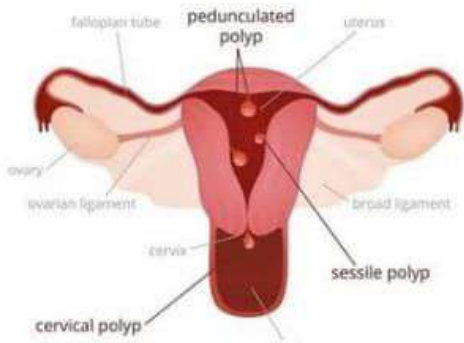
Non-cancerous growths in the uterus that can develop during a woman's childbearing years.

The cause of fibroids isn't well understood. Risk factors include a family history of fibroids, obesity or early onset of puberty.

Uterine Fibroids



UTERINE POLYPS (endometrial Polyps)



Endometrial polyp

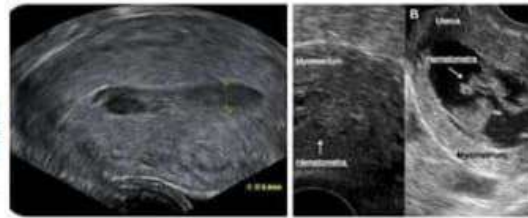
Overview

Symptoms

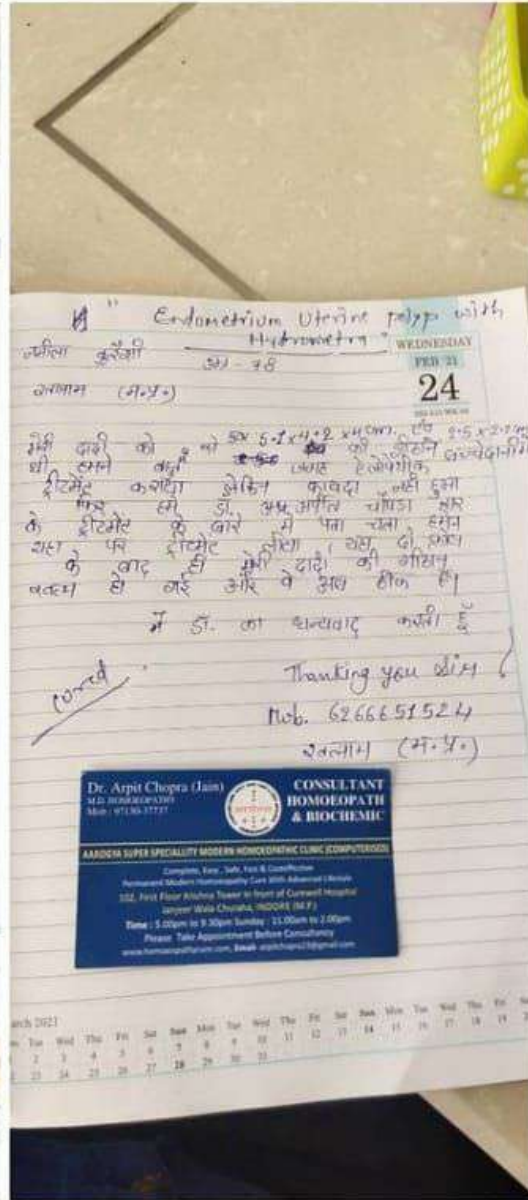
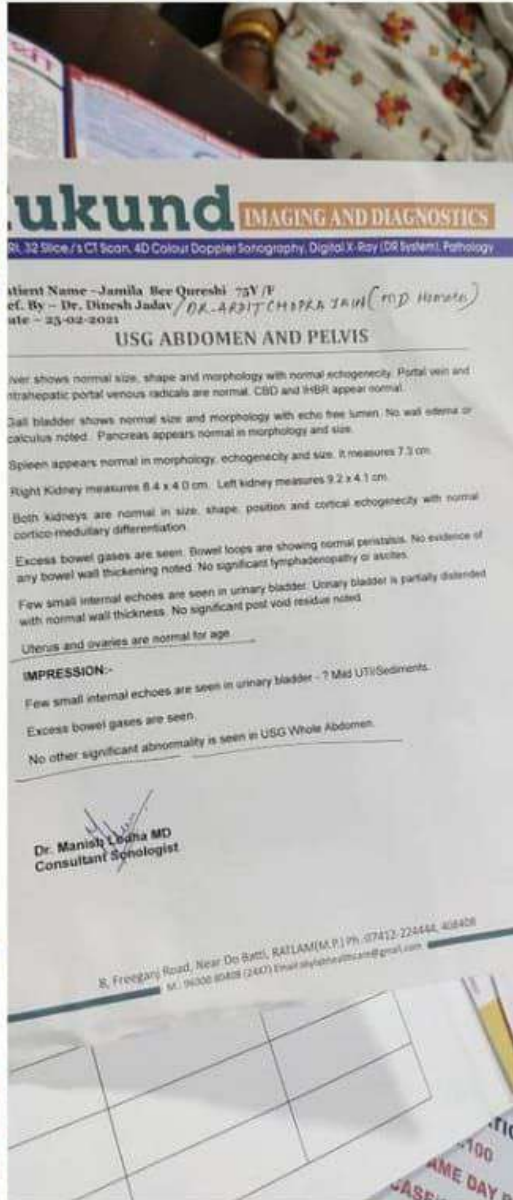
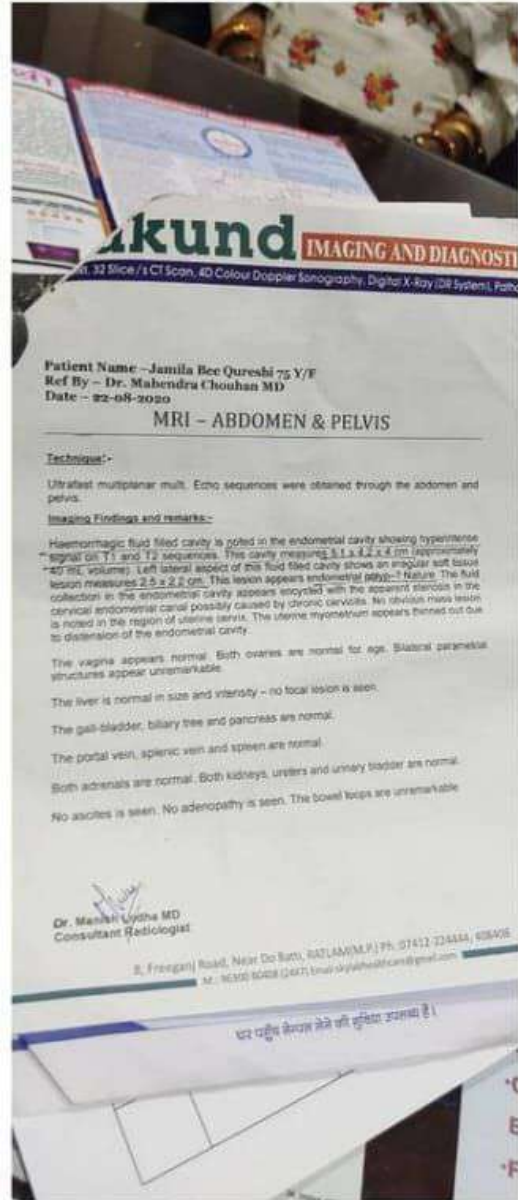
Treat

A usually non-cancerous growth attached to the inner wall of the womb (uterus).

Endometrial polyps are common in women undergoing or have completed menopause and their size varies.



Hematometra is a medical condition involving collection or retention of blood in the uterus. It is most commonly caused by an imperforate hymen or a transverse vaginal septum.



आरोग्य सुपर स्पेशलिटी मॉडर्न होम्योपैथिक क्लिनिक

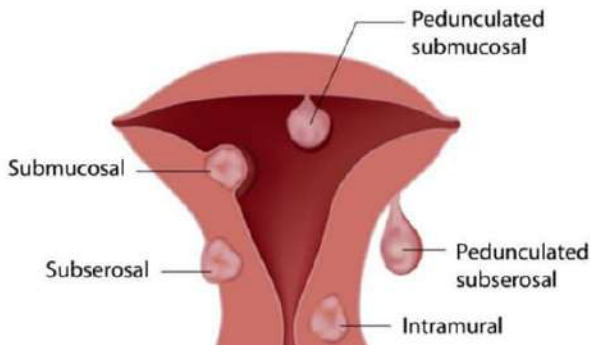कम्पलिट * परमानेंट * ईजी * सेफ * फास्ट एण्ड कॉस्ट इफैक्टिव

* कैंसर * किडनी फेलियर * अस्पताल में गंभीर रूप से भर्ती मरिजों का उपचार * कोमा *

* शल्य चिकित्सा योग्य रोग * आँटो इन्फ्यूज रोग * जीवनभर दवाई लेने वाले रोगों की रोकथाम

एवं 300 प्रकार के असाध्य जटिल रोगों की चिकित्सा ।

Uterine fibroids



कैंसर, किडनी फेलियर, अस्पताल में गंभीर रूप से भर्ती मरिजों का उपचार, कोमा, शल्य चिकित्सा योग्य रोग, ऑटो इम्यून रोग, जीवनभर दवाई लेने वाले रोगों की रोकथाम एवं 300 प्रकार के असाध्य जटिल रोगों की चिकित्सा।

आरोग्य सुपर स्पेशलिटी मॉडर्न होमियोपैथी

कम्पलिट, परमानेंट, ईजी, सेफ, फास्ट एण्ड कॉस्ट इफैक्टिव

102, प्रथम मंजिल, कृष्णा टॉवर, क्योरवेल हॉस्पिटल के सामने, जंजीरवाला चौराहा, न्यू पलासिया, इन्दौर म.प्र.

99075 27914 संपर्क : 0731-4977076, 79999 78894

www.homeopathycure.in www.aarogyaahomeopathyindore.com Email: amitichopra23@gmail.com

डॉ. अमित चौपड़ा (जैन)
एच. बी. होमियोपैथी
जटिल, असाध्य एवं
हृत्स्य रोग विशेषज्ञ

आरोग्य सुपर स्पेशलिटी मॉडर्न होमियोपैथी

कम्पलिट, परमानेंट, ईजी, सेफ, फास्ट एण्ड कॉस्ट इफैक्टिव

102, प्रथम मंजिल, कृष्णा टॉवर, क्योरवेल हॉस्पिटल के सामने, जंजीरवाला चौराहा, न्यू पलासिया, इन्दौर म.प्र.

99075 27914 संपर्क : 0731-4977076, 79999 78894

www.homeopathycure.in www.aarogyaahomeopathyindore.com Email: amitichopra23@gmail.com

CHRISTIAN PATTY, NEAR CHURCH, A.D.P. ROAD, NOGAON
Phones : 03672 - 235842 , 236247 (Clinic)

Ms. Rupa Hazarika
Ref by :: Dr. M Hazarika MD
Part scanned :: USG of whole abdomen

REPORT
January 28, 2021

The liver is mildly enlarged. High level echoes are seen in liver. The intra hepatic biliary ducts are normal. The portal and hepatic veins are normal. No SOL is seen in liver.

The Gall-Bladder is well distended. The wall thickness of Gall-Bladder is normal. No calculi are seen in Gall-Bladder.

The extra hepatic biliary ducts are normal. The CBD measures 4.3 mm. No calculi are seen in CBD.

High level echoes are seen in pancreas. The MPD is not dilated.

The echotextures of spleen are normal.

The size of right and left kidneys are 109.5 mm and 107.5 mm respectively. The pelvi-calyceal systems of both kidneys are normal. No calculi are seen in kidneys.

No ascites nor paraaortic lymphadenopathy seen.

PELVIC ORGANS

The uterus is grossly enlarged and measures approx 150.7 mm X 108.6 mm X 81.9 mm. The echotexture of myometrium is heterogenous. A large elongated hypoechoic lesion measuring approx 104mm X 58 mm is seen centrally inside uterus.

None of the normal ovaries are visualized.

No free fluid is seen in POD.

The urinary bladder is normal.

PROVISIONAL IMPRESSION :: 1. FATTY INFILTRATION OF LIVER AND PANCREAS.
2. LARGE UTERUS WITH UTERINE POLYP / MASS.

ADV :: Follow up.

2021-1-28

STARLAB
CHRISTIAN PATTY, NEAR CHURCH, A.D.P. ROAD, NOGAON - 782 001
Phones : 03672 - 235842 , 236247 (Clinic) 231721 (Home)

Ms. Rupa Hazarika 54yr, F
Ref by :: Dr. Self
Part scanned :: USG of whole abdomen

REPORT
July 15, 2021

The liver is mildly enlarged. High level echoes are seen in liver. The intrahepatic biliary ducts are normal. The portal and hepatic veins are normal. No SOL is seen in liver.

The Gall-Bladder is well distended. The wall thickness of Gall-Bladder is normal. No calculi are seen in Gall-Bladder.

The extra hepatic biliary ducts are normal. The CBD measures 4.0 mm. No calculi detected in CBD.

The echoanatomy of pancreas is normal.

The echotextures of spleen are normal.

The size of right and left kidneys are 82.7 mm and 92.1 mm respectively. The pelvi - calyceal systems of both kidneys are normal. No calculi are seen in kidneys.

No ascites nor paraaortic lymphadenopathy seen.

PELVIC ORGANS

The uterus is bulky and measures approx 187.7 mm X 112 mm X 73 mm. An oval hypo echoic lesion measuring approx 86mm X 51mm is seen centrally in uterus. A placenta like structure is seen around the hypo echoic lesion.

The ovaries are not visualized.

No free fluid is seen in POD.

The urinary bladder is normal.

PROVISIONAL IMPRESSION :: 1. FATTY LIVER
2. BULKY UTERUS WITH HYPO ECHOIC LESION AS MENTIONED ABOVE.

ADVISED :: 1. CA125
2. TVS
3. FOLLOW UP

2021-7-15 13:35

Before treatment

after Modern Homoeopathy treatment as on July 2021

मॉडर्न होम्योपैथी

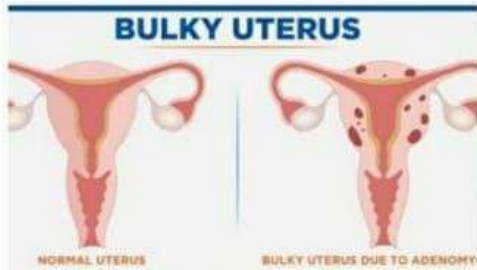
Modern Homeopathy - Complete, Permanent, Easy, Safe, Fast & Cost Effective Cure



Mrs. Roshni Satle
Sanvad (M.P.)



Dr. Arpit Chopra (Jain)
(MD) HOMEOPATHY
CRITICAL & SURGICAL DISEASE SPECIALIST

AAROGYA SUPERSPECIALITY MODERN HOMEOPATHIC CLINIC
Complete, Safe, Fast & Cost-Effective Permanent Modern Homeopathy Cure with Advanced Lifestyle




डिप्पर, चिकित्सी केरियर, अस्पताल में सचिव रूप में
बर्ती परिवार का उपचार, कोमा, शल्य चिकित्सा योग्य रोग,
अर्धो बुद्धि रोग, जीवनपर्यन्त स्वार्थ लेने वाले लोगों को रोकावट एवं
300 प्रकार के अलायन जटिल रोगों की चिकित्सा।

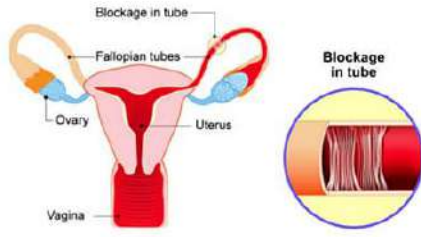
आरोग्य सुपर स्पेशलिटी मॉडर्न होमियोपैथी
बम्बई, पारानेपर, ई-सी, केए, काउन्सल एंड ऑप्टिकल इन्फॉर्मेशन
102, कृष्ण चौराहा, कृष्ण टॉवर, लोकोक (एडमिशन के समकालीन), लोकोक रोड, न्यू कालोनी, कृष्ण नगर,
www.homenopathy.com | www.aarogyasuperspecialitymodernhomeopathy.com | Email: aarogyasuperspeciality@gmail.com



Adenomyosis >
A condition in which endometrial tissue exists within and grows into the **uterine wall**.
Symptoms may include

- Painful intercourse
- Menstrual cramps
- Abdominal pain





* कैंसर * किडनी फेलियर * अस्पताल में गंभीर रूप से * भर्ती मरि
 * शल्य चिकित्सा योग्य रोग आँटो इन्सूत रोग * जीवनभर दवाई लेने
 एवं 300 प्रकार के असाध्य जटिल रोगों की चिकि
आरोग्य सुपर स्पेशलिटी मॉडर्न होम्योपै
 डॉ. जयदीप (मैन)
 एच.टी. इन्सोलेबी
 जटिल, असाध्य एवं
 शल्य रोग विशेषज्ञ
 कम्प्यूटिड * परमानेन्ट * ईजी * लेफ * फास्ट एण्ड
 102, प्रथम मंजिल, कृष्णा टॉवर, कवोरवेल हॉस्पिटल के सामने, जंजीरवाला चौक
 फ़ोन : 0731-4977076, मो. : 97130-92737, 97130-37737, 79899
 www.homoepathycure.in, www.aarogyahomeopathyindore.com Email : an

DATE - 11.12.2020

PATIENT NAME..... MRS. KHILSHWARI SAHU
 AGE/SEX 29 YRS / FEMALE
 REF. BY DR. PRITI AGRAWAL MD(OBG)

Technique: HSG done using 50% dilution of Urografin 76% under image intensifier.

OBSERVATION

- No evidence of any filling defect or extrinsic impression on the endometrial cavity.
- No evidence of any stricture or dilatation.
- There is no free spill of contrast into peritoneal cavity suggestive of Bilateral Fallopian Tubes blockage.
- IMPRESSION: Bilateral Fallopian Tubes blockage.

DR. RAJESH RUPRELA
 MBBS, DARRD
 CONSULTANT RADIOLOGIST

Investigations have their limitations and/or radiological, pathological and other investigations may confirm the final diagnosis of disease. They may help in diagnosing the disease in correlation to symptoms and other related tests please interpret accordingly.

Kindly Note:-

- The report and films are not valid for medico-legal purpose.
- Please follow-up as if any typing mistakes and send the report for correction within 7 days.

before treatment

Dpp. Gold's Gym, Shankar Nagar, Raipur (C.G.), Tel: 0771-4044115, 4265115, Fax: 0771-4281223
 Email : aarogya_raipur@yahoo.com

Scanned by CamScanner

Ruprela
 X-ray & Advanced Diagnostic Centre
 (ANISO Certified Lab - certificate No. LR 1331 031) E-Mail: ruprela@rediffmail.com

OFF: TA BHILOffice, Behind RAJANGMANSI
 G. ROAD KATCHERI CHOWK RAIPUR
 TEL: 0771-331437
 M: 977089992

Reg No : 117544 Date: 20/09/2021
 Name : KHILSHWARI SAHU Sex/Age: F/29 Y
 Referred By : DR. P. AGRAWAL

HYSTRO-SALPINGO-GRAM

UTERUS : NORMAL SIZE, SHAPE AND CONTOUR. NO FILLING DEFECT OR ANOMALY SEEN.

FALLOPIAN TUBES : BOTH ARE OF NORMAL CALIBRE. PERITONEAL SPILL SEEN ON BOTH SIDES.

INFERENCE : BOTH FALLOPIAN TUBES ARE PATENT.
 : NORMAL UTERINE CAVITY.

NOTE:- Procedure was painless as disposable HSG plastic catheter used.
 :- Procedure was done under image intensifier, which increases the accuracy.

Dr. Rajesh Ruprela
 MBBS, DMRE, FICA (USA), MRSI (London)

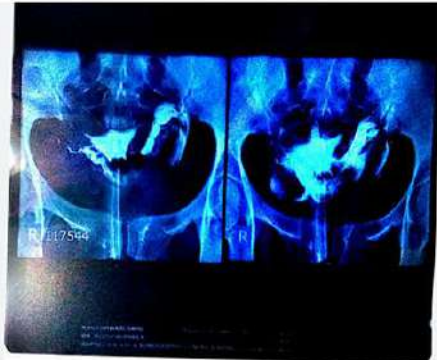
Dr. Harshad Ruprela
 MBBS, DMRD, DNB (Stomach)

after modern homoeopathy treatment

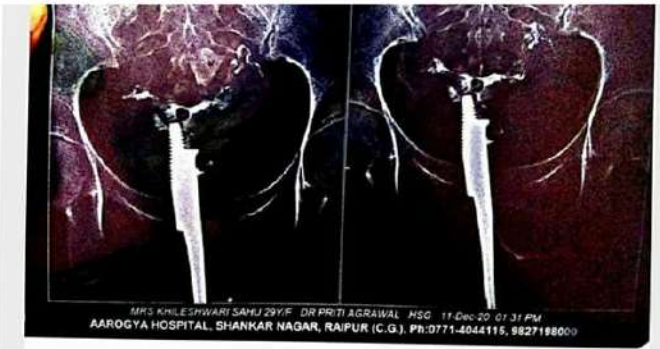
RADIOLOGY
 DR. RAJESH RUPRELA
 MBBS, DMRE, FICA (USA), MRSI (LONDON)
 Radiologist

RADIOLOGY
 DR. HARSHAD RUPRELA
 MBBS, DMRD, DNB (STOMACH)
 Radiologist

Scanned by CamScanner



before treatment



after modern homoeopathy treatment

मॉडर्न होम्योपैथी

Modern Homeopathy - Complete, Permanent, Easy, Safe, Fast & Cost Effective Cure

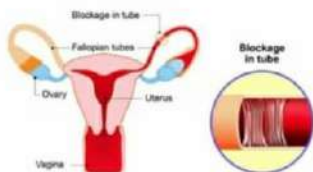


Dr. Arpit Chopra (Jain)
(MD) HOMEOPATHY
CRITICAL & SURGICAL DISEASES SPECIALIST
Investor Of Super Speciality Modern Homeopathy



Khileshwari Sahu
Ruzm Garaband, Chhattisgarh

AAROGYA SUPERSPECIALITY MODERN HOMEOPATHY CLINIC
Complete, Safe, Fast & Cost-Effective Modern Homeopathy Cured With Advanced Lifestyle
Phone : 0731-4977076, Mobile : 97130-92737, 97130-37737, 79999-78894, For Whatsaap, 99075-27914



• कैंसर • किडनी फेलियर • अस्पताल में गंभीर रूप से • भर्ती मरीज
• शल्य चिकित्सा योग्य रोग • आंटी ड्रग्स रोग • जीवनभर दवाई लेने
एवं 300 प्रकार के असाध्य जटिल रोगों की चिकित्सा

आरोग्य सुपर स्पेशलिटी मॉडर्न होम्योपैथी

डॉ. अर्पित चोपड़ा (जैन)
एच.डी. (होम्योपैथी)
क्रिटिकल & सर्जिकल रोगों के विशेषज्ञ
सुपरस्पेशलिटी में अग्रणी

कामगारों के • परामर्श के • इंजीनी • रोगों • पर फलदा एकाद
102, शंकर भवन, शंकर नगर, रापुर (C.G.) के समीप, अर्पित चोपड़ा जीन
फोन : 0731-4977076, मो. : 97130-92737, 97130-37737, 79999-78894
www.homeopathyindia.in, www.aarogyahomeopathyindia.com Email : aa

DATE - 11.12.2023

PATIENT NAME: MRS. KHILESHWARI SAHU
AGE/SEX: 29 YRS / FEMALE
REF. BY: DR. PRITI AGRAWAL (MBOBG)

Observation: HSG done using 30% dilution of Contrast. No leak seen at uterine cavity.

OBSERVATION

- No evidence of any filling defect or extrinsic impression on the endometrial cavity.
- No evidence of any tubular dilatation.
- There is no free spill of contrast into peritoneal cavity suggestive of Bilateral Fallopian Tube Blockage.

IMPRESSION: Bilateral Fallopian Tube Blockage.

DR. RAJESH BHARGAVA
M.B.B.S., D.M.D.
CONTRAST RADIOLOGIST

before treatment

Opp. Kirti's Gym, Shankar Nagar, Raipur (C.G.), Tel. : 0771-494118, 422115, Fax : 0771-4291223
E-mail : aarogyahomeopathy@yahoo.com

Scanned by CamScanner

Ruprela
X-ray & Advanced Diagnostic Centre

MRD 5A, JALAJITHI, BHIMJI KUMAR BHAVI
C. E. 2010-44010001000000000000
TEL: 0731 494118
M: 97130 92737

HYSTRO-SALPINGO-GRAM

UTERUS: NORMAL SIZE, SHAPE AND CONTOUR, NO FILLING DEFECT OR ABNORMALITY NOTED.

FALLOPIAN TUBES: BOTH SIDES OF NORMAL CALIBRE, PERITONEAL SPILL NOTED ON BOTH SIDES.

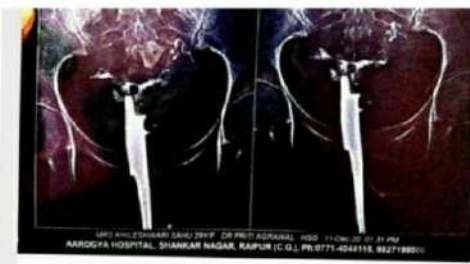
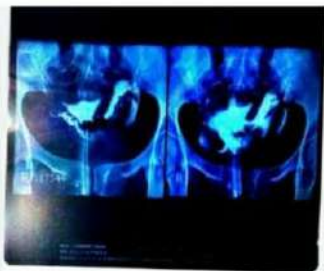IMPRESSION: BOTH FALLOPIAN TUBES ARE PATENT.
NORMAL UTERINE CAVITY.

NOTE: Procedure was painless as diagnosed with HSG photo reflector used.
Procedure was done under aseptic technique, which becomes the accuracy.

Dr. Rajesh Bhargava
MRD 5A, JALAJITHI, BHIMJI KUMAR BHAVI
Dr. Harish Bhargava
MRD 5A, JALAJITHI, BHIMJI KUMAR BHAVI

after modern homoeopathy treatment

Scanned by CamScanner



Fibroids

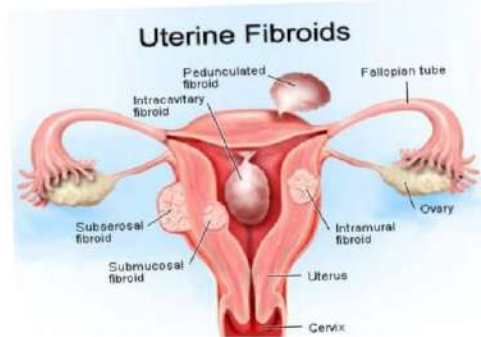
Also called: Uterine myoma

Overview

Symptoms

Treatments

Non-cancerous growths in the uterus that can develop during a woman's childbearing years.



आरोग्य सुपर स्पेशलिटी मॉडर्न होम्योपैथिक क्लीनिक

कम्पलिट * परमानेंट * ईजी * सेफ * फास्ट एण्ड कॉस्ट इफैक्टिव

* कैंसर * किडनी फेलियर * अस्पताल में गंभीर रूप से * भर्ती मरिजों का उपचार * कोमा * शल्य चिकित्सा योग्य रोग * आँटो इन्यून रोग * जीवनभर दवाई लेने वाले रोगों की रोकथाम एवं 300 प्रकार के असाध्य जटिल रोगों की चिकित्सा ।

102, 104, प्रथम मंजिल, कृष्णा टॉवर, क्योरवेल हॉस्पिटल के सामने, जंजीरवाला चौराहा, न्यू पलासिया, इन्दौर (म.प्र.)

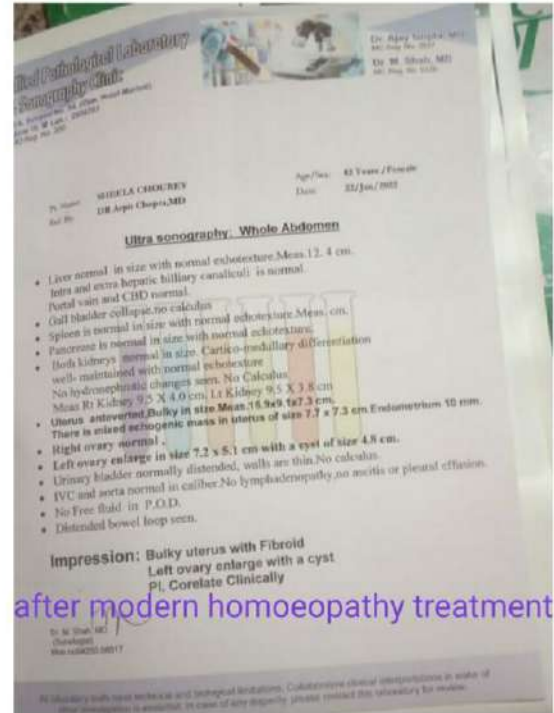फोन : 0731-4977076, मो. : 97130-92737, 97130-37737, 799999-78894, 99075-27914

www.homoeopathyure.in, www.aarogyahomoeopathyindore.com Email : arpit Chopra23@gmail.com

YouTube dr arpit chopra's super speciality modern homoeopathic, <https://g.page/r/CaRz52neBZQXEBA>



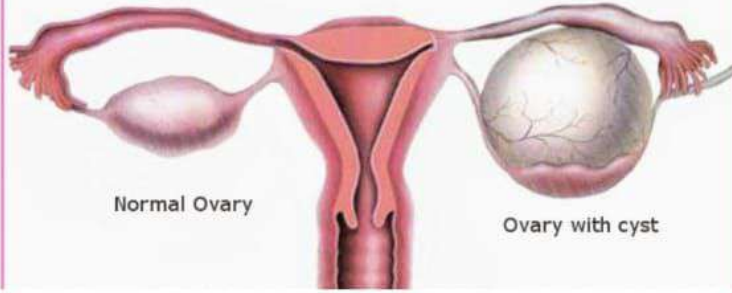
before modern homoeopathy treatment



after modern homoeopathy treatment

Ovarian Cysts

Fallopian Tube



Normal Ovary

Ovary with cyst

मॉडर्न होम्योपैथी
Modern Homoeopathy - Complete Permanent, Easy, Safe, Fast & Cost Effective Cure

DR. ARPIT CHOPRA JAIN
M.D. (HOMOEOPATHY)
Specialist and Professor, Aarogya Super Speciality Modern Homoeopathy Centre, Jabalpur (M.P.)
Phone: 97130-92737, 97130-37737, 97999-78894, 99075-27914

RITI AGARWAL
JABALPUR, M.P.

AAROGYA SUPERSPECIALITY MODERN HOMOEOPATHIC CLINIC
Complete, Safe, Fast & Cost-effective Permanent Modern Homoeopathy Cure with Advanced Lifestyle
Phone: 0731-4977076, Mobile: 97130-92737, 97130-37737, 79999-78894, 99075-27914

Smt. Manjua Saxena Memorial **SAXENA** Sonography, Color Doppler, Mammography & Digital X-Ray Centre
Roopam Towers, Opp. Water Tank, Near Chanchalabai College & Hanuman Mandir, Wright Town Jabalpur - 482 002 (M.P.)
Dr. R.K. Saxena M.D. (Radiology)
Phone: 0761-2401280

Name: MRS REETI AGRAWAL, 35/F, Date: 06/04/2022

WHOLE ABDOMEN SONOGRAPHY

- Liver measures approx 14.4 cms in crano-caudal axis. Its echostructure appears normal. No focal lesion is seen. No dilatation of intra or extra hepatic biliary radicles is seen.
- Gall bladder measures approx 4.5 x 1.5 cms. Its walls are mild thickened (3 mms). Multiple calculi of approx 6-8 mms are seen in the lumen which are casting distal acoustic shadowing.
- CBD measures 5 mms in caliber.
- Spleen appears normal in size, shape and echostructure.
- Pancreas appears normal in size, shape and echostructure. No focal lesion is seen. Pancreatic duct is not dilated.
- Both kidneys appear normal in size, shape & echostructure. Cortico-central differentiation is maintained. No pelvicalyceal or ureteral dilatation is seen on either side. No obvious calculus shadow is seen.
- Uterus measures approx 8.4 x 3.5 x 4.9 cms. Its shape & echostructure appears normal. The endometrial echo complex appears normal (Thickness is 6 mms).
- Right ovary measures approx 4.7 x 3.3 cms.
- Left ovary measures approx 3.4 x 1.9 cms. Right ovary appears enlarged in size. A follicular cyst approx. measures 3.1 x 1.9 cms with internal echoes is seen in it. Left ovary appears normal in size, shape and echostructure.
- Pouch of Douglas is clear.
- Urinary bladder appears normal in shape, contours and has thin walls.
- No pre/para aortic lymphadenopathy is seen.
- No free ascites is seen.

before treatment

IMPRESSION: SONOLOGICAL FINDINGS SUGGESTS-

(1) CHRONIC CHOLECYSTITIS WITH CHOLELITHIASIS.
(2) A SMALL FOLLICULAR CYST WITH INTERNAL ECHOES IN RIGHT OVARY (? DUE TO HAEMORRHAGE IN IT).

ADVISED: PLEASE CORRELATE CLINICALLY.

[Signature]
DR. R.K. SAXENA

Smt. Manjua Saxena Memorial **SAXENA** Sonography, Color Doppler, Mammography & Digital X-Ray Centre
Roopam Towers, Opp. Water Tank, Near Chanchalabai College & Hanuman Mandir, Wright Town Jabalpur - 482 002 (M.P.)
Dr. R.K. Saxena M.D. (Radiology)
Phone: 0761-2401280

Name: MRS REETI AGRAWAL, 35/F, Date: 03/04/2022
Adv. by: DR. ARPIT CHOPRA JAIN MD(HOMO)

WHOLE ABDOMEN SONOGRAPHY

- Gall bladder measures approx 8. x 2.4 cms. Its walls are thickened (3 mms). Multiple calculi of approx 6-8 mms are seen in the lumen which are casting distal acoustic shadowing.
- CBD measures 5 mms in caliber.
- Liver appears normal in size, shape and echostructure. No focal parenchymal lesion is seen. No dilatation of intra or extra hepatic biliary radicles is seen.
- Spleen appears normal in size, shape and echostructure.
- Pancreas appears normal in size, shape and echostructure. No focal lesion is seen. Pancreatic duct is not dilated.
- Both kidneys appear normal in size, shape & echostructure. Cortico-central differentiation is maintained. No pelvicalyceal or ureteral dilatation is seen on either side. No obvious calculus shadow is seen.
- Uterus measures approx 8.3 x 4 x 6 cms. Its shape & echostructure appears normal. The endometrial echo complex appears normal (Thickness is 7 mms). Right ovary measures 3.3x2.2 cms. and Left ovary measures 3.6x2.2 cms.
- Both ovaries appear normal in size, shape and echostructure.
- Pouch of Douglas is clear.
- Urinary bladder appears normal in shape, contours and has thin walls.
- No pre/para aortic lymphadenopathy is seen.
- No free ascites is seen.

after modern homoeopathy treatment

IMPRESSION: SONOLOGICAL FINDINGS SUGGESTS CHRONIC CHOLECYSTITIS WITH CHOLELITHIASIS.

ADVISED: PLEASE CORRELATE CLINICALLY.

[Signature]
DR. R.K. SAXENA

Ovarian cyst! Haemorrhagic
3.1 x 1.9 cm

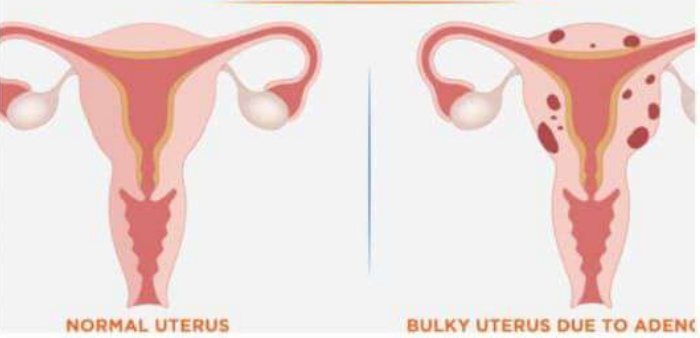
कैंसर, किडनी फेलियर, अस्पताल में गंभीर रूप से भर्ती मरिजों का उपचार, कोमा, शल्य चिकित्सा योग्य रोग, ऑटो इम्यून रोग, जीवनभर दवाई लेने वाले रोगों की रोकथाम एवं 300 प्रकार के असाध्य जटिल रोगों की चिकित्सा।

डॉ. अर्पित चौपड़ा (जैन)
एच. बी. होम्योपैथी जटिल, असाध्य एवं शल्य रोग विशेषज्ञ

आरोग्य सुपर स्पेशलिटी मॉडर्न होमियोपैथी
कम्पलिट, परमानेंट, ईजी, सेफ, फास्ट एण्ड कॉस्ट इफैक्टिव

102, प्रथम मंजिल, कृष्णा टॉवर, कयोरेल हॉस्पिटल के सामने, जंजीरवाला चौराहा, न्यू पलासिया,
99075 27914 संपर्क : 0731-4977076, 79999 78894
www.homoeopathycure.in. www.aarogvahomoeopathyindore.com. Email : arpitchopra23

BULKY UTERUS



Dr. Ravindra Kumar
KRUTI DIAGNOSTIC & MRI CENTRE
22, Jashwanth Nagar, Sector 14, Gurgaon, Haryana, INDIA - 122001
Phone: 97130-26205, 37737
+44 Sonography / Echocardiography / Color Doppler / Digital DPO

50 y F
Mrs. Vandana Sharma
Dr. Archana Maheshwari MS
Reg No: 62207

Demographic, Abdomen & TVS

The liver is normal in size & architecture.
The gall bladder is physiologically distended & no stones.
The spleen is normal.
The pancreas & spleen are normal in parenchymal collection seen.
Both kidneys are normal in position, size, contour & normal echotexture.
The uterine cervix is normal.
The urinary bladder is normal.
Transvaginal sonography reveals a bulky uterus measuring 14.4 cm in long axis & 7.1 cm in transverse axis.
The endometrial thickness is normal & homogeneous. The subendometrial echotexture is normal. This finding is suggestive of adenomyosis.
No adnexal masses. No free fluid in pouch of Douglas.

BEFORE MODERN HOMEOPATHY

CONCLUSION Normal liver, gall bladder, pancreas, spleen.
Enlarged uterus, adenomyosis, fibroids & cysts.
Mildly bulky uterus, adenomyosis with mild, bilateral, polycystic ovaries.
Fundamental Sonography. Cervix is upper part of uterus. (uterus, cervix)

Dr. Ravindra Kumar
KRUTI DIAGNOSTIC & MRI CENTRE
22, Jashwanth Nagar, Sector 14, Gurgaon, Haryana, INDIA - 122001
Phone: 97130-26205, 37737
+44 Sonography / Echocardiography / Color Doppler / Digital DPO

51 y F
Mrs. Vandana Sharma
Dr. Archana Maheshwari MS
31-Mar-22

Sonography Abdomen

The liver is normal in size & architecture.
The gall bladder is physiologically distended & no stones.
The pancreas & spleen are normal.
Both kidneys are normal in position, size, contour & normal echotexture.
The uterine cervix is normal & homogeneous. The endometrial thickness is normal & homogeneous.
The urinary bladder is normal & normal.
The uterus is anteroposteriorly slightly bulky & size measuring 12.8 cm in long axis & 6.6 cm transverse. The margins are smooth. The endometrial thickness is normal & homogeneous.
The endometrial echotexture is normal & homogeneous.
No adnexal masses. No free fluid in pouch of Douglas.

AFTER MODERN HOMEOPATHY

CONCLUSION Normal liver, gall bladder, pancreas, spleen.
Normal uterus, adenomyosis & cysts.
Slightly bulky uterus, adenomyosis.
Fundamental Sonography. Cervix is upper part of uterus. (uterus, cervix)

मोडर्न होमियोपैथी

Complete, Permanent, Easy, Safe, Fast & Cost Effective Cured

Cervical Polyp with Bulky Uterus 21

MARCH - MONDAY

मेरा नाम Vandana है मुझे कोणी पॉलीप से ग्रस्त थी। इस कारण से मैं अक्सर खून आने का अनुभव करती थी। डॉक्टरों से मैंने कई तरह के इलाज किए, लेकिन कोई फल नहीं मिला। मैंने आखिरकार डॉ. आरुणा मलहोत्रा से मिली। उन्होंने मेरी समस्या को ठीक करने में मेरी मदद की। मैंने अपना खून बंद कर लिया। मैं बहुत खुश हूँ।

डॉ. आरुणा मलहोत्रा

आरोग्य सुपर स्पेशलिटी मॉडर्न होमियोपैथी

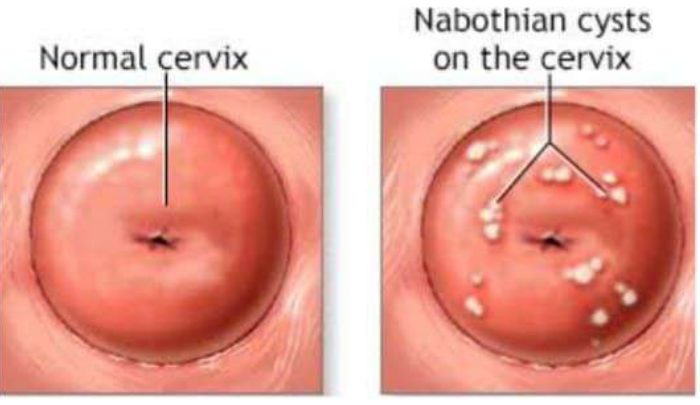
Permanent, Easy, Safe, Fast & Cost Effective Cured

आरोग्य सुपर स्पेशलिटी मॉडर्न होमियोपैथी

आरोग्य सुपर स्पेशलिटी मॉडर्न होमियोपैथी

ROGYA SUPERSPECIALITY MODERN HOMEOPATHY CURED WITH ADVANCED LITHIUM

Complete, Safe, Fast & Cost- Effective Modern Homeopathy Cured With Advanced Lithium
: 0731- 4977076, Mobile : 97130-92737, 97130-37737, 799999-78894, For Whatsaap, 990



कैंसर, किडनी फेलियर, अस्पताल में गंभीर रूप से भर्ती मरिजों का उपचार, कोमा, शल्य चिकित्सा योग्य रोग, ऑटो इम्यून रोग, जीवनभर दवाई लेने वाले रोगों की रोकथाम एवं 300 प्रकार के असाध्य जटिल रोगों की चिकित्सा।

आरोग्य सुपर स्पेशलिटी मॉडर्न होमियोपैथी

कम्प्लिट, परमानेंट, ईजी, सेफ, फास्ट एण्ड कॉस्ट इफेक्टिव

102, प्रथम मंजिल, कृष्णा टॉवर, कयोरेवेल हॉस्पिटल के सामने, जंजीरवाला चौराहा, न्यू पलासिया, इन्दौर म.प्र.
☎ 90075 27914 संपर्क : 0731-4977076, 799999-78894

मॉडर्न होमियोपैथी

AAROGYA SUPERSPECIALITY MODERN HOMEOPATHY

Complete, Permanent, Easy, Safe, Fast & Cost Effective Cure

भरपित चोपड़ा (जैन) मॉडर्न होम्योपैथी: महिलाओं सम्बंधित गंभीर बीमारियों का सफल इलाज

• डॉ. अरपित चोपड़ा (जैन) को केन्द्रीय स्वास्थ्य मंत्री श्री मनसुख मोदगिया द्वारा अवार्ड प्रदान किया गया।



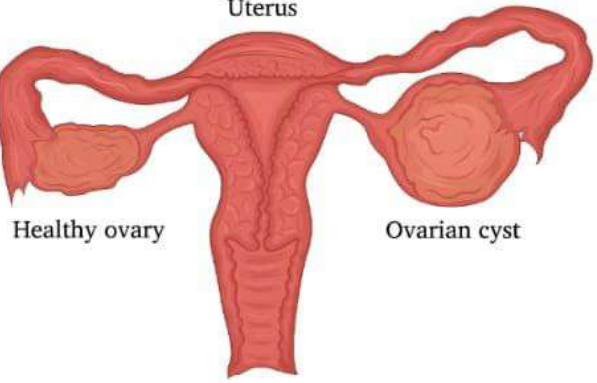
DR. ARPIT CHOPRA
M.D. HOMEOPATHY
CRITICAL AND SURGICAL DISEASE SPECIALIST
INVENTOR OF SUPER SPECIALITY MODERN HOMEOPATHY
MOB. 9907527914, 9731992731
www.aarogyasuperspeciality.com

18:48

ALL TYPES OF GYNAECOLOGICAL DISORDERS TREATED BY DR ARPIT CHOPRA, JAIN'S MODERN HOMEOPATHY
ONLINE CONSULTATION AVAILABLE : WWW.HOMOEOPATHYCURE.IN / WWW.AAROGYASUPERSPECIALITY.COM
@AAROGYA101 @AAROGYAMODERN48 @AAROGYAMHOMEOPATHY @9907527914 9909999994 9731992731

Ovarian cyst

Uterus



Healthy ovary

Ovarian cyst

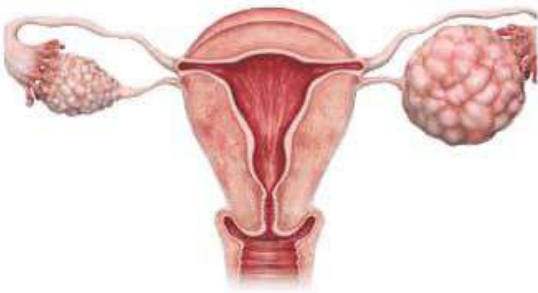कैंसर, किडनी फेलियर, अस्पताल में गंभीर रूप से भर्ती मरिजों का उपचार, कोमा, शल्य चिकित्सा योग्य रोग, ऑटो इम्यून रोग, जीवनभर दवाई लेने वाले रोगों की रोकथाम एवं 300 प्रकार के असाध्य जटिल रोगों की चिकित्सा।

आरोग्य सुपर स्पेशलिटी मॉडर्न होमियोपैथी
कम्प्लिट, परमानेंट, ईजी, सेफ, फास्ट एण्ड कॉस्ट इफैक्टिव
102, प्रथम मंजिल, कृष्णा टॉवर, कयोस्वेल हॉस्पिटल के सामने, जंजीरवाला चौराहा, न्यू पलासिया, इन्दौर म.प्र.
99075 27914 संपर्क : 0731-4977076, 79999 78894
www.homoeopathycure.in. www.aarogvahomoeopathyindore.com Email : arpit Chopra23@gmail.com

Hemorrhagic cyst on the ovary

आरोग्य
COMPLETE CURE EASY SAFE, FAST & COST EFFECTIVE
HOMOEOPATHY

POORNIMA AGARWAL
NARSINGHPUR (M.P)



Should You Be Worried About an
OVARIAN CYST?

मिर्चल
श्री. प्रो. डा. प्रमोद क. शर्मा
11, शांति नगर, पुराना दिल्ली, का. (ए.सी.) 110028, फोन : 27320-22041, 22042

PATIENT'S NAME : **SARFU BAI** DATE : **16/05/22**
CONSULTANT : **DR. KANAKA CHANDRAN** AGE : **35YRS**

CLUTERABSONEN

Clinical Profile: Pain in abdomen.

Examination:
USS of abdominal area performed on 16 May CT scanner with oral, rectal and b-spectrum. Coronal and sagittal reformatted images were obtained.

Findings:
Approx 43 x 40 x 28 mm sized well defined peripherally enhancing cystic lesion with low internal echogenic areas within wall in right adnexa with right ovary covered by low echogenicity suggest benign cystic lesion. Haemorrhagic cyst more likely. Uterus not seen (postmenstrual).

Lower pararenal appears normal and shows normal enhancement pattern. No focal or diffuse lesion is seen. Paraaortic lymph nodes are not dilated. Para-aortic lymphatic nodes are not enlarged. No evidence of retroperitoneal lymphadenopathy.

Both adrenal glands appear normal in size and enhancement pattern.

No definite enlarged parathyroid, paraneural, paracardiac or paracardiac lymph nodes are seen.

मिर्चल
श्री. प्रो. डा. प्रमोद क. शर्मा
11, शांति नगर, पुराना दिल्ली, का. (ए.सी.) 110028, फोन : 27320-22041, 22042

Abdominal pain, I/O, Clotting tests, coagulation parameters, urinary and rectal abdominal results appears unremarkable. No evidence of any metastasis for staging is seen.

Urinary bladder appears normal. No calculus, mass or diverticulum is seen.

Rectum appears normal. No definite evidence of perirectal fat or tubular connection is seen. No definite rectal wall thickening is noted.

Visceral wall of lower lungs and pleural spaces appears normal bilaterally.

Conclusion: The CT findings are:-

- Well defined peripherally enhancing cystic lesion with low internal echogenicity areas within wall in right adnexa with right ovary covered by low echogenicity suggest benign cystic lesion. Haemorrhagic cyst more likely.
- No evidence of focal liver lesion, lymphadenopathy or metastasis.

(Suggested clinical correlation/further evaluation if indicated)

BEFORE MODERN HOMEOPATHY TREATMENT

DR. PRATIK MITTAL
MD
Consultant Radiologist

DR. POOJA PRAJAPATI
MD
Consultant Radiologist



अर्चना सोनो सेंटर
SONOGRAPHY | COLOUR DOPPLER | DIGITAL X-RAY | ECHO-CARDIOGRAPHY

Dr. R.K. Gupta
M.B.B.S., M.D. (Radiology)
Reg. No. 2322
Consultant Radiologist & Sonologist

Dr. Mrs. Archana Gupta
M.B.B.S., M.D. (Gynaecology & Obstetrics)
Reg. No. 2322
Sonologist

Patients Name: Sarfu Bai Ramkaran
Referred by Dr: Arpit Chopra
Date: 17/5/2022

U S G ABDOMEN

(Due to technical limitations, and biological variations sonography report must be correlated clinically and with additional/exploratory)

Liver is normal in size and echopattern, no focal lesion seen. Biliary and portal radicles are normal.
Portal vein is normal.
Gallbladder is normal in size, smooth in outline, nonthiatric. C B D is normal in size.
Pancreas is normal in size and echopattern, no focal lesion seen.
Spleen is normal in size and echopattern, no focal lesion seen.

Both kidneys are normal in size and echopattern, p.c system is normal. Cortical thickness is normal.
Ureters are normal.
Urinary bladder is normal in size and nonthiatric outline is smooth.

Uterus is 110 days gestation pregnancy
Normal echopattern, no focal lesion
Endometrial echo is _____ cavity is empty
Cervix is _____
Cul de Sac _____
Both ovaries and adnexa show normal features

No free fluid or lymphadenopathy.
Major abdominal vessels are normal.

Sonography findings are within normal limits
Dr. Pratik

AFTER MODERN HOMEOPATHIC TREATMENT

डॉ. अमित बोधरा (जीव)
श्री. प्रो. डा. प्रमोद क. शर्मा
11, शांति नगर, पुराना दिल्ली, का. (ए.सी.) 110028, फोन : 27320-22041, 22042

आरोग्य

पेशा : 071-4877076, 4877076
फोन : 09800-13914, 09800-27914
वेबसाइट : www.aarogya.com
ईमेल : aarogya@aarogya.com

पेशा : 071-4877076, 4877076
फोन : 09800-13914, 09800-27914
वेबसाइट : www.aarogya.com
ईमेल : aarogya@aarogya.com


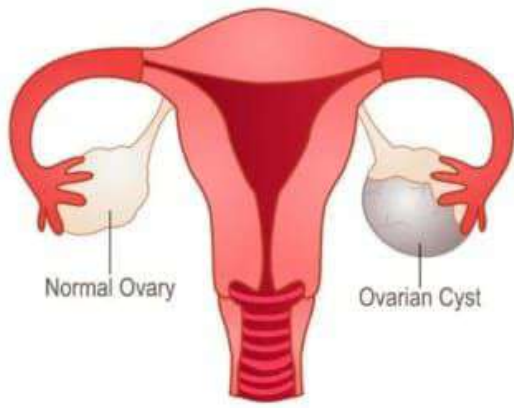
17/05/2022
Sarfai Bai 35 yrs F. unbalanced
Hypertension 12 years ago
Right Ovary cystic lesion 1 year
45x40x36mm
Hormonal: gut (Bdry)
Pain +
Anastha

कैंसर, किडनी फेलियर, अस्पताल में गंभीर रूप से बर्ती मरिजों का उपचार, कोमा, शल्य चिकित्सा योग्य रोग, ऑटो इम्यून रोग, जीवनभर दवाई लेने वाले रोगों की रोकथाम एवं 300 प्रकार के असाध्य जटिल रोगों की चिकित्सा।

आरोग्य सुपर स्पेशलिटी माईन होमियोपेथी
कम्प्लिट, परमानेंट, ईजी, सेफ, फास्ट एण्ड कॉस्ट इफेक्टिव

102, प्रथम मंजिल, कृष्णा टॉवर, कपोल्लत हॉस्पिटल के सामने, जे.जी.रावराव वीरानगर, न्यू पतारिया, इन्दौर म.प्र.
98076 27914 संपर्क : 0731-4877076, 79696 79694

Ovarian Cyst



NATIONAL SONOGRAPHY CENTRE
डॉ. कनिश कुशेशी
Dr. Danish Qureshi
 Consultant Radiologist & Ultrasonologist
 Consultant Radiologist, Sai Baba Hospital & HC, Indore
 Ex-Consultant: CH, Hospital, Indore

2D / 3D / 4D ULTRASOUND, COLOR DOPPLER, MUSCULOSKELETAL AND SMALL PARTS

Patient Name: Miss. Paragi
 Age: 29 Years
 Sex: Female
 Referring Doctor: Dr. Anup Patidar
 Date: 30.07.2022

ULTRASOUND PELVIS

FINDINGS:
 Uterus is anteverted, normal in size and echotexture and measures 7.3x4.4x3.8cm. Myometrial and endometrial echoes are normal.
 Endometrium measures 3mm.
 Both ovaries are normal in size and echotexture.
 Right ovary shows a thick walled cyst of size 3.6x3.2cm with few internal echoes & an irregular avascular area - ? Haemorrhagic Cyst with retracting clot.
 Left ovary: measures 2.4x1.4cm.
 No free fluid in PDD.

Adv. Follow up

before treatment

Address: 102, Fortune-7, Kalani Nagar Sqr., Near Mousa Jalebi, Airport Road, Indore
 Ph. : 0731-4911954, E-mail : nationalsonography@gmail.com

MEDICA SONOGRAPHY CENTRE
 11, Mangalad Centre Opp. State Bank of India, Anandnagar East, Indore (M.P.)
 Ph. - 0731-4911954

SONOGRAPHY & COLOR DOPPLER

Patient's Name: MISS PARAGI KESHURIA D/O. HARESH Dny. Date: 15-Aug-2022
 Age & Sex: 29 Yrs. Female
 Referred by: DR. ANUP PATIDAR MDCC
 Consultant: DR. ARUN TALWAR MDCC

WHOLE ABDOMEN SONOGRAPHY

Height contour is smooth & even (112.2 cm) & normal. Paravertebral echotexture is normal. CBD & Portal vein are normal in caliber. No focal lesions seen. No dilatation of any calyx or ureter. Gall bladder is normally distended. Visceromegaly not seen. No stones or sludge seen. Pancreas is normal in size & echotexture. No focal lesions seen. Peritoneum is normal. Spleen is normal (11.0 cm). No focal lesions seen. Kidneys are T2 X 5.8 cm in size and normal in position, echotexture and size. Calyces & ureters are normal. Left kidney is 9.2 X 4.2 cm in size and normal in position, echotexture and size. Uterus is anteverted & normal in size. Measures 6.2 x 3.2 x 4.2 cm. No focal lesions seen. Endometrium is 3 mm. Both ovaries & tubes are normal in size. No focal lesions seen. No significant lymphadenopathy seen. No free fluid seen in peritoneal cavity. T10 dependent pleural nodules are normal.

IMPRESSION: NO SIGNIFICANT ABNORMALITY SEEN.
 SUGGESTED CLINICAL CORRELATION

after Modern Homoeopathy treatment

Address: 102, Fortune-7, Kalani Nagar Sqr., Near Mousa Jalebi, Airport Road, Indore
 Ph. - 0731-4911954, E-mail : nationalsonography@gmail.com

15 MONDAY - AUGUST

Ovarian cyst

मेरा नाम परागी केशरिया है। मुझे 20 परागी की है। मुझे 30 अक्टूबर को सिस्टर का size - 3.5 x 3.4 x 3.2 था। मैंने 30 अक्टूबर को डॉ. अरुण तालवार को बताया। डॉ. अरुण तालवार ने मुझे 30 अक्टूबर को बताया कि मुझे 15 दिन में पूरी तरह स्वस्थ होना और 15 दिन में डॉ. अरुण तालवार को देखना।

धन्यवाद डॉ. अरुण तालवार जैन
 Date - 16/8/22

पर स्पेशलिटी मॉडर्न होम्योपैथिक क्लिनिक (जैन)

रोग विशेषज्ञ

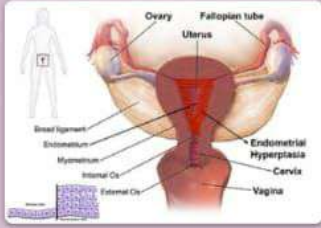फोन: 102-104 प्रथम कृष्णा टॉवर, कयोरेल हॉस्पिटल के सामने, जंजीरवाला चौराहा, न्यू पलारिया

कैंसर, किडनी फेलियर, अस्पताल में गंभीर रूप से भर्ती मरिजों का उपचार, कोमा, शल्य चिकित्सा योग्य रोग, ऑटो इम्यून रोग, जीवनभर दवाई लेने वाले रोगों की रोकथाम एवं 300 प्रकार के असाध्य जटिल रोगों की चिकित्सा।

आरोग्य सुपर स्पेशलिटी मॉडर्न होमियोपैथी
 कम्पलिट, परमानेंट, ईजी, सेफ, फास्ट एण्ड कॉस्ट इफैक्टिव

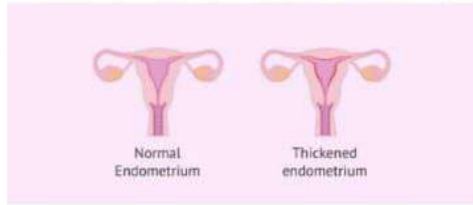102, प्रथम मंजिल, कृष्णा टॉवर, कयोरेल हॉस्पिटल के सामने, जंजीरवाला चौराहा, न्यू पलारिया, इन्दौर म.प्र.
 99075 27914 संपर्क: 0731-4977076, 79999 78894
 www.homoeopathycure.in, www.aarogyahomoeopathyindore.com, Email: arpitchohra23@gmail.com

Endometrial Hyperplasia



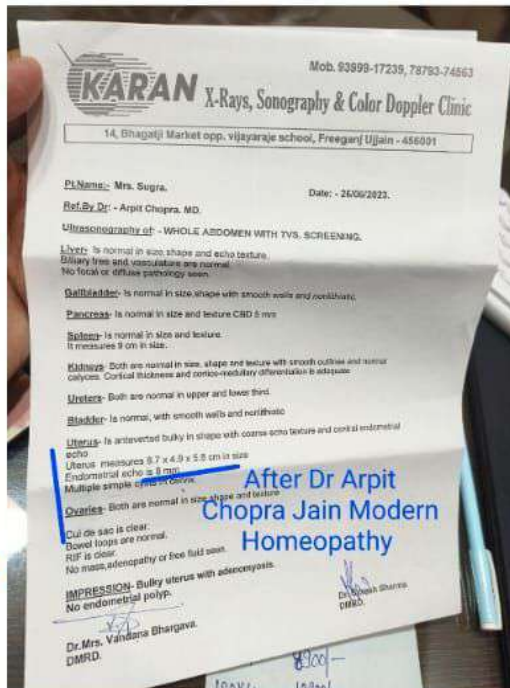

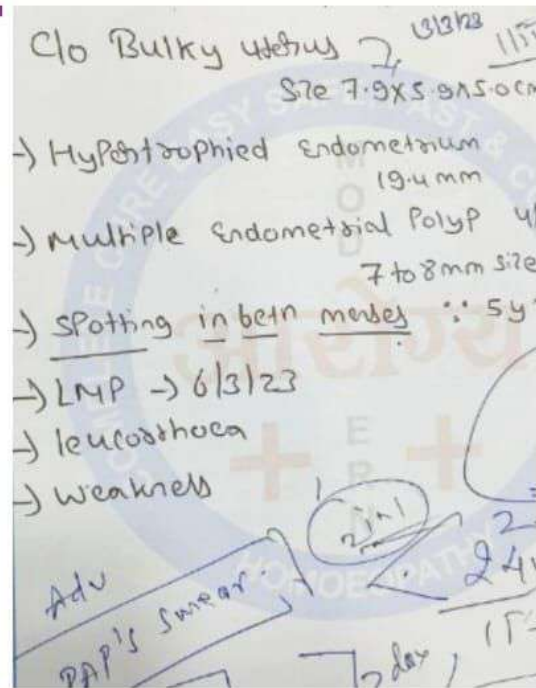
Endometrial hyperplasia occurs when the cells lining the endometrium (the inner lining of the uterus) multiples and becomes thickened. Endometrial hyperplasia is a pre-cancerous condition. There are two types of hyperplasia, endometrial hyperplasia without atypia and endometrial hyperplasia with atypia.

Normal endometrium and endometrium with hyperplasia



These hormones (estrogen and progesterone) act on the woman's menstrual cycle. The purpose of estrogens is to provoke cell growth of the endometrium, while progesterone indicates the moment of endometrial detachment.

For this reason, an imbalance in estrogen and progesterone values may be the cause of excessive and abnormal proliferation of



बच्चेदानी में सूजन
Bulky Uterus Cure | Endometrium Thicken...
Dr Arpit Chopra's SuperS...
747 views • 1 year ago

बच्चेदानी में सूजन
का सफल इलाज
मौखिक होम्योपैथी से
सर्वसेस 4:00

बच्चेदानी में सूजन
का सफल इलाज
मौखिक होम्योपैथी से
Dr Arpit Chopra's SuperS...
88 views • 1 year ago

BULKY UTERUS
SURGICAL ADVISED
CASE CURED
सर्वसेस 18:39

सर्वसेस स्टोरी
CERVICAL NABOTHIAN CYST
का सफल इलाज
Dr Arpit Chopra's SuperS...

OVARIAN CYST
किसका
सफल इलाज
सर्वसेस 16:56

OVARIAN CYST
किसका
सफल इलाज
सर्वसेस 20:30

BULKY UTERUS
SURGICAL ADVISED
CASE CURED
सर्वसेस 18:39

OVARIAN CYST
किसका
सफल इलाज
सर्वसेस 17:05

OVARIAN CYST
किसका
सफल इलाज
सर्वसेस 18:02

OVARIAN CYST
किसका
सफल इलाज
सर्वसेस 17:05

OVARIAN CYST
किसका
सफल इलाज
सर्वसेस 18:48

OVARIAN CYST
किसका
सफल इलाज
सर्वसेस 38:07

OVARIAN CYST
किसका
सफल इलाज
सर्वसेस 1:00

OVARIAN CYST
किसका
सफल इलाज
सर्वसेस 6:08

UTERINE FIBROID & BULKY UTERUS, CYSTITIS CURED
Dr Arpit Chopra's SuperS...
185 views • 8 months ago

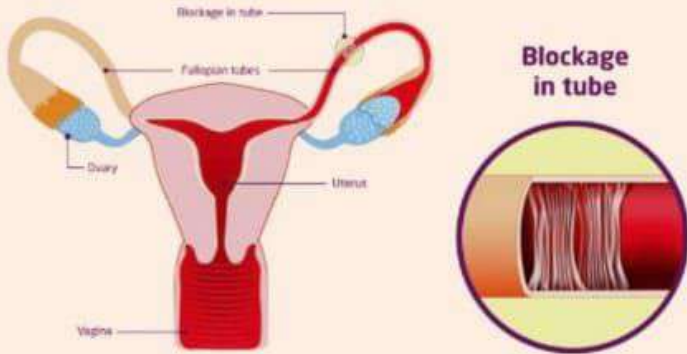
FEMALE GYNAECOLOGY DISE...
Dr Arpit Chopra's SuperS...
212 views • 7 months ago

GALL BLADDER STONE & UTERINE POLYP OF CUR...
Dr Arpit Chopra's SuperS...
152 views • 5 months ago

GALL BLADDER STONE & UTERINE POLYP OF CUR...
Dr Arpit Chopra's SuperS...
237 views • 5 months ago

UTERINE FIBROID WITH BULKY UTERUS CURED WI...
Dr Arpit Chopra's SuperS...
167 views • 5 months ago

Blocked Fallopian Tubes Treatment



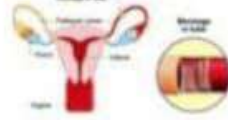Blockage in tube

Blocked Fallopian Tubes Treatment

मॉडर्न होम्योपैथी

Khilashwari Sahu

Dr. Arpit Chopra (Dr.)
AAROGYA SUPERSPECIALITY MODERN HOMEOPATHY CLINIC
Complete, Safe, Fast & Cost Effective Modern Homeopathy Care With Advanced Lifestyle
Phone: 0731-4977076, 97130-37737, 97130-37737, 79999-78894, For WhatsApp: 99075-27914



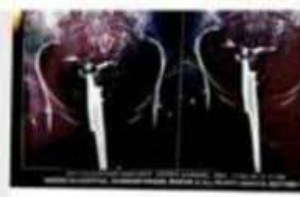
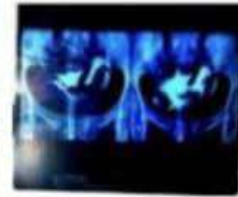Dr. Arpit Chopra (Dr.)
AAROGYA SUPERSPECIALITY MODERN HOMEOPATHY CLINIC
Complete, Safe, Fast & Cost Effective Modern Homeopathy Care With Advanced Lifestyle
Phone: 0731-4977076, 97130-37737, 97130-37737, 79999-78894, For WhatsApp: 99075-27914

before treatment

Dr. Arpit Chopra (Dr.)
AAROGYA SUPERSPECIALITY MODERN HOMEOPATHY CLINIC
Complete, Safe, Fast & Cost Effective Modern Homeopathy Care With Advanced Lifestyle
Phone: 0731-4977076, 97130-37737, 97130-37737, 79999-78894, For WhatsApp: 99075-27914

Ruprela

Dr. Arpit Chopra (Dr.)
AAROGYA SUPERSPECIALITY MODERN HOMEOPATHY CLINIC
Complete, Safe, Fast & Cost Effective Modern Homeopathy Care With Advanced Lifestyle
Phone: 0731-4977076, 97130-37737, 97130-37737, 79999-78894, For WhatsApp: 99075-27914



H/O -> IVF failed : 2020
(Twice)
Before Treatment
c/o - Infertility
BIL tubal blockage -> Repeated
oestrogen : 911.74 (1/2/23)
AMH : 3.74 (2020)
Mentel Jugalah e Nehmat

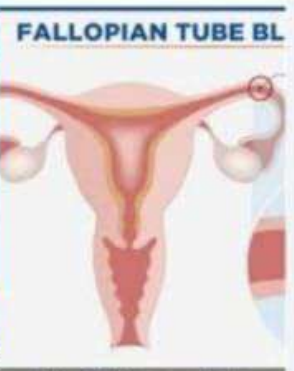SODANI DIAGNOSTIC CLINIC

Dr. Arpit Chopra (Dr.)
AAROGYA SUPERSPECIALITY MODERN HOMEOPATHY CLINIC
Complete, Safe, Fast & Cost Effective Modern Homeopathy Care With Advanced Lifestyle
Phone: 0731-4977076, 97130-37737, 97130-37737, 79999-78894, For WhatsApp: 99075-27914

घोषपैथी

Babita Karma

MODERN HOMEOPATHIC CLINIC
Complete, Safe, Fast & Cost Effective Modern Homeopathy Care With Advanced Lifestyle
Phone: 0731-4977076, 97130-37737, 97130-37737, 79999-78894, For WhatsApp: 99075-27914



Dr. Arpit Chopra (Dr.)
AAROGYA SUPERSPECIALITY MODERN HOMEOPATHY CLINIC
Complete, Safe, Fast & Cost Effective Modern Homeopathy Care With Advanced Lifestyle
Phone: 0731-4977076, 97130-37737, 97130-37737, 79999-78894, For WhatsApp: 99075-27914

Dr. Arpit Chopra (Dr.)
AAROGYA SUPERSPECIALITY MODERN HOMEOPATHY CLINIC
Complete, Safe, Fast & Cost Effective Modern Homeopathy Care With Advanced Lifestyle
Phone: 0731-4977076, 97130-37737, 97130-37737, 79999-78894, For WhatsApp: 99075-27914

आरोग्य स्वर स्पेशलिटी मॉडर्न होम्योपैथिक वर्गीय क

Dr. Arpit Chopra (Dr.)
AAROGYA SUPERSPECIALITY MODERN HOMEOPATHY CLINIC
Complete, Safe, Fast & Cost Effective Modern Homeopathy Care With Advanced Lifestyle
Phone: 0731-4977076, 97130-37737, 97130-37737, 79999-78894, For WhatsApp: 99075-27914

www.homeopathycure.in, www.aarogyahomeopathyindore.com Email: arpitchoopra23@gmail.com

102, पाप मंजिल, कृष्णा टॉवर, क्रांतिवेल हीमपथ के मार्ग, क्रांतिवेल कॉम्प्लेक्स, न्यू क्रांतिवेल, इन्डोर (म.प.)
फोन : 0731-4977076, फोन : 97130-37737, 97130-37737, 79999-78894, 99075-27914

Dr. Arpit Chopra (Dr.)
AAROGYA SUPERSPECIALITY MODERN HOMEOPATHY CLINIC
Complete, Safe, Fast & Cost Effective Modern Homeopathy Care With Advanced Lifestyle
Phone: 0731-4977076, 97130-37737, 97130-37737, 79999-78894, For WhatsApp: 99075-27914

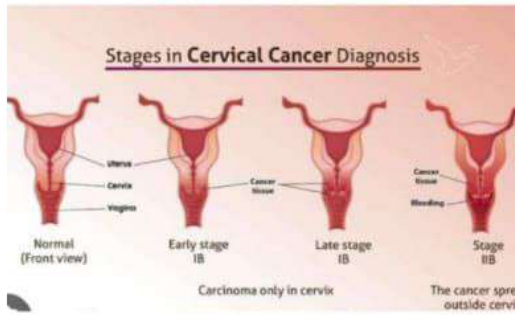
CAUSES OF FEMALE INFERTILITY

Endometriosis
Fallopian Tube Blockage
Tubal Infection

COMPLETE CURE, EASY, SAFE, FAST & COST EFFECTIVE

आरोग्य

High-risk HPVs can cause several types of cancer. There are about 14 high-risk HPV types including HPV 16, 18, 31, 33, 35, 39, 45, 51, 52, 56, 58, 59, 66, and 68. Two of these, **HPV16 and HPV18**, are responsible for most HPV-related cancers. 04-Apr-2023



Is HPV 16 a cancer?

ह्यूमन पेपिलोमावायरस टाइप 16 क्या है?

ह्यूमन पेपिलोमावायरस टाइप 16 (एचपीवी 16) सर्वाइकल कैंसर का प्राथमिक कारण है, जो दुनिया भर में महिलाओं में कैंसर का दूसरा सबसे आम प्रकार है (29)

HPV 16 : +ve (2/4/23)
 Biopsy : NEGATIVE for
 HSV Lt2 IGG : 1.67 (7/6)
 HSV Lt2 IGM : 0.69
 NO - OPERATED CASE OF
 TREATED CASE OF ADENO

aditya Microbiology & Molecular Diagnostics
 Sayash C.H.S., Sect. 2, Opp. Shriani Hotel, New Parvati, New Mumbai, Cell: +91 98524 88844 • Tel: 022 2748...

LAB NO.: 2853
 PATIENT NAME: Aashu Hassan
 REF. BY DR.: Dr. Venus Hospital
 SAMPLE COLL. AT: R.Vision Path Lab

DATE OF COLL.: 03-Apr-2023
 SEX: Female
 AGE: 35 Years
 REPORT DATE: 04-Apr-2023

HPV DNA Detection
Before Treatment

TEST: Detected HPV (Human Papilloma Virus) High-Risk Type Associated with Cervical Cancer

SAMPLE: Cervical Swab

HPV16: Detected

HPV18: NOT Detected

Other High Risk HPV: NOT Detected

CONCLUSION: HPV 16 DNA was detected in the present sample.

aditya Microbiology & Molecular Diagnostics
 Sayash C.H.S., Sect. 2, Opp. Shriani Hotel, New Parvati, New Mumbai, Cell: +91 98524 88844 • Tel: 022 2748...

LAB NO.: 2853
 PATIENT NAME: Aashu Hassan
 REF. BY DR.: Dr. Venus Hospital
 SAMPLE COLL. AT: R.Vision Path Lab

DATE OF COLL.: 03-Apr-2023
 SEX: Female
 AGE: 35 Years
 REPORT DATE: 04-Apr-2023

HPV DNA Detection
After Dr Arpit Chopra Jain Modern Homoeopathy

TEST: Detected HPV (Human Papilloma Virus) High Risk Type Associated with Cervical Cancer

SAMPLE: Cervical Swab

HPV16: Detected

HPV18: NOT Detected

Other High Risk HPV: NOT Detected

CONCLUSION: HPV 16 DNA was detected in the present sample.

मॉडर्न होम्योपैथी

Aarogya Super Speciality ...
 CERVICAL CERVIX CANC...

आप सर्वाइकल कैंसर से परेशान हैं कैसे खत्म करें

Dr. Arpit Chopra Jain
 Treatment Of Cervical Cancer By Modern Homeopathy

33:40

YouTube
 Cervical Cancer Cured By Dr ...

भारतीय कैंसर के लक्षण और उपचार

CERVICAL CANCER
 CARCINOMA CERVIX
 Treatment

Dr. Arpit Chopra

Specialty 10:33
 Aarogya Super Speciality Modern Homeopathy Clinic

YouTube
 CERVICAL CANCER CARCIN...

Dr. Arpit Chopra Jain
 (MD Homoeopathy
 Critical & Surgical
 Case Specialist)

Cervical Cancer
 RECENTLY DIAGNOSED
 CHRONIC
 PROBLEM CURED

सर्वसेस स्टोरी
 मॉडर्न होमियोपैथी के द्वारा

Mrs. Prathna Gaur

Aarogya Super Speciality ...
 CERVICAL CERVIX CANC...

Dr. Arpit Chopra Jain
 स्ना. शि. होम्योपैथी
 आरोग्य सुपर स्पेशलिटी
 क्लिनिक, अरावली रोड
 खारज रोड, दिल्ली

आरोग्य सुपर स्पेशलिटी मॉडर्न होमियोपैथिक वर्ल्डविक
 कम्पलिट * परमानेंट * ईजी * सेफ * फास्ट एण्ड कॉस्ट इफैक्टिव

* कैंसर * किडनी फेलियर * अस्पताल में जागीर
 रूप से भारी गरिजों का उपचार * कोणा
 * शल्य चिकित्सा योग्य रोग * आंटी इन्फ्यूजन रोग
 * जीवनरत्न दवाई लेने वाले रोगों की रोकथाम
 एवं 300 प्रकार के असाध्य जातिन रोगों की चिकित्सा

102, प्रथम मॉडर्न, कृष्णा टॉवर, क्योरवेल हॉस्पिटल के सामने, जॉर्जवाला चौराहा, न्यू फर्मासिया, इन्दौर (म.प्र.)
 फोन : 0731-4977076, मो: 97130-92737, 97130-37737, 799999-78894, 99075-27914

www.aarogyahomeopathyindore.com Email: arpitchopra23@gmail.com

COMPLETE CURE EASY SAFE, FAST & COST EFFECTIVE
 आरोग्य
 MODERN
 HOMOEPATHY

कैंसर, किडनी फेलियर, अस्पताल में गंभीर रूप से भर्ती मरिजों का उपचार, कोमा, शल्य चिकित्सा योग्य रोग, ऑटो इम्यून रोग, जीवनभर दवाई लेने वाले रोगों की रोकथाम एवं 300 प्रकार के असाध्य जटिल रोगों की चिकित्सा।



डॉ. अर्पित चौपड़ा (जैन)
एम. डी. होम्योपैथी
जटिल, असाध्य एवं
शल्य रोग विशेषज्ञ

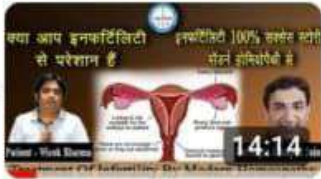आरोग्य सुपर स्पेशलिटी मॉडर्न होमियोपैथी

कम्पलिट, परमानेन्ट, ईजी, सेफ, फास्ट एण्ड कॉस्ट इफैक्टिव

102, प्रथम मंजिल, कृष्णा टॉवर, क्योरवेल हॉस्पिटल के सामने, जंजीरवाला चौराहा, न्यू पलासिया, इन्दौर म.प्र.

📞 99075 27914 संपर्क : 0731-4977076, 79999 78894

www.homoeopathycure.in. www.aarogyahomoeopathyindore.com Email : arpitchopra23@gmail.com



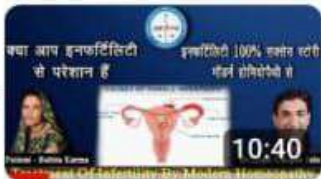Infertility Male Impotency of 7 Years...

Dr Arpit Chopra's SuperS...
437 views • 3 years ago



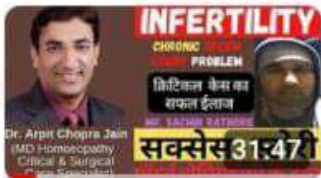Male Infertility impotency oligosper...

Dr Arpit Chopra's SuperS...
435 views • 3 years ago



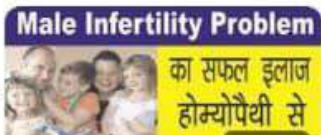FEMALE INFERTILITY CURE FOR BILATERA...

Dr Arpit Chopra's SuperS...
629 views • 3 years ago



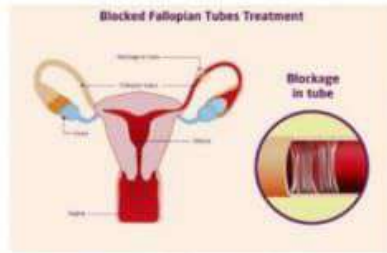Male infertility OLIGOSPERMIA Cure...

Dr Arpit Chopra's SuperS...
278 views • 1 year ago

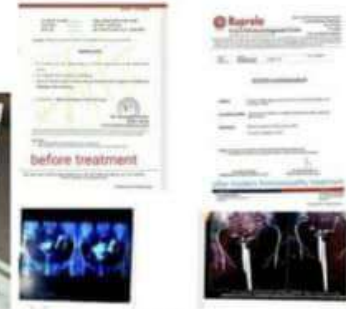

Male Infertility Problem का सफल इलाज होम्योपैथी से

Dr Arpit Chopra's SuperS...

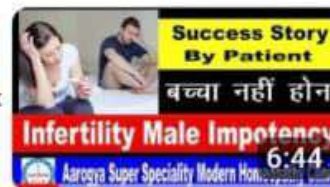
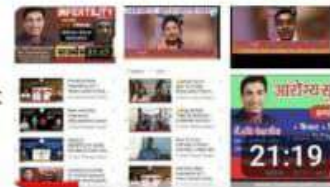
Blocked Fallopian Tubes Treatment



Male & Female Infertility cured by Dr ...

Dr Arpit Chopra's SuperS...
178 views • 1 year ago



Male infertility Cured | Oligospermia Succes...

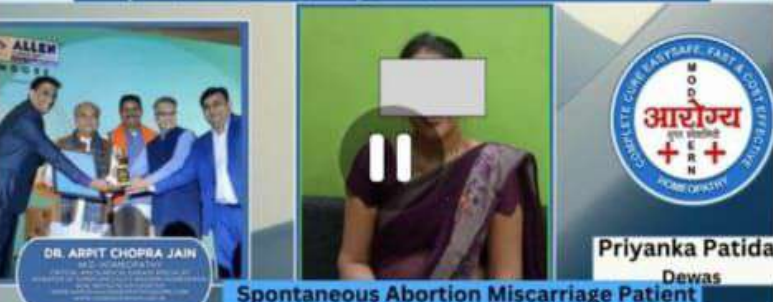Dr Arpit Chopra's SuperS...
154 views • 1 year ago



Male Infertility impotency oligosper...

आरोग्य सुपरस्पेशलिटी मॉडर्न होमियोपैथी

Complete, Permanent, Easy, Safe, Fast & Cost Effective Cure



ONLINE CONSULTATION AVAILABLE : 📞 9907527914, 7999978894, 9713037737, 9713062737 📞 0731-4977076

📧 @AAROGYAI 📧 @AAROGYAMODERN 📧 @AAROGYAHOMEOPATHY 📧 WWW.AAROGYAHOMEOPATHYINDORE.COM/HOMEOPATHY

02.103.104 1st Floor, Krishna Tower, Opposite Carewell Hospital, Janjeerwala Chouraha, New Palasia, Indore M.P.

NAME - Mrs. Swati Shrivastava
 REF. BY - Dr. Vaishali Gupta BAMS
 AGE - 42 Y/F
 DATE- 14/01/2023

E.S.G. WHOLE ABDOMEN

Liver is normal in size (13.76 cm) shape and has smooth echotexture. Hepatic echotexture is normal. No focal lesion is seen. Intrahepatic biliary radicals and portal-venous system is normal.

Gall bladder is normal in size, has thin walls and lumen is echo free. The CBD is normal. Pancreas is normal in size and echotexture.

Spleen is normal in size and has normal homogeneous parenchyma. Size - 5.51 cm.

Both kidneys are normal in size, shape outline & position. Renal parenchymal echotexture is normal and Pelvic/ureteric system - not dilated. Cortico-medullary ratio is maintained.

Right kidney size- 8.87 x 3.36 cm. Left kidney size- 8.43 x 2.23 cm.

Both ureters are normal in course and radiated.

IVC and aorta are normal in caliber.

No para aortic mesenteric lymphadenopathy is seen. No ascites or free fluid is seen.

Urinary bladder is normal in shape and echo free.

Uterus is anteverted and bulky. Myometrium is homogeneous. No focal lesion is seen. (L: 9.53 T: 5.81 AP: 4.88 cm)

Endometrium echo is 13.5 mm in thickness and in mid line.

Right ovary is normal in shape and size. Right is 2.57 cm.

A hypo echoic cystic mass is seen in left ovary. Margins are smooth and regular. Size is 3.25 x 2.87 cm.

No free fluid is seen in cul de sac.

Before Treatment

IMPRESSION - Bulky uterus
 Simple left ovarian cyst

श्रीनाथजी सेवा संस्थान
 आयुर्वेदिक-होम्योपैथी
 Pathology, Biopsy, X-ray, Sonography

पु.जी.-2 शिवराज वृद्धाश्रम, 118 रेकी अहिमा मार्ग, चिन्मयारा कोला, इंदौर नग. पोस्ट: 0731-497475, 81005-34579
 मुख्य शस्त्रालय: 22, चिन्मय नगर रोड, चिन्मय नगर, इंदौर नग. पोस्ट: 0731-4947911

Name: MRS. SWATI SHIVASTAVA Age: 42 Y Sex: F Date: 14/01/2023
 Ref. By: DR. VAISHALI GUPTA

WHOLE ABDOMEN SONOGRAPHY

The liver is normal in size (13.1 cm), shape and echotexture. Intrahepatic biliary tree and venous radicals are normal. The portal vein and CBD appear normal.

The gall bladder is well distended, with normal wall thickness & is noncalculic. Pancreas and spleen are normal in size (9.5 cm), shape and echotexture.

Both kidneys are normal in size, shape position & echotexture. The renal outlines are smooth.

Right kidney - 9.4 x 3.5 cm. Left kidney - 9.8 x 4.2 cm.
 Cortico-medullary differentiation is well maintained. No evidence of hydronephrosis or calculi on either side. Both ureters are unobstructed.

Abdominal aorta and I.V.C. are normal. No lymphadenopathy or ascites. Both pleural angles are clear.

The urinary bladder is well distended, with normal wall thickness & is noncalculic. The uterus is anteverted, measures about 8.5 x 5.8 x 4.9 cm. Contains smooth Myometrial echotexture is homogeneous. Endometrial echo thickness measures about 7.6 mm. Both lips of cervix appears bulky. Few cervical nabothian cysts are noted up to 3 mm in size. No free fluid is seen in the region of cul de sac.

Both ovaries are normal.
 No adnexal mass.
 No free fluid in the P.O.D.

After Dr Arpit Chopra Jain Modern Homoeopathy

Dr. S. Mishra
 Consultant Radiologist
 D.M.R.D., D.I.B. Radiodiagnosis
 Reg. No. MP-7899

Dr. R. Thakur
 M.D. Urologist
 Reg. No. MP-7899

Ovarian Cyst

Aarogya Super Speciality ... LARGE OVARIAN CYST CURE...

Aarogya Super Speciality ... Ovarian Cyst 3.1 cm cured w...

BULKY UTERUS SURGICAL ADVISED CASE CURED

Ovarian cyst

Alter Dr Arpit Chopra Jain Modern Homoeopathy

Breast cancer

3 days ago

सक्सेस स्टोरी
CERVICAL NABOTHIAN CYST
 गर्भाशय में गठान की गंधर बीमारी से छुटकारा दिना आपरेसन
 मॉडर्न होमियोपैथी के द्वारा

बच्चेदानी
 कारण लक्षण इलाज

16:46
 2:39

YouTube
 Cervical Nabothian Cyst with...
 Ovarian Cyst Cure

Dr. Arpit Chopra Jain - Book

COMPLETE CURE, EASY, SAFE, FAST & COST EFFECTIVE

आरोग्य
 MODERN HOMOEOPATHY

आरोग्य सुपर स्पेशलिटी मॉडर्न होमियोपैथी

UTERINE FIBROIDS

2 days ago
 6 days ago

Facebook
 Aarogya modern homoeopat...
 Aarogya modern h

Aarogya Super Speciality ... CERVICAL NABOTHIAN CYS...

Bulky Uterus PCOD Cervix

महिलाओं में पाई जाने वाली कॉमन स...
 2:53

YouTube
 Ovarian Cyst Cured | Multip

Facebook
 Aarogya modern homoeopat...

क्या आप ओवेरियन सिस्ट से परेशान हैं

ओवेरियन सिस्ट को कैसे खत्म करें

Dr. Arpit Chopra Jain
 Patient - Yogita Lad
Treatment of ovarian cyst By Modern Homeopathy

YouTube
 OVARIAN CYST CURED IN 1 ...

BULKY UTERUS
 SURGICAL ADVISED CASE CURED
 किर्किटल केस का सफल इलाज

सक्सेस स्टोरी
 मॉडर्न होमियोपैथी के द्वारा

18:39

YouTube
 Bulky Uterus Cure|Endometri...

Aarogya Super Speciality ... Uterine Fibroid with Bulky Ut...

6 days ago

ऑपरेशन या सर्जरी के बगैर पाए अपनी समस्याओं का इलाज

5:45

DR. ARPIT CHOPRA JAIN

कैंसर, किडनी फेलियर, अस्पताल में गंभीर रूप से भर्ती मरिजों का उपचार, कोमा, शल्य चिकित्सा योग्य रोग, ऑटो इम्यून रोग, जीवनभर दवाई लेने वाले रोगों की रोकथाम एवं 300 प्रकार के असाध्य जटिल रोगों की चिकित्सा।

आरोग्य सुपर स्पेशलिटी मॉडर्न होमियोपैथी
 कम्पलिट, परमानेंट, ईजी, सेफ, फास्ट एण्ड कॉस्ट इफैक्टिव

डॉ. अर्पित चौपड़ा (जैन)
 एच. डी. होमियोपैथी जटिल, असाध्य एवं शल्य रोग विशेषज्ञ

102, प्रथम मंजिल, कृष्णा टॉवर, कयोरेवेल हॉस्पिटल के सामने, जंजीरवाला चौराहा, न्यू पलासिया, इन्दौर म.प्र.
 99075 27914 संपर्क : 0731-497076, 79999 78894
 www.homoeopathycure.in, www.aarogyahomeopathyindore.com Email : arpit Chopra23@gmail.com

कैसर, किडनी फेलियर, अस्पताल मे गंभीर रूप से
 भर्ती मरिजों का उपचार, कोमा, शल्य चिकित्सा योग्य रोग,
 ऑटो इम्यून रोग, जीवनभर दवाई लेने वाले रोगो की रोकथाम एवं
 300 प्रकार के असाध्य जटिल रोगों की चिकित्सा।



डॉ. अर्पित चौपडा (जैन)
 एम. डी. होम्योपैथी
 जटिल, असाध्य एवं
 शल्य रोग विशेषज्ञ

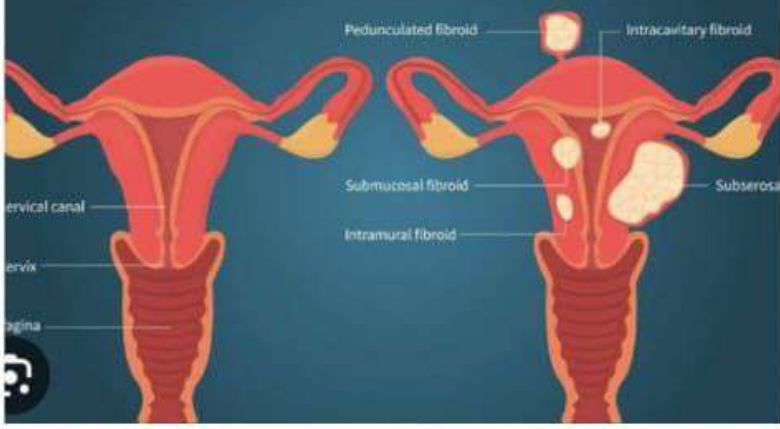
आरोग्य सुपर स्पेशलिटी माईन होमियोपेथी
 कम्पलिट, परमानेंट, ईजी, सेफ, फास्ट एण्ड कॉस्ट इफैक्टिव

102, प्रथम मंजिल, कृष्णा टॉवर, क्योरवेल हॉस्पिटल के सामने, जंजीरवाला चौराहा, न्यू पलासिया, इन्दौर म.प्र.

99075 27914 संपर्क : 0731-4977076, 79999 78894

www.homoeopathycure.in. www.aarogvahomoeopathyindore.com Email : arpit Chopra23@gmail.com

UTERINE FIBROIDS



of excessive and abnormal proliferation of

NOON HOSPITAL & RESEARCH CENTRE
 Jhalawar Road, Bhawani Mandi 326502

Both kidneys show increased attenuation of cortex with poor corticomedullary demarculation.
 Peri-renal fat stranding seen bilaterally. Bilateral anterior renal, posterior renal and laterofascial fasciae are thickened.
 No evidence of calculus or hydronephrosis.
 Renal pelvis-contrast normal.

Ureters:
 Both ureters appear normal in course and calibre. Minimal Peri-ureteric fat stranding seen on both sides.
 No evidence of ureteric calculus / obstruction seen.

Urinary Bladder:
 The urinary bladder is distended showing abnormal irregular wall thickening. The mural thickness is approximately 7 mm. Mild perivesical fat stranding is also noted.

Gastrointestinal Tract:
 Stomach is distended with normal gastric wall thickness.
 Esophagus (to 4th level) is normal.
 Visceralis small and large bowel loops appear normal in calibre.
 Appendix and surrounding soft tissue in right iliac fossa appears unremarkable.
 Cecal junction appears defined.
 Colon is predominantly faecal loaded and is unremarkable.
 Rectum appears normal in size. The perirectal fat planes are intact.

Tortus and Adnexa:
 Uterus is enlarged in size ms = 8.7 x 6.6 x 8.8 CM and shows a well-defined heterogeneous lesion of size ms = 2.0 x 5.4 x 5.1 cm at subserosal region of fundus suggestive of subserosal fibroid. Few hypodense areas are seen within it. Bilateral ovaries are not well visualized.

Miscellaneous:
 No evidence of free fluid in abdomen or pelvis.
 No significant mesenteric or retroperitoneal lymphadenopathy observed.
 Major abdominal vessels appear unremarkable. Few calcified atherosclerotic plaques are seen in abdominal aorta and its major branches.
 Patchy areas of ground glass opacities are seen in both lower lobes at pleural. Bilateral minimal pleural effusion with underlying passive collapse-consolidation of basal segments of bilateral lower lobes is noted.
 Moderate cardiomegaly noted- 2-D Echo is advised.
 Moderate vertebral show degenerative changes in the form of marginal anterior and posterior osteophytes.

IMPRESSION:
 Bilateral renal increased attenuation of cortex with poor corticomedullary bilaterally chronic kidney disease.
 Bilateral acute pyelonephritis with urethritis and cystitis without obvious evidence of calculus along the ureter.

Before Treatment

Dr. Arpit Chopra
 Jhalawar Road, Bhawani Mandi 326502, Dist. Jhalawar, Madh. Pr. India
 Tel: 011-997329312, 01475-223049

समर्पण
 Imaging & Diagnostics

15-20, Ground Floor, Yashwant Plaza,
 Opp. Railway Station, Indore (M.P.)
 22/2, Yashwant Niwas Road, Indore (M.P.)
 Plot No.2, Dussehra Maidan Road, Brawaripur
 Colony, Annapurna Main Road, Indore (M.P.)
 www.samarpanimaging.com

Patient ID: SMR01191223	Patient Name: LALITA CHOUHAN 51Y/F
Age: 51 Years	Sex: F
Referring Physician: DR ARPIT GHOPRA JAIN	Modality: MR
Study Date: 19-Dec-2023	Study: WHOLE ABDOMEN

MR: WHOLE ABDOMEN

TECHNIQUE:- AXIAL: FSPGR & T2, SAGITTAL: T2, CORONAL: FSPGR & STIR

CLINICAL:- Ms Lalita Chouhan is under evaluation for abdominal pain.

IMAGING FINDING :-
 Mild hepatomegaly is seen, with no evidence of focal lesion within. The spleen appears normal.
 The gallbladder is well distended with layering of sludge within. There is no evidence of cholelithiasis or cholecystochlithiasis. No intrahepatic biliary radical dilatation is seen.
 The pancreas appears rather atrophic, with no evidence of focal lesion within. The adrenals appear normal.
 Both the kidneys appear normal in size and shape with mild changes of sinus lipomatosis. No focal lesion is seen. The ureters are not dilated.
 The urinary bladder is partially distended and appears unremarkable.
 The retroverted uterus appears normal in size with poor zonal differentiation. The endometrial cavity appears normal. Small subcentimetre sized fibroid nodules are seen. Both the ovaries appear clear.
 There is no ascites or significant abdominopelvic lymphadenopathy.
 No obstructive bowel dilatation is seen. The visualized bowel show normal signal intensity.

IMPRESSION:-
 Mild hepatosplenomegaly is seen without focal lesion. Sludge is seen in the gallbladder lumen.
 No other significant or relevant abnormality is seen in this study.

After Dr Arpit Chopra Jain Modern Homoeopathy

DR. ANISH KUMAR SHARMA
 MD (Radiology)

DR. AMIT KUMAR TIKARI
 CONSULTANT RADIOLOGIST

Disclaimer for typing error: This report was created by using an automated process with voice recognition. If you find any discrepancy in this report, please contact the report generating center. It is only the operator not the third party who is responsible for the accuracy of the report. Please contact the report generating center for any discrepancy. Report of your doctor may vary from the above report. Please contact your doctor for any discrepancy.

9422807711 or 9422807712

DIGITAL X RAY | 3DHD SONOGRAPHY
 DIGITAL MAMMOGRAPHY | ENDOSCOPIC ULTRASONOGRAPHY
 CT SCAN | PET SCAN (HIGH QUALITY)

Fibroids

Also called: leiomyomas, uterine myoma

Overview

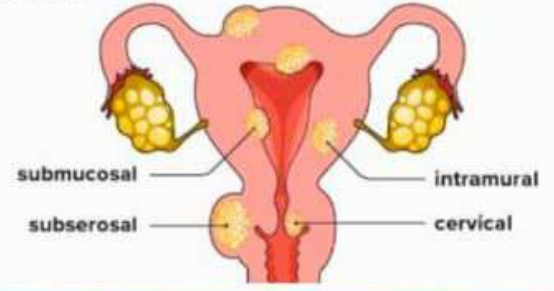
Symptoms

Treatments

Sp

Non-cancerous growths in the uterus that can

Types of fibroids



ADVANCE DIAGNOSTIC CENTRE

(Centre for Color Doppler, Sonography, Digital X-ray & Pathology)

Sreyas Apartment, Near N.I.C. Show Room, Malgudi Chauraha, Tando Stand, 41, Jangampura, INDORR Phone : 2342668, 2348884

PATIENT NAME : MRS NEETA HARDIA PATIENT ID 050923-054
AGE/SEX : 35 Years /Female RECEIVED 05/Sep/2023
REFERRING DR. : DR ARPIT CHOPRA (JAIN) MD REPORTED 05/Sep/2023

WHOLE ABDOMEN SONOGRAPHY

REPORT

Liver appears normal in size, shape, outlines and echotexture. Intrahepatic vascular and biliary pattern appear normal. No focal lesion is seen. Main bile duct and portal vein appear normal.

Gall bladder is well distended and appears normal in size, shape and wall thickness. Lumen is anechoic.

Spleen and Pancreas are normal sonographically.

Both Kidneys are normal in position, size and echostructure. Cortico-medullary differentiations are fair. Bilateral pelvi-calyceal systems and ureters are undilated.

Major abdominal vasculature appear normal. No adenopathy / ascites.

Urinary bladder is well distended and appears normal.

Uterus is anteverted and appears normal in size measuring, shape and echostructure. Endometrium is normal. No myometrial lesion is seen.

Cervix is bulky and reveals a solid, rounded, well marginated echogenic lesion of 5.2 x 3.6 cms arising from the posterior lip.

Both ovaries are normal in size, shape and echotexture. No adnexal abnormality. Pouch of Douglas is empty.

Conclusion : Sonography suggests a solid mass arising from the cervical region. ? Fibroid / ? Nature. Abdominal organ appears normal. FNAC/ Biopsy of cervical lesion is suggested.

DR. R.S. KESWANI
MD, DNB, AFRC (France)
EX-Asst. Radiologist,
Central University Hospital, Cas (France)
Reg. No 7988

DR. R.D. MAHESHWARI
MBBS, DNB, DGO
Ex-Registrar, Bhatnagar Hospital, Bhatnagar
Reg. No 8975

Before Treatment

N

नर्मदा

डायग्नोस्टिक सेंटर

ए. एम. 38, भुलीवाला स्वीट्स के पास,
बापट चौराहा, सुखनिवा, इन्दौर (म.प्र.)
☎ 0731-4939242 ☎ 999816-84242, 76920-56320

☑ सोनोग्राफी 3D-4D ☑ कलर डॉपलर ☑ पैथोलॉजी ☑ IBClinix
Approved

Patient's Name:	MRS. NITA HARDIYA	Age/Sex:	35 Y / F
Ref. by:	Dr. ARPIT CHOPRA IAIN	Date:	14/03/2024

SONOGRAPHY - WHOLE ABDOMEN

Liver: Liver is normal in size (13.2 cms) and echotexture. Intra and extrahepatic biliary radicals are not dilated. Hepatic vein & Portal vein appear normal & undilated. CBD is normal in caliber & undilated.

Gall bladder: GB is contracted.

Spleen: Spleen is normal in size (10.6 cms) and echotexture.

Pancreas: Visualized part of Pancreas is normal in size and echotexture.

Kidneys: Both kidneys are normal in size, shape, outlines & echogenicity. Mid cortical thickness and cortico-medullary differentiation is normal. Pelvi-calyceal system is insulated on both sides. Both ureters are undilated.

Right kidney: 9.5 cms. **Left kidney:** 9.9 cms.

Urinary bladder: UB is normal in shape & contours. Its wall is normal.

Liver: is anteverted and normal in size (11.83 x T 5.8 x AP 4.1 cms), shape and echotexture. Myometrium echotexture is homogenous. Cervix and mid-cervical canal appears normal. Endometrial echoes are normal (ET - 7.3 mm).

Ovary: Right ovary is normal in size, shape and echotexture. There is a 51 x 44 mm sized anechoic cystic lesion in left ovary. So Left ovarian simple cyst.

- TVC and abdominal aorta are normal in caliber.
- No evidence of intrabdominal lymphadenopathy & ascites.
- No evidence of free fluid seen in Pouch of Douglas.

IMPRESSION

- Left ovarian simple cyst.

(ADV - Follow up and clinical correlation suggested.)

Dr. Ashish Kumar
MD, DNB, DGO
Ex-Asst. Radiologist

Complete, Permanent, Easy, Safe, Fast & Cost Effective Cure

आपत चौपड़ा (जैन) माईन होमियोपैथी: महिलाओं सम्बंधित गंभीर बीमारियों का सफल इलाज




DR. ARPIT CHOPRA

ऑपरेशन या सर्जरी के बगैर पाए अपनी समस्याओं का इलाज



कैंसर, किडनी फेलियर, अस्पताल में गंभीर रूप से
भर्ती मरिजों का उपचार, कोमा, शल्य चिकित्सा योग्य रोग,
ऑटो इम्यून रोग, जीवनभर दवाई लेने वाले रोगों की रोकथाम एवं
300 प्रकार के असाध्य जटिल रोगों की चिकित्सा ।

आरोग्य सुपर स्पेशलिटी माईन होमियोपैथी

कम्पलिट, परमानेन्ट, ईजी, सेफ, फास्ट एण्ड कॉस्ट इफैक्टिव

102, प्रथम मंजिल, कृष्णा टॉवर, क्योरवेल हॉस्पिटल के सामने, जंजीरवाला चौराहा, न्यू पलासिया, इन्दौर म.प्र.

☎ 99075 27914 संपर्क : 0731-4977076, 79999 78894



ENDOMETRIUM HYPERTROPHY
 Size: 11.89 MM (8/3/24).
UTERINE FIBROID (MULTIPLE)
 MEASURES 1) 1.3 X 1.3 CM
 2) 1.19 X 1.5 CM
 3) 1.35 X 1.44 CM
CHANGES LATE & PROFUSE
 Date: 12/4/24

रामपुरे नर्सिंग होम
 Patient name: Manisha Age: 47 years
 Referred by: Dr. Arpit Chopra Date: 12/4/24
 Singh Rampure
PELVIC USG
 Urinary bladder is normal thin walled. There is no calculi.
 Uterus is normal in size. Myometrial echotexture is homogeneous.
 length 7.69cm
 width 5.0cm
 Height 5.25cm
 Endometrial thickness 11.89 mm.
 Endometrial echotexture is small hyper echotic shadow seen.
 Both ovaries are normal in size, shape and echotexture.
 Several fibroids seen in fundal aspect of size
 1.3x1.3cm
 1.19x1.5cm
 1.35x1.44cm.
 Dr. Manisha Singh Rampure
 Endometrium hypertrophy.

Classic Ultra Sonography REPORT
 Diagnostic centre
 780, Usha Nagar Extension, Indore
 Dr. Shradh Jain
 Mob. : 9302115770
 PATIENT'S NAME: MRS. MANISHA KUMAR
 CONSULTANT: DR. ARPIT CHOPRA (MD) MBBS
WHOLE ABDOMEN (F) SONOGRAPHY
 Liver is normal in size (13.0 cm) shape and outline.
 Parenchymal echotexture is homogeneous.
 No focal lesion is seen.
 CBD and portal vein are normal in calibre.
 Gall bladder is thin walled. Its lumen is echo free.
 Pancreas is normal in size and echotexture.
 Spleen is normal in size (8.0 cm) and echotexture.
 Both kidneys are normal in size (RT 9.8 cm LT 10.5 cm), shape and position.
 C.M. differentiation is fair.
 No poly-calyceal dilatation.
 Left ureter is dilated in lower part up to its lower end where it is obstructed by a calculus of about 7 mm length casting acoustic shadow.
 No lymphadenopathy. No ascites.
 Urinary bladder is distended. No calculus.
 Uterus is antverted normal in size, shape and position.
 It measures about 8.6 cm in long axis.
 Myometrial echotexture is homogeneous.
 Endometrial echo is normal (5 mm).
 Both ovaries are normal in size and echotexture.
 No adnexal mass or cyst.
 No free fluid is seen in the pouch of Douglas.
CONCLUSION: - A left ureteric calculus at left UVJ with minimally dilated left lower ureter.
 After Dr Arpit Chopra Jain Modern

Fibroids
 Also called: leiomyomas, uterine myoma
 Overview Symptoms Treatments Sp

आरोग्य सुपर स्पेशलिटी मॉडर्न होमियोपैथी
 कम्प्लिट, परमानेंट, ईजी, सेफ, फास्ट एण्ड कॉस्ट इफेक्टिव
 102, ब्रह्म पौड्या, बुध्वा टॉवर, अयोध्या हॉस्पिटल के सामने, जंजीरवाला चौराहा, न्यू पलासिया, इन्दौर म.प्र.
 0791-279714, मोबाई : 0791-4977076, 799997884
 www.aarogyahomeopathyindore.com Email: arpitchochra23@gmail.com

Before Treatment **After Dr Arpit Chopra Jain Modern Homoeopathy**

ऑपरेशन या सर्जरी के बगैर घाए अपनी समस्याओं का इलाज

कैंसर, किडनी फेलियर, अस्पताल में गंभीर रूप से भर्ती मरिजों का उपचार, कोमा, शल्य चिकित्सा योग्य रोग, आंटी इन्फ्यूजन रोग, जीवन्मर दवाई लेने वाले रोगों की रोकथाम एवं 300 प्रकार के असाध्य जटिल रोगों की चिकित्सा।

आरोग्य सुपर स्पेशलिटी मॉडर्न होमियोपैथी
 कम्प्लिट, परमानेंट, ईजी, सेफ, फास्ट एण्ड कॉस्ट इफेक्टिव
 102, ब्रह्म पौड्या, बुध्वा टॉवर, अयोध्या हॉस्पिटल के सामने, जंजीरवाला चौराहा, न्यू पलासिया, इन्दौर म.प्र.
 0791-279714, मोबाई : 0791-4977076, 799997884

300 प्रकार के असाध्य जटिल रोगों का चिकित्सा।

आरोग्य सुपर स्पेशलिटी मॉडर्न होमियोपैथी
 कम्प्लिट, परमानेंट, ईजी, सेफ, फास्ट एण्ड कॉस्ट इफेक्टिव
 102, ब्रह्म पौड्या, बुध्वा टॉवर, अयोध्या हॉस्पिटल के सामने, जंजीरवाला चौराहा, न्यू पलासिया, इन्दौर म.प्र.
 0791-279714, मोबाई : 0791-4977076, 799997884
 www.aarogyahomeopathyindore.com Email: arpitchochra23@gmail.com

UTERINE FIBROIDS

Endometrial hyperplasia occurs when the cells lining the endometrium (the inner lining of the uterus) multiply and become thickened. Endometrial hyperplasia is a pre-cancerous condition. There are two types of hyperplasia, endometrial hyperplasia without atypia and endometrial hyperplasia with atypia.

Before Treatment **After Dr Arpit Chopra Jain Modern Homoeopathy**

UTERINE FIBROID LARGE up to 9 CM

Endometrial Hyperplasia
 Endometrial hyperplasia occurs when the cells lining the endometrium (the inner lining of the uterus) multiply and become thickened. Endometrial hyperplasia is a pre-cancerous condition. There are two types of hyperplasia, endometrial hyperplasia without atypia and endometrial hyperplasia with atypia.

Before Treatment **After Dr Arpit Chopra Jain Modern Homoeopathy**

UTERINE FIBROID LARGE up to 9 CM

आरोग्य सुपर स्पेशलिटी मॉडर्न होमियोपैथी
 कम्प्लिट, परमानेंट, ईजी, सेफ, फास्ट एण्ड कॉस्ट इफेक्टिव
 102, ब्रह्म पौड्या, बुध्वा टॉवर, अयोध्या हॉस्पिटल के सामने, जंजीरवाला चौराहा, न्यू पलासिया, इन्दौर म.प्र.
 0791-279714, मोबाई : 0791-4977076, 799997884

ऑपरेशन या सर्जरी के बगैर घाए अपनी समस्याओं का इलाज

कैंसर, किडनी फेलियर, अस्पताल में गंभीर रूप से भर्ती मरिजों का उपचार, कोमा, शल्य चिकित्सा योग्य रोग, आंटी इन्फ्यूजन रोग, जीवन्मर दवाई लेने वाले रोगों की रोकथाम एवं 300 प्रकार के असाध्य जटिल रोगों की चिकित्सा।

आरोग्य सुपर स्पेशलिटी मॉडर्न होमियोपैथी
 कम्प्लिट, परमानेंट, ईजी, सेफ, फास्ट एण्ड कॉस्ट इफेक्टिव
 102, ब्रह्म पौड्या, बुध्वा टॉवर, अयोध्या हॉस्पिटल के सामने, जंजीरवाला चौराहा, न्यू पलासिया, इन्दौर म.प्र.
 0791-279714, मोबाई : 0791-4977076, 799997884

आरोग्य सुपर स्पेशलिटी मॉडर्न होमियोपैथी
 कम्प्लिट, परमानेंट, ईजी, सेफ, फास्ट एण्ड कॉस्ट इफेक्टिव
 102, ब्रह्म पौड्या, बुध्वा टॉवर, अयोध्या हॉस्पिटल के सामने, जंजीरवाला चौराहा, न्यू पलासिया, इन्दौर म.प्र.
 0791-279714, मोबाई : 0791-4977076, 799997884

ऑपरेशन या सर्जरी के बगैर घाए अपनी समस्याओं का इलाज

कैंसर, किडनी फेलियर, अस्पताल में गंभीर रूप से भर्ती मरिजों का उपचार, कोमा, शल्य चिकित्सा योग्य रोग, आंटी इन्फ्यूजन रोग, जीवन्मर दवाई लेने वाले रोगों की रोकथाम एवं 300 प्रकार के असाध्य जटिल रोगों की चिकित्सा।

आरोग्य सुपर स्पेशलिटी मॉडर्न होमियोपैथी
 कम्प्लिट, परमानेंट, ईजी, सेफ, फास्ट एण्ड कॉस्ट इफेक्टिव
 102, ब्रह्म पौड्या, बुध्वा टॉवर, अयोध्या हॉस्पिटल के सामने, जंजीरवाला चौराहा, न्यू पलासिया, इन्दौर म.प्र.
 0791-279714, मोबाई : 0791-4977076, 799997884

कैंसर * किडनी फेलियर * अस्पताल में गंभीर रूप से भर्ती मरिजों का उपचार * कोमा * शल्य चिकित्सा योग्य रोग * आंटी इन्फ्यूजन रोग * जीवन्मर दवाई लेने वाले रोगों की रोकथाम एवं 300 प्रकार के असाध्य जटिल रोगों की चिकित्सा

आरोग्य सुपर स्पेशलिटी मॉडर्न होमियोपैथिक क्लीनिक
 कम्प्लिट * परमानेंट * ईजी * सेफ * फास्ट एण्ड कॉस्ट इफेक्टिव
 102, ब्रह्म पौड्या, बुध्वा टॉवर, अयोध्या हॉस्पिटल के सामने, जंजीरवाला चौराहा, न्यू पलासिया, इन्दौर म.प्र.
 0791-4977076, मोबाई : 0791-4977076, 799997884, 99075-2333
 www.aarogyahomeopathyindore.com Email: arpitchochra23@gmail.com

ऑपरेशन या सर्जरी के बगैर घाए अपनी समस्याओं का इलाज

कैंसर, किडनी फेलियर, अस्पताल में गंभीर रूप से भर्ती मरिजों का उपचार, कोमा, शल्य चिकित्सा योग्य रोग, आंटी इन्फ्यूजन रोग, जीवन्मर दवाई लेने वाले रोगों की रोकथाम एवं 300 प्रकार के असाध्य जटिल रोगों की चिकित्सा।

आरोग्य सुपर स्पेशलिटी मॉडर्न होमियोपैथी
 कम्प्लिट, परमानेंट, ईजी, सेफ, फास्ट एण्ड कॉस्ट इफेक्टिव
 102, ब्रह्म पौड्या, बुध्वा टॉवर, अयोध्या हॉस्पिटल के सामने, जंजीरवाला चौराहा, न्यू पलासिया, इन्दौर म.प्र.
 0791-279714, मोबाई : 0791-4977076, 799997884

कैंसर, किडनी फेलियर, अस्पताल में गंभीर रूप से
 भर्ती मरिजों का उपचार, कोमा, शल्य चिकित्सा योग्य रोग,
 ऑटो इम्यून रोग, जीवनभर दवाई लेने वाले रोगो की रोकथाम एवं
 300 प्रकार के असाध्य जटिल रोगों की चिकित्सा।



डॉ. अर्पित चौपडा (जैन)
 एम. डी. होम्योपैथी
 जटिल, असाध्य एवं
 शल्य रोग विशेषज्ञ

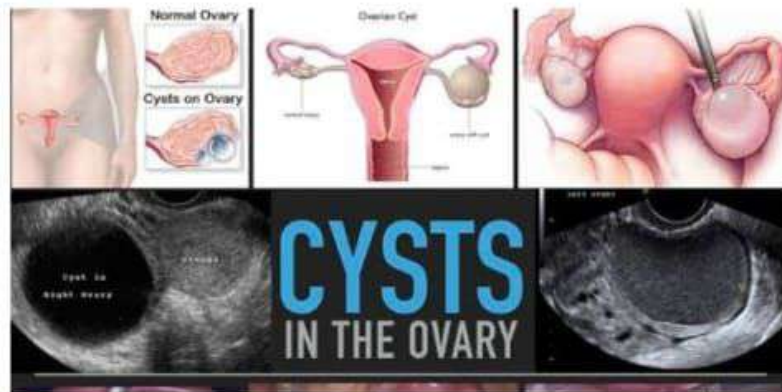
आरोग्य सुपर स्पेशलिटी मॉडर्न होमियोपैथी

कम्पलिट, परमानेन्ट, ईजी, सेफ, फास्ट एण्ड कॉस्ट इफैक्टिव

102, प्रथम मंजिल, कृष्णा टॉवर, क्योरवेल हॉस्पिटल के सामने, जंजीरवाला चौराहा, न्यू पलासिया, इन्दौर म.प्र.

99075 27914 संपर्क : 0731-4977076, 79999 78894

www.homoeopathycure.in, www.aarogyahomoeopathyindore.com Email : arpitchopra23@gmail.com



ऑपरेशन या सर्जरी के
 बगैर पाए अपनी
 समस्याओं का इलाज

DR. ARPIT CHOPRA JAIN

5:45

Dr. Gopal K. Gupta
 M.D. (MBBS)
 Sr. Consultant in Radiology
 & Imaging Services
 (DMC Regn No. 9956)

Ultrasound & X-Ray Clinic
 Colour Doppler Clinic
 E-6A, Hauz Khas Market, New Delhi
 Mobile : 9810272107
 Phones: 26513174 (Clinic)
 35750857 (Residence)

MS EDEN DEBOULLE
 4th May 2024

ULTRASOUND WHOLE ABDOMEN

Ms Eden has normal sized liver, shows homogenous echopattern and there is no focal lesion in the liver.
 (Max AP dia of the Rt lobe of the liver is 13.06 cms)
 Gall bladder is normal, no stones in it.
 CBD is not dilated...
 Pancreas is normal in size and echopattern.

Both the kidneys are normal in size and echopattern,
 There are no stones and no mass lesion in the kidneys.
 (minor faint concretions are shown in the Left kidney)
 There is no calycesis and the ureters are not dilated.
 There is no ureteric stone.

Rt kidney : 9.69*3.11 cms Left kidney : 10.51*4.51 cms

There is no adenopathy and no ascitis.
 Spleen is normal sized.

Ur bladder is well distended, no mass lesion and no stones in it.

Uterus is normal in size and echopattern.
 Endometrial echos are normal, 4.4mm.

Left ovary is normal in size and echopattern, measures 2.88*1.49 cms.
 Rt ovary is enlarged due to the presence of a cyst in it.
 Rt ovary measures 6.75*3.85 cms (cyst size : 5.45*3.18 cms)

There is no pelvic fluid collection.

Before Treatment

CONCLUSION: PRESENCE OF A CYST IN THE RT OVARY. ? PHYSIOLOGICAL.
 SUBTLE CONCRETIONS IN THE LEFT KIDNEY.
 (MAY RE CHECK IN 4 TO 5 WKS)

Gopal K Gupta

Ultrasound facilities include : Colour Doppler & 3D Imaging, Conventional Ultrasound,
 Small Parts examination (like Thyroid, Breast & Scrotum etc.) Transvaginal & Transrectal Examination, Bed Side Examination (Portable)
 X-ray facilities include : all kinds of special/contrast studies & plain X-rays

July 27, 2024

After Dr Arpit
 Chopra Jain Modern
 Homoeopathy

Client name Eden Deboulle
 Date of birth April 15, 1999 25 yrs. old

The both ovaries are normal size. There is no cyst.

No stones are detected by sonography in the left kidney. And there is no hydronephrosis.

Smile Ladies' Clinic
 2-38-7 Kichijojiminamityo, Musashino, Tokyo 180-0003, Japan

Satoru Akutsu, M.D., Ph.D.
 阿久津 聡

PATIENT NAME: Mrs. NAKA TAJAR REG. DATE: 12/09/2018
 DEPARTMENT OF RADIOLOGY
 90017-2008
 1500100004
 RECEIVED BY: DR. ABHIR CHANDRA SAHU
 REPORTED BY: DR. ABHIR CHANDRA SAHU

DIGITAL CEREBRAL MAMMOGRAM AND REPORT LEFT BREAST

Technique:- Mammogram was done & crania caudal medio-lateral & compression views of both breasts were taken. The marker is on lateral & compression views of both breasts were taken.

Observations:-
 Left breasts are symmetrical with dense glandular appearance. No evident spiculated suspicious mass lesion was seen. No architectural distortion was seen. No architectural distortion was seen. Skin & nipple shadows are normal. No axillary LN.

IMPRESSION:- Dense breasts thus mammographic sensitivity speculated mass or suspicious pleomorphic micro calcification (ACR-BIRADS) Negative.

NOTE:- 1) The American College of Radiology (ACR) has established reporting and Database System (BI-RADS) to guide the breast cancer under interpretation of mammograms. This system reserves 11 radiologic 2). Not all breast abnormalities show up on mammography are approximately 10%. If you detect a lump or a lump before your next screening mammogram, consult your doctor immediately. Tissue sampling & Clinical Breast Examinations, 1 vast abnormalities.

Dr. A.Mangal
 DVA/DRNB
 RadioDiagn

PATIENT NAME: Mrs. NAKA TAJAR REG. DATE: 12/09/2018
 DEPARTMENT OF RADIOLOGY
 90017-2008
 1500100004
 RECEIVED BY: DR. ABHIR CHANDRA SAHU
 REPORTED BY: DR. ABHIR CHANDRA SAHU

DIGITAL CEREBRAL MAMMOGRAM AND REPORT RIGHT BREAST

Technique:- Mammogram was done & crania caudal medio-lateral & compression views of both breasts were taken. The marker is on lateral & compression views of both breasts were taken.

Observations:-
 Left breasts are symmetrical with dense glandular appearance. No evident spiculated suspicious mass lesion was seen. No architectural distortion was seen. No architectural distortion was seen. Skin & nipple shadows are normal. No axillary LN.

IMPRESSION:- Dense breasts thus mammographic sensitivity speculated mass or suspicious pleomorphic micro calcification (ACR-BIRADS) Negative.

NOTE:- 1) The American College of Radiology (ACR) has established reporting and Database System (BI-RADS) to guide the breast cancer under interpretation of mammograms. This system reserves 11 radiologic 2). Not all breast abnormalities show up on mammography are approximately 10%. If you detect a lump or a lump before your next screening mammogram, consult your doctor immediately. Tissue sampling & Clinical Breast Examinations, 1 vast abnormalities.

Dr. A.Mangal
 DVA/DRNB
 RadioDiagn

PATIENT NAME: Mrs. CHANDAL BHAVI/2198, PUNE
 DATE: 02/20/21
 DISTRIBUTED BY: DR. PAVIT THAKAR

Dr. Shweta Nagar's Ultrasound Clinic & Imaging Centre
 Dr. Shweta Nagar
 1500100004
 RECEIVED BY: DR. ABHIR CHANDRA SAHU
 REPORTED BY: DR. ABHIR CHANDRA SAHU

HIGH RESOLUTION USG BREAST

Technique:- Both low high frequency transducers of the breast was done using 5-12MHz probe on 7MHz/12MHz presets. Color Doppler advanced system.

Evaluation requested for pain in both breasts.

Observations:-
 There are few fibrocystic changes along perimastoid region of both breasts. Most of the glandular and fatty tissue in both breasts is homogeneously fibroglyc in echotexture. No focal solid nodular lesion. No dilated ducts, skin, perimastoid and retro-mastoid are normal in echotexture bilaterally. There are enlarged axillary lymph nodes, bilaterally with echotexture than largest on right measure 12 x 8 mm, left measure 15 x 5 mm.

IMPRESSION:-
 Focal fibrocystic changes in breast bilaterally.

Normal. Detailed mammography is suggested.

PATIENT NAME: Mrs. CHANDAL BHAVI/2198, PUNE
 DATE: 02/20/21
 DISTRIBUTED BY: DR. PAVIT THAKAR

Dr. Shweta Nagar's Ultrasound Clinic & Imaging Centre
 Dr. Shweta Nagar
 1500100004
 RECEIVED BY: DR. ABHIR CHANDRA SAHU
 REPORTED BY: DR. ABHIR CHANDRA SAHU

Digital Mammography Report

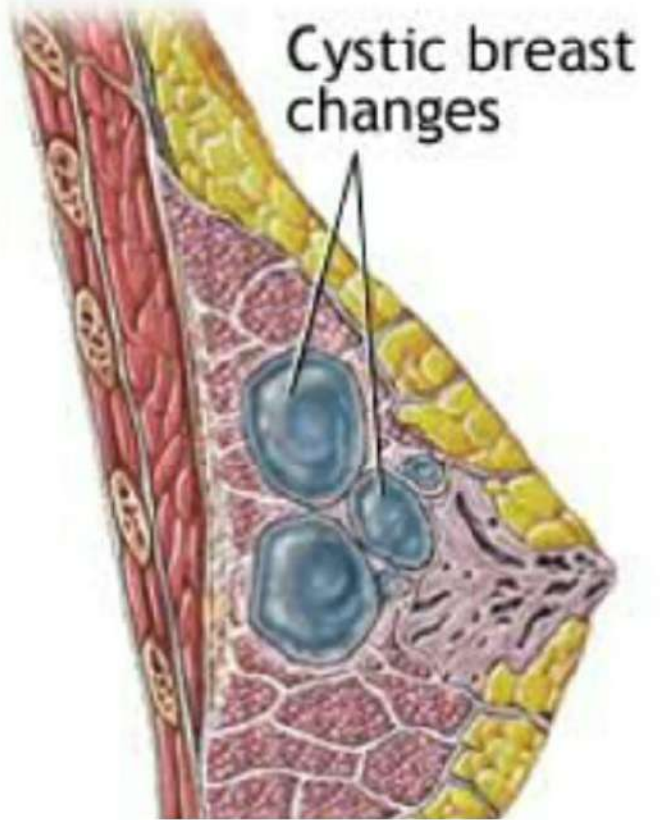
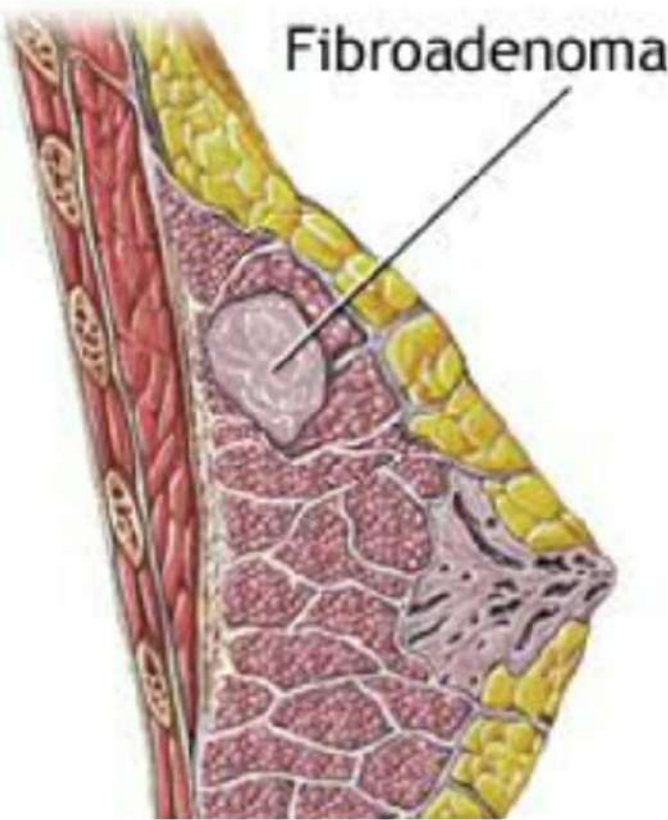
Findings presented with comparison of pain left right breast
 Bilateral low to high mAs (Digital) screen mammography performed with mammogram 45 degree oblique and CC view taken. Adequate compression applied.

Size and shape of both breast is normal identical. Radii-density is of mixed type. axillary fatty & thymohilar con No discernible calcification or any obvious spiculated mass lesions are appears normal. Skin, nipple, axilla and axilla appears free. Vasculature appears normal.

Impression:- No significant mammographic abnormality seen.

Dr. P.S.T
 MID
 RadioDiagn

Common benign causes of breast lumps





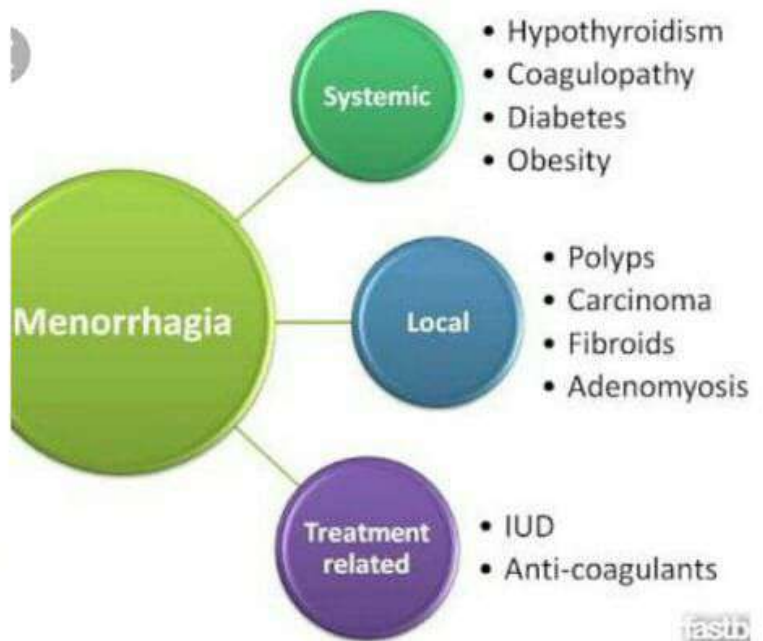
Δ Menorrhagia / metrorrhagia
 (menses problem)
 Pooja choubey
 8103843621
 poojachoubey44@gmail.com
 Suffering from
 Heavy bleeding and
 pain problem in
 monthly period time
 after taken 2 month
 treatment almost
 Relief in problem



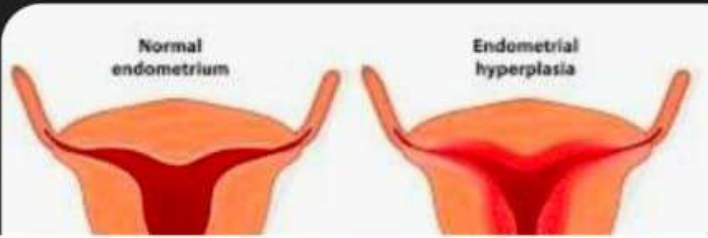Shares Purchased Δ Menses problems

DATE	NO. OF SHARES	NAME OF THE COMPANY	PRICE Rs.	TOTAL PRICE Rs.
		CHHAYA CHOURAY		
		9893909128 ✓		

 Feedback - Completely satisfied.
 c/o - menses cycle irregularity.
 — Dysmenorrhoea
 — Heavy
 Anura (Jain)



Endometrial hyperplasia



Endometrial hyperplasia (EH) is a uterine condition where the endometrium, or the inner lining of the uterus, thickens due to excessive cell production. It's often caused by an estrogen and progesterone imbalance, which can lead to irregular menstrual bleeding and an increased risk of endometrial cancer.

CHHABRA DIAGNOSTIC CENTRE
 For Appointments & Enquiries:
 Ph. : (0731) 4229066
 Mob. : 77239-41121
 Email : chhabradiagnostics@gmail.com
 Web : www.chhabradiagnostics.com

Address : D - 33, HIG, Near Shopping Complex, A.B. Road, Indore - 462010

Timing : Monday to Saturday - 8.00 a.m to 8.00 p.m Sunday & National Holidays - 9.00 a.m to 1.00 pm

Pt Name: **MRS. REENA GIRWAL**
 Ref. By: **DR PRIYANKA JAIN MBBS D.G.O.** Age/Sex: **33 Years /Female**
 Date: **10/Apr/2024**

SONOGRAPHY PELVIC REGION (TVS)

Uterus is retroverted, normal in size, shape & outlines. Myometrial echotexture is smooth & homogenous. **Endometrium is 16 mm thick echogenic.** Two cysts seen in endocervix of about 6 mm & 7 mm size.

Both ovaries are normal in size, shape & echotexture. No dominant follicle is observed. No cyst / mass. No adnexal mass or cyst is seen. No free fluid is observed in pouch of Douglas.

IMPRESSION:
Hyperplastic endometrium. Nabothian cysts endocervix.

Before Treatment

Dr. Harish Chhabra
 M.D. (Radio Diagnosis)
 Diploma in Obstetrical Ultrasonography
 Consultant Radiologist & Sonologist

PC PNOT Reg. No. 452 / NPMG Reg No. 9246 / Clinic Reg. No. 785 - FMP UK 116413

CHHABRA DIAGNOSTICS
 CENTRE FOR : SONOGRAPHY DIGITAL X-RAY PATHOLOGY COLOR DOPPLER ECG

258, Satyadev Nagar, CAT Road, Near Hawa Bungalow, INDORE (M.P.)
 Mob. 78793-81761, 9: 0731-3502099

Pt Name: **REENA GIRWAL** 33Y/F Date: 4/01/2025
 Ref by : - Dr. ARPIT CHOPRA

USG WHOLE ABDOMEN

Liver is normal in size (12.5 cm) and shape. Its echogenicity is normal. Margins are smooth and regular. No focal lesion seen. The portal vein and biliary radicals are normal in calibre.

GB is well distended. Wall thickness is normal. No evidence of calculus or echoes within the lumen. CBD is within normal limits.

Pancreas is normal in size, shape and echo pattern. Spleen is normal in size (9 cm) and echo pattern.

Rt. Kidney: 10.4 x 4.8 cm Lt. Kidney: 10.5 x 5.2 cm

Bilateral kidneys are normal in shape, size and echo texture. Corticomedullary differentiation is maintained. No evidence of any calculus or hydronephrosis. Both ureter undilated and VUJ clear.

Urinary bladder is normally distended with normal wall thickness. Its lumen is free from echoes or calculus.

The Uterus is anteverted & normal in size. Utero cervical length is 8.0 cm. The maximum AP dimensions is 4.1 cm & maximum transverse dimension is 3.7 cm. The uterine contours & margins are smooth. Endometrium is 4-5 mm in thickness. Cervix measures 2.3 cm in maximum AP dimensions. A few small nabothian cysts are seen in cervix. Largest measuring approx. 3.7 x 3.5 mm in anterior lip of cervix.

Both ovaries are normal in shape & size. Right ovary: 3.1 x 2.5 x 2.6 cms. Left ovary: 3.0 x 2.7 x 2.5 cms.

No obvious adnexal lesion noted. No free fluid seen in Pouch of Douglas.

The bowel appear undilated and shows normal peristalsis. No evidence of ascites / significant lymphadenopathy/pleural effusion.

IMPRESSION :

- Anteverted uterus with few small nabothian cysts in cervix.
- No significant abnormality is seen in USG upper abdomen.

After Dr Arpit Chopra Jain Modern Homoeopathy

DR. BHARATI VERMA MD, (Consulting RADIOLOGIST) Regd. No. MP- 7546

Handwritten notes: **Hyperplastic Endometrium**
 Endometrium thickening: **16mm**
 10/4/24

Endometria polyp Uterus

जगद्वि बच्चेदानी की गोंठ के बारे में

DR. BHARATI VERMA MD, (Consulting RADIOLOGIST) Regd. No. MP- 7546

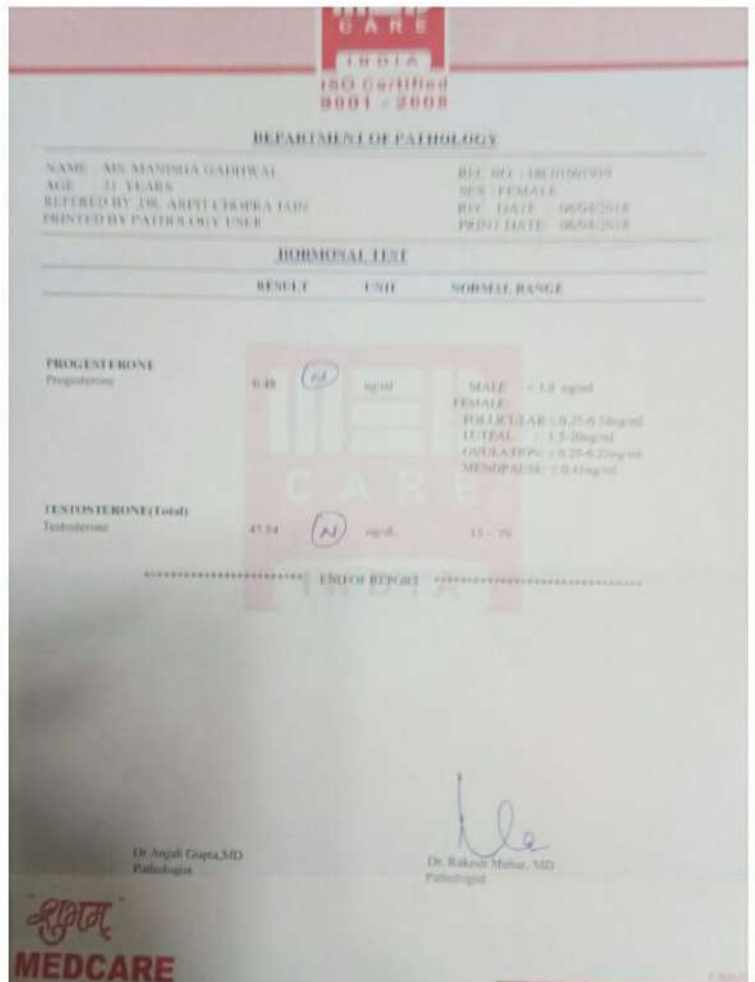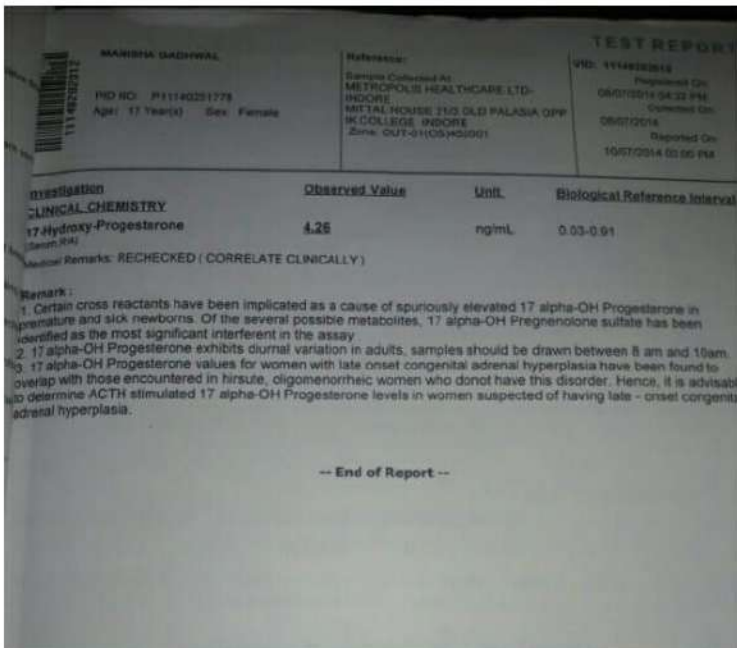
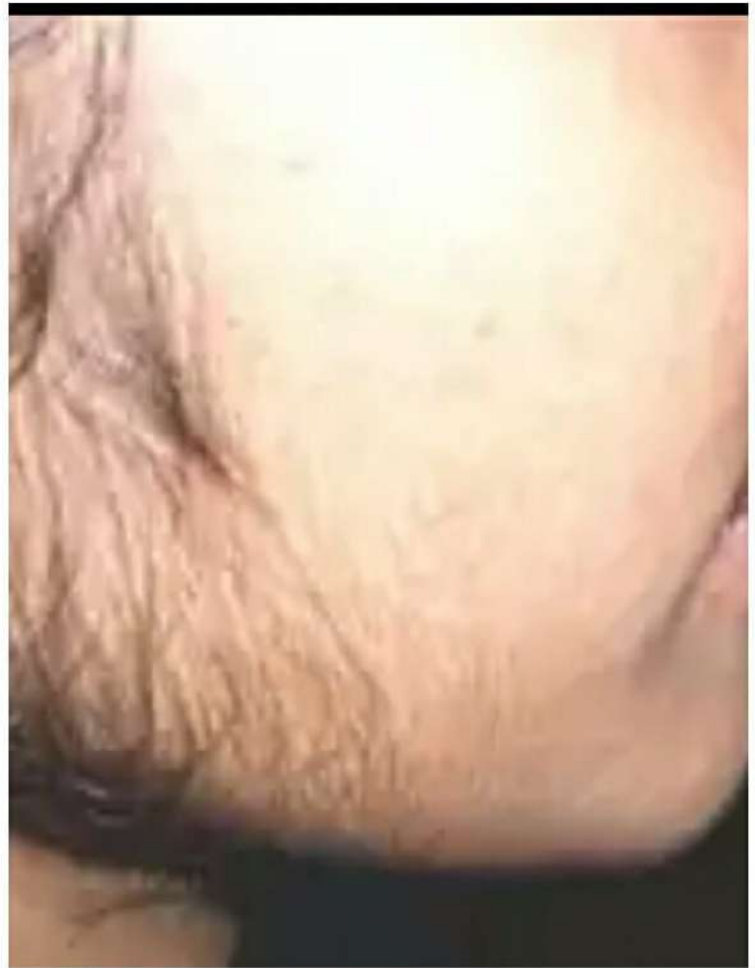
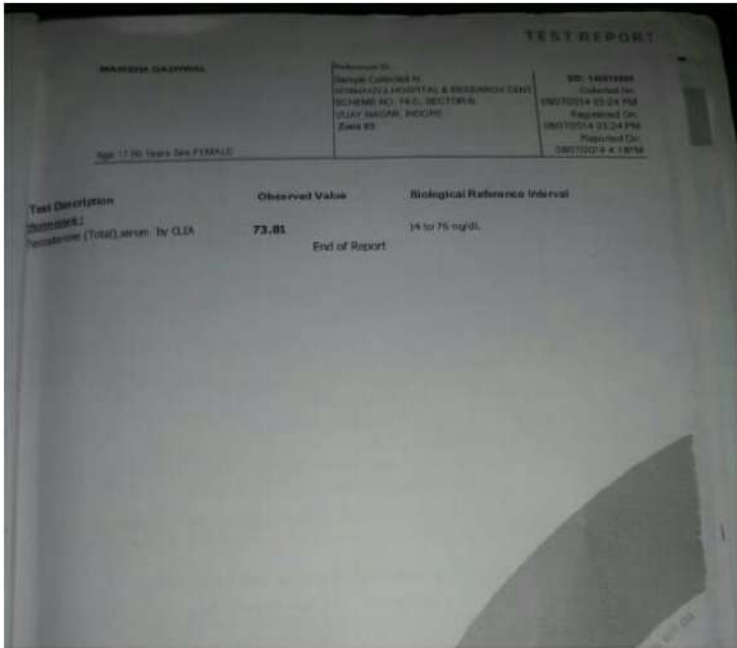
आरोग्य सुपर स्पेशलिटी माडर्न होम्योपैथीक क्लिनिक
AAROGYA SUPER SPECIALITY MODERN HOMOEOPATHIC CLINIC

विषय, किडनी फेलिचर, अल्ट्रासाउंड में गंभीर कण के भ्रू की सर्जिकल या उपचार, कोमा, शल्य चिकित्सा योग्य नॉटिड्यूलन रोग, अल्ट्रासाउंड एनेस्थीसिया, कस्तुरीन डिस्ट्रिब्यूशन, जीवन भर दवा लेने वाले लोगों की चिकित्सा एवं 300 प्रकार के अल्ट्रासाउंड जटिल रोगों की चिकित्सा

0731-4977076 +91 99075-27814, +91 97130-92737, +91 97130-37783, +91 93404-95672, +91 79899-78894 +91 97130-37737, +91 80481-32033

Address: 101, 102, 103, 104, Krishna Tower, Janjalewala Square, in front of Curwen Hospital Road, New Palasia, Indore, Madhya Pradesh 462001
 Email: arpit Chopra 23@gmail.com

DR. ARPIT CHOPRA JAIN
 (MD HOMOEOPATHY) & (M.D. B.S. IN SURGERY)
 SHIKSHA SPECIALIST



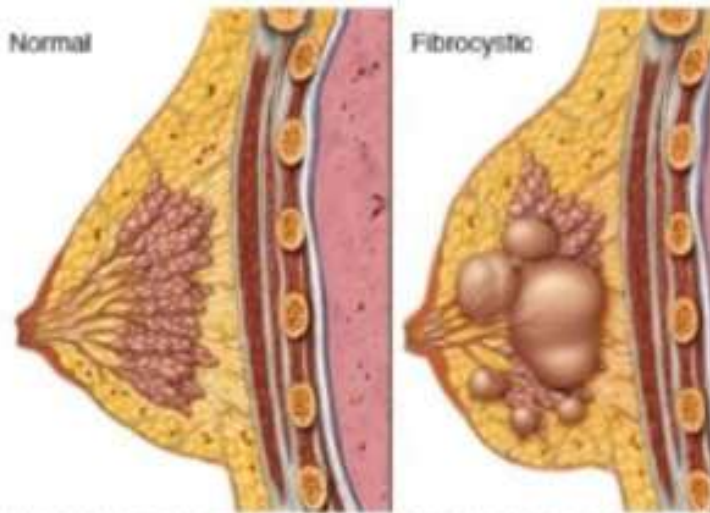
Hirsutism
 Also called: hypertrichosis

ABOUT SYMPTOMS TREATMENTS

Unwanted male-pattern hair growth on a woman's face, chest and back.

Very common
 More than 10 million cases per year (India)

- Treatable by a medical professional
- Usually self-diagnosable



© MAYO FOUNDATION FOR MEDICAL EDUCATION AND RESEARCH. ALL RIGHTS RESERVED.

Fibrocystic breast changes

Fibrocystic breast changes lead to the development of fluid-filled round or oval (cysts) and more prominent scar-like (fibrous) tissue, which can make breasts tender, lumpy or ropy.

Also called: fibrocystic breasts

ABOUT

TREATMENTS

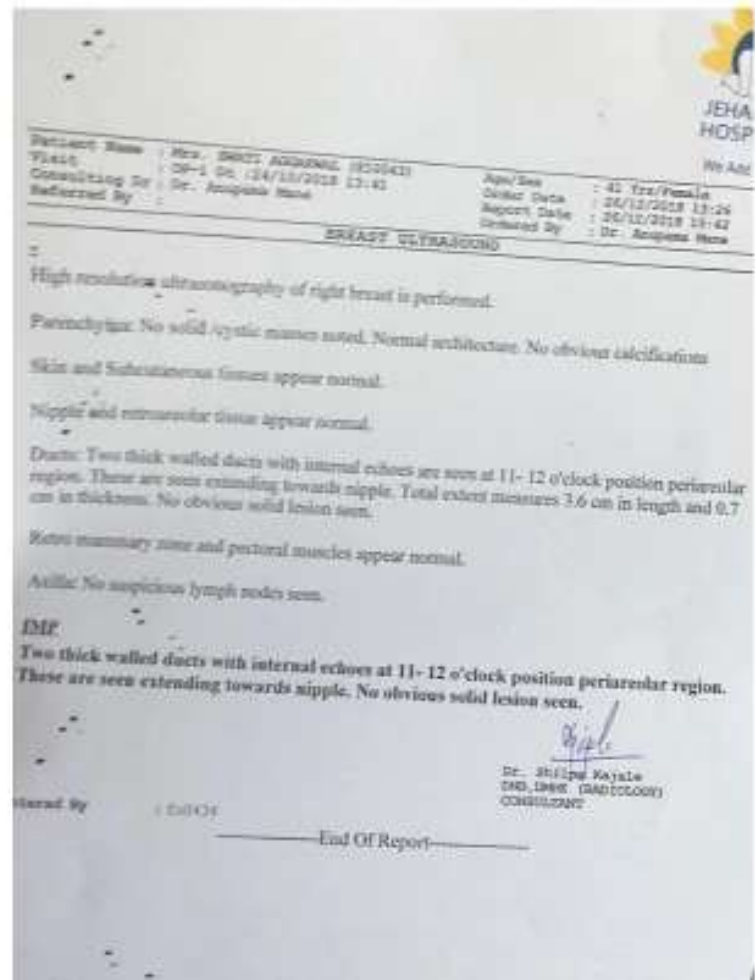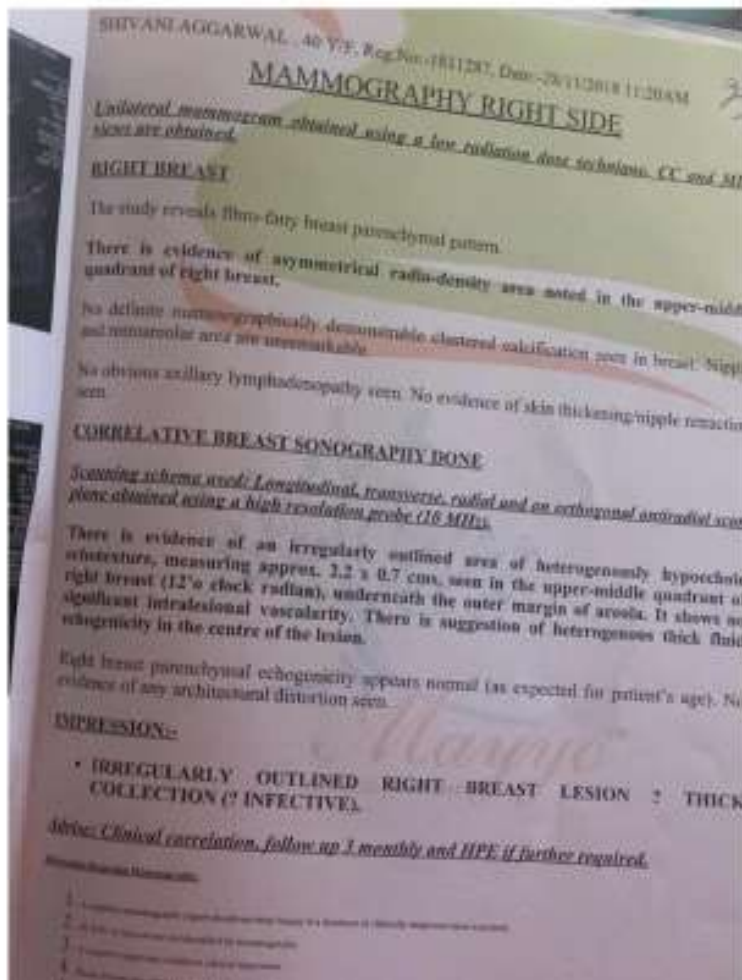
Non-cancerous changes that give a breast a lumpy or rope-like texture.

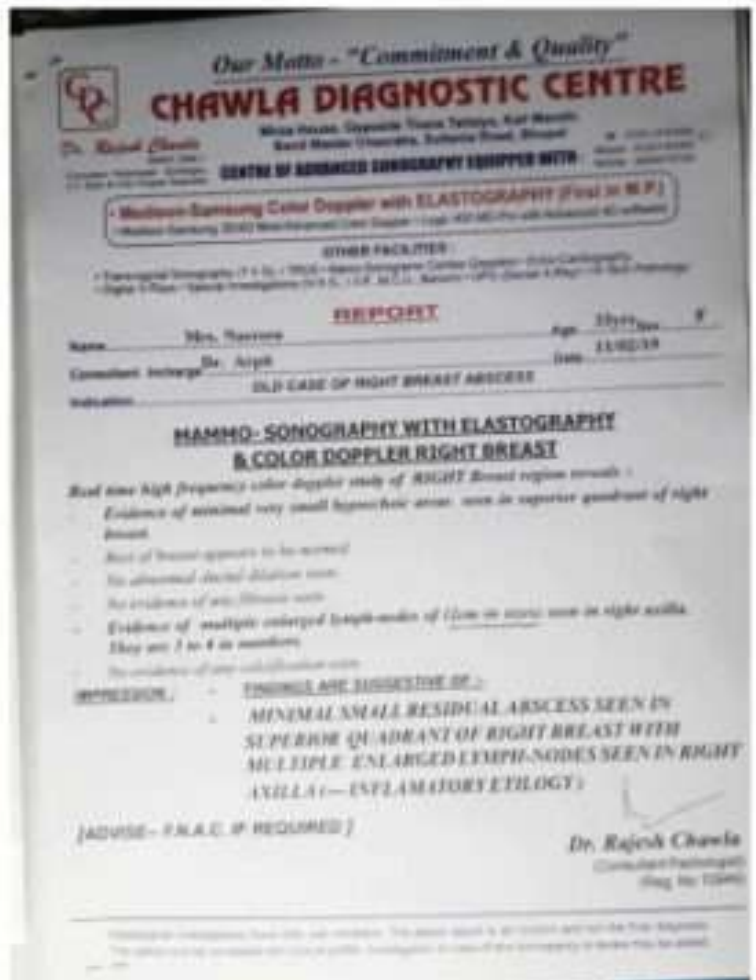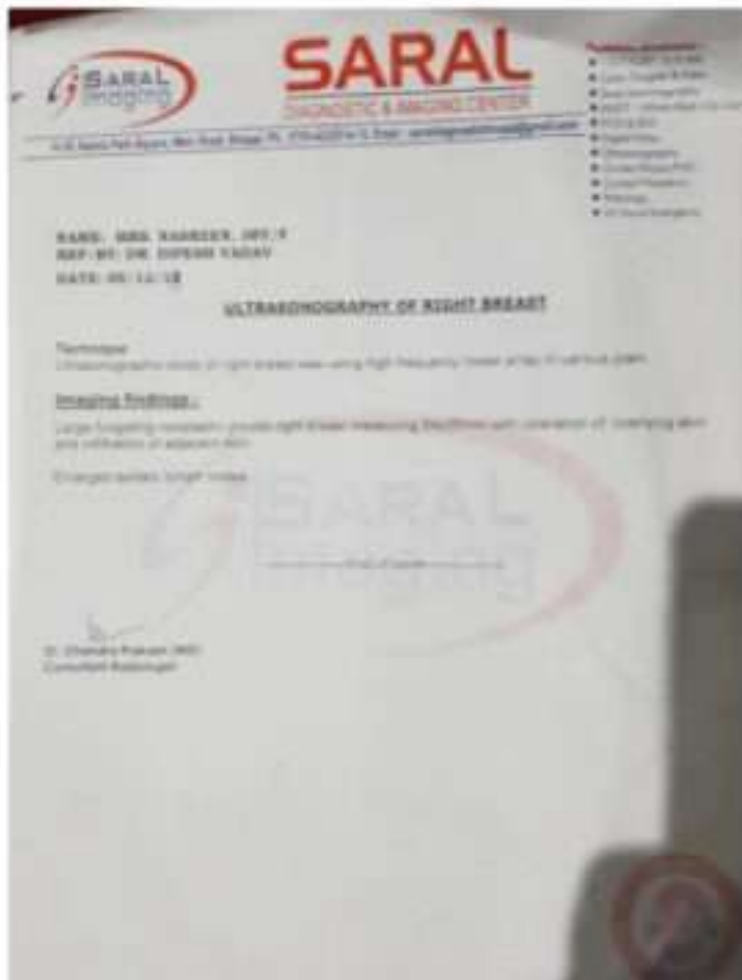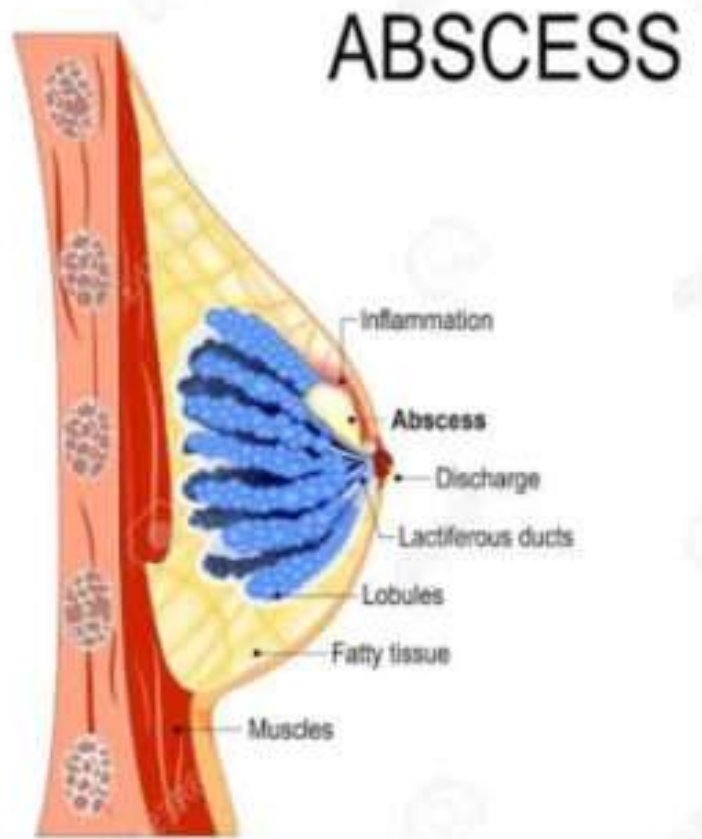
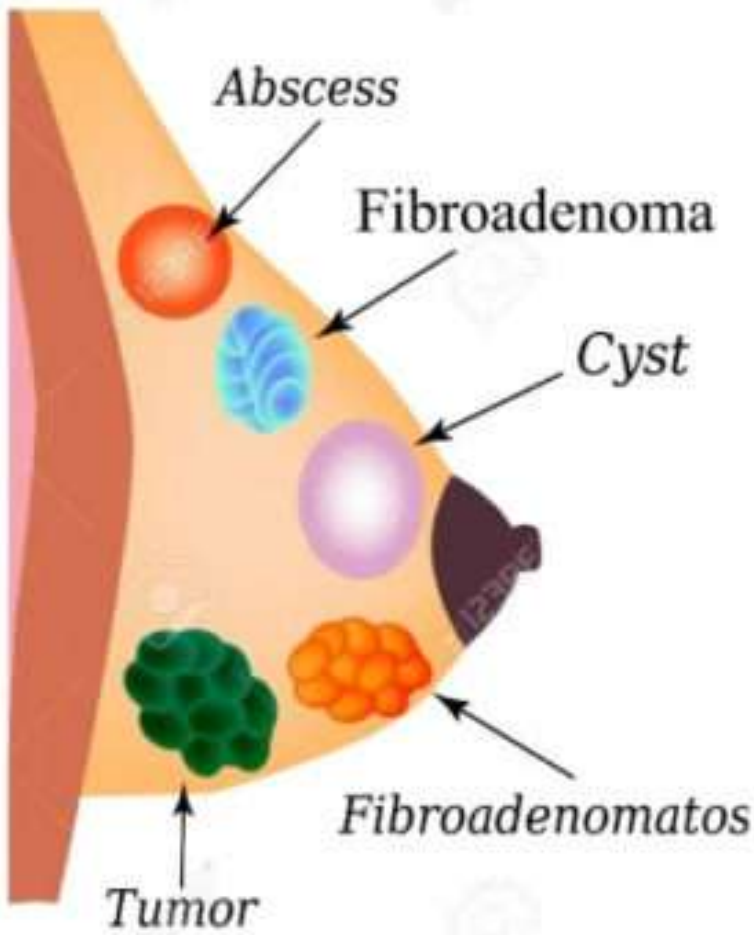
Very common

More than 10 million cases per year (India)

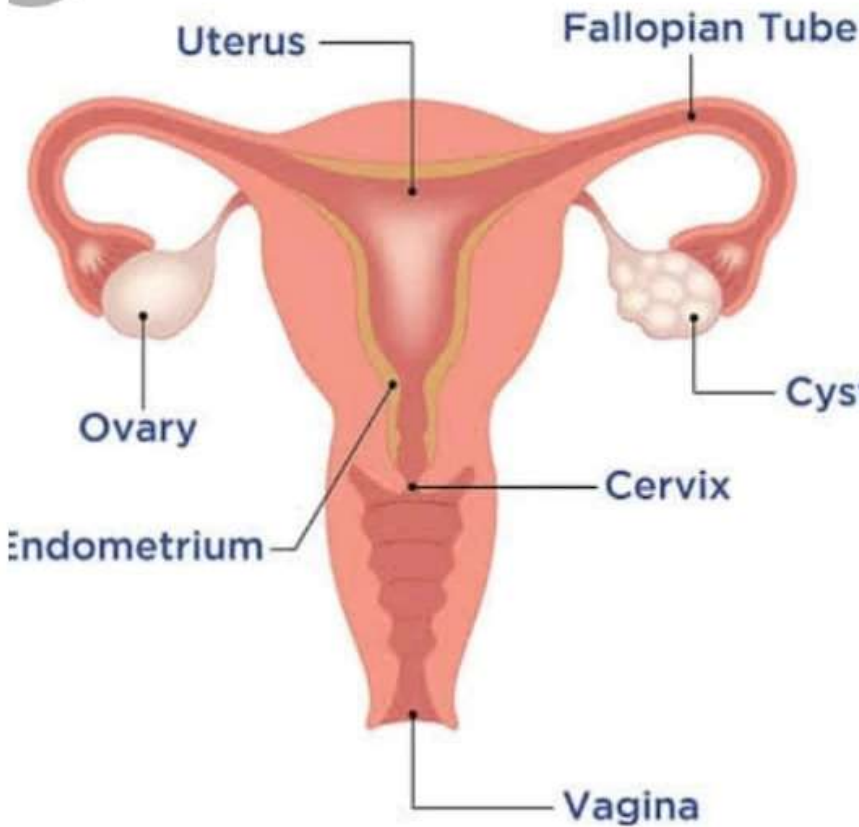


Treatment can help, but this condition can't be cured





TYPES OF OVARIAN CYSTS



-  Corpus Luteum
-  Follicular Cyst
-  Endometrioma
-  Dermoid Cyst
-  Paraovarian Cyst
-  Hemorrhagic Cyst
-  Possibly Malignant

Δ Hemorrhagic Ovarian Cyst

March 2018

Handwritten notes describing a hemorrhagic ovarian cyst, mentioning symptoms like abdominal pain and bloating, and the need for medical attention.

Dr. Arpit Chopra (Jain)

AMROHA SUPER SPECIALITY MODERN HOMOEPATHIC CLINIC

Dr. Arpit Chopra (Jain)

AMROHA SUPER SPECIALITY MODERN HOMOEPATHIC CLINIC

9826026199

Ulcerative Colitis

Handwritten notes in Hindi describing Ulcerative Colitis, its symptoms, and treatment options.

Dr. Arpit Chopra (Jain)

AMROHA SUPER SPECIALITY MODERN HOMOEPATHIC CLINIC

9826026199

Handwritten notes in Hindi describing a case of a hemorrhagic ovarian cyst. The text mentions the patient's symptoms and the doctor's recommendation for surgery.

Dr. Arpit Chopra (Jain)

AMROHA SUPER SPECIALITY MODERN HOMOEPATHIC CLINIC

9826026199

Δ Hemorrhagic Cyst


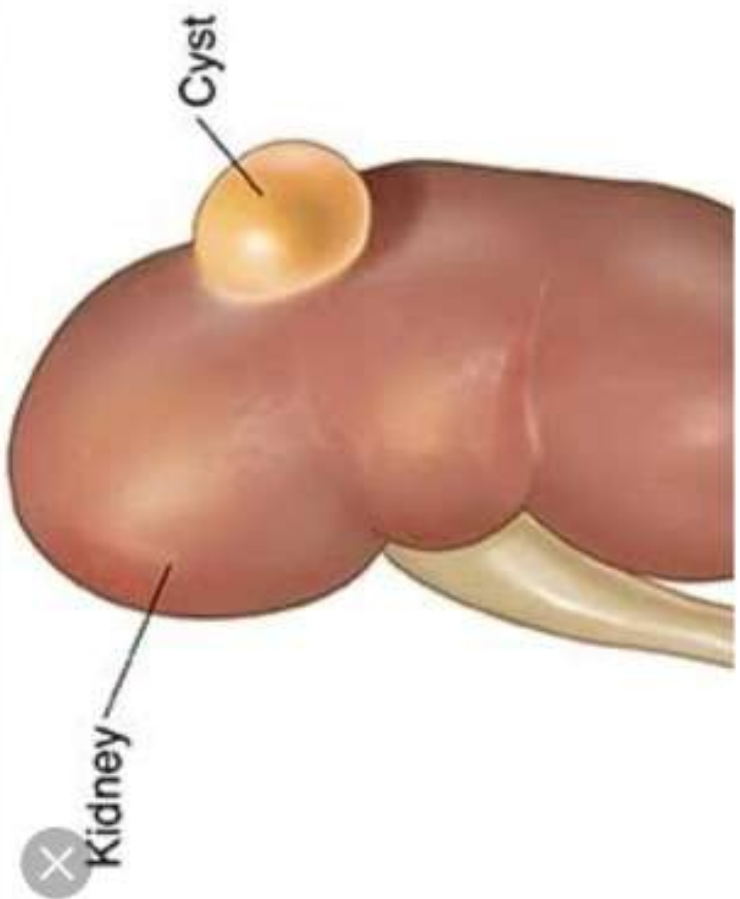

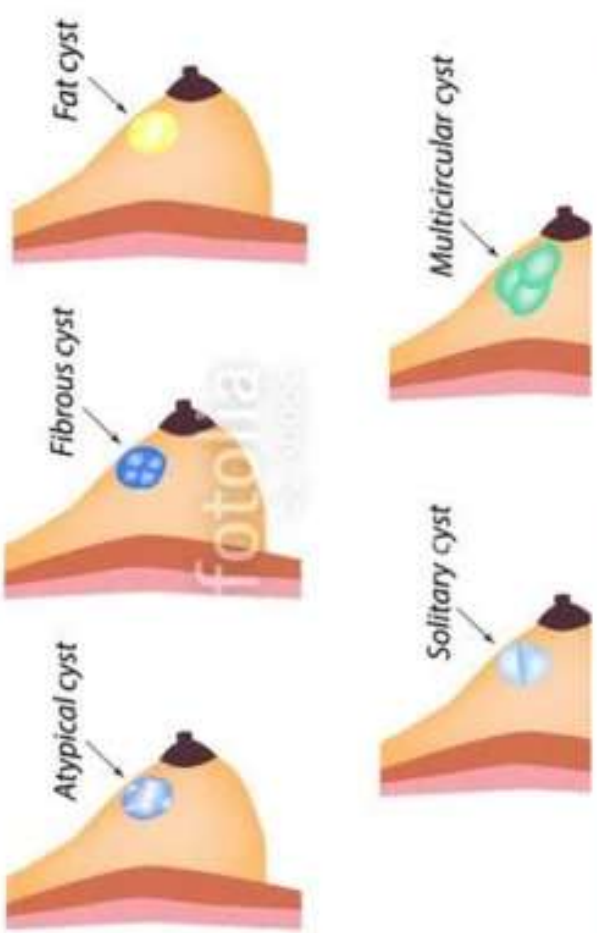
Handwritten notes in Hindi describing a hemorrhagic ovarian cyst, including symptoms and treatment.

Dr. Arpit Chopra (Jain)

AMROHA SUPER SPECIALITY MODERN HOMOEPATHIC CLINIC

9826026199

TYPES OF CYSTS IN THE BREAST



Endometrial polyp

Overview

Symptoms

Treatments

Spec

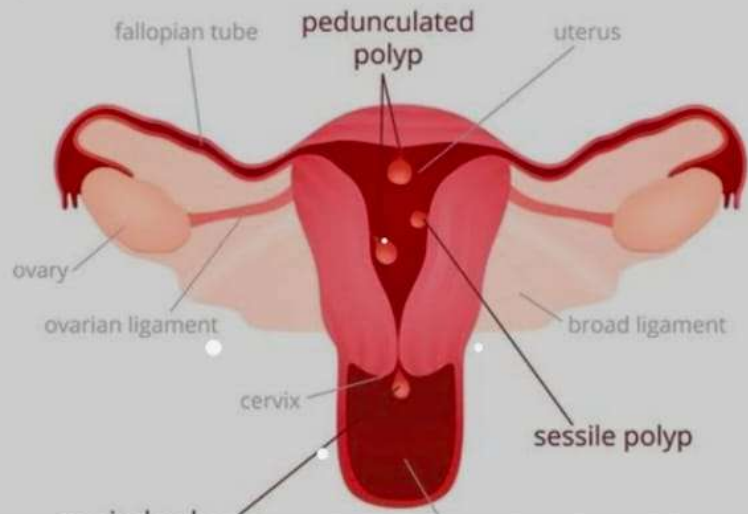
A usually non-cancerous growth attached to the inner wall of the womb (uterus).

Endometrial polyps are common in women who are undergoing or have completed menopause. Polyp size varies.

Common

More than 1 million cases per year (India)

UTERINE POLYPS (endometrial Polyps)



Sanya DIAGNOSTICS

Pt. Name: MRS. SANGEETA DIXIT
Ref. By: DR. ARPIT JAIN
Age/Sex: 53 Years / Female
Date: 29/06/2024

USG PELVIS (TVS)

Imaging findings:

- Uterus is anteverted and ante-flexed and normal in size. It measures ~ 7.0 X 4.4 X 4.1 cm in size.
- The myometrial echogenicity is normal. No focal myometrial lesion is seen. The endometrial lining is measures ~ 4.7 mm in thickness. Mild intra-cavitary fluid is noted with echogenic lesion ~ 10 x 7 mm with a vascular pedicle.
- Bilateral adnexa are clear.
- No free fluid is seen in the pelvic cavity.

Impression: USG pelvis (TVS) shows -

- Mild fluid in endometrial cavity with echogenic lesion showing a vascular pedicle - Polyp.
- Rest no other significant abnormality seen.

Please correlate clinically.

Dr. Laxman Prasad, MD, DNB Sr. Consultant Radiologist
Dr. Suryakant Singh, DNB Consultant Radiologist
Dr. Arunima Suresh, MD, DNB Consultant Radiologist

Before Treatment

कृति डायग्नोस्टिक सेंटर

Dr. Samta Johri
M.B.B.S., D.M.R.D. (Radiologist)
Reg. No.: 11344

Name of Patient - MRS SANGEETA DIXIT
Age - 53 Y.F.
Refd. By - DR ARPITA CHOPRA
Date - 12 / 8 / 2024

ULTRASONOGRAPHY OF PELVIS (TVS)

REPORT

Done with 5.5 MHZ probe. It reveals -

- Uterus is mild bulky in size with endometrium 7.6 mm. Myometrium normal.
- Both ovaries are normal in size. Very small follicles seen in them.
- No collection seen in posterior cul de sac.

IMPRESSION - USG FINDINGS SUGGESTIVE OF ENDOMETRIUM 7.6 MM.

After Dr Arpit Chopra Jain Modern Homoeopathy

DR. SAMTA JOHRI
M.B.B.S., D.M.R.D.
Reg. No. 11344

ENDOMETRIUM HYPERTROPHIC
Size: 11.89 MM (11/8/24)

UTERINE FIBROIDS (MULTIPLE)

- 1) 1.3 X 1.3 CM
- 2) 1.19 X 1.5 CM
- 3) 1.35 X 1.44 CM

NOBES LATE & PROFUSE

P: 18/4/24
ANOMALIA

Before Treatment

Classico Diagnostic Centre REPORT

After Dr Arpit Chopra Jain Modern Homoeopathy

आरोग्य
COMPLETELY SAFE, FAST & COST EFFECTIVE

* कैंसर * किडनी फेलियर * अस्पताल में गंभीर रूप से मर्ती गरिजों का उपचार * कोमा * शल्य चिकित्सा योग्य रोग * आँटो इन्चूब रोग * जीवनमर दवाई लेने वाले रोगों की रोकथाम एवं 300 प्रकार के असाध्य जटिल रोगों की चिकित्सा

आरोग्य सुपर स्पेशलिटी मॉडर्न होम्योपैथिक क्लीनिक

कम्पलिट * परमानेंट * ईजी * सेफ * फास्ट एण्ड कॉस्ट इफैक्टिव

102, प्रथम मंजिल, कृष्णा टॉवर, क्वोरवेल हॉस्पिटल के सामने, वजीरवाला चौराहा, न्यू प्लासिवा, इन्दौर (म.प्र.)
फोन : 0731-4977076, मो: 97130-92737, 97130-37737, 79999-78894, 99075-27914

www.homoeopathy.cure.in, www.aarogyahomoeopathyindore.com Email: arpit Chopra 23@gmail.com

Bansal Diagnostic Centre

Dr. Krati Bansal
(M.D., D.R.)
 Radiodiagnosis Mumbai (Gold Medalist)
 Regd. No. MP 9302
 More than 12 Years of Experience in Radiology

Pt. Name	MRS. SAJEDA BEE	Age/Sex	52 Years / Female
Ref. By	DR. ARPIT CHOPRA JAIN	Date	07/Sep/2022

WHOLE ABDOMEN SONOGRAPHY

Liver is mildly increased in size measuring approximately 17 cm and reveals mild generalized increase in parenchymal echogenicity. Portal & hepatic venous system appear normal. No focal lesion is seen. Intra & Extra hepatic biliary radicles are not dilated.

Gall bladder is not visualized postoperative status.

Portal vein and CBD are normal in caliber.

Pancreas is normal in size, outline and echo-pattern.

Spleen is normal in size and measures approximately 9.3 cm with normal echo-pattern.

Both kidneys are normal size, shape & echogenicity with smooth outline. Central pelvicalyceal sinus and corticomedullary ratio are normal on both sides.

Renal size:- Right -> 9.7 x 4.2 cms
 Left -> 10.5 x 4.7 cms

Both ureters are undilated and not visualized.

Urinary bladder is normal in size, shape & echotexture. Its wall is normal. Prevoid volume is 250 cc. Postvoid residual is insignificant.

Uterus is anteverted and mildly bulky size and measures approximately 10.1 x 6.0 x 5.4 cm vol 173.0 cc with normal shape with smooth outline. Uterine myometrium appears heterogeneous with presence of approximately 1.6 x 1.7 and 2.0 x 1.8 cm size focal hypoechoic area with posterior uterine myometrium-intramural uterine fibroids. Myometrial and central endometrial echoes are normal. Endometrial thickness is 17 millimeter, appears thickened and echogenic with few cystic spaces within.

Left -> 2.0 x 1.8 cms.

Ovarian size:- Right -> 1.7 x 1.6 cms
 Both ovaries are normal in size, shape & echogenicity. No dominant follicle is observed.

No adnexal mass or cyst is seen.

No free fluid is observed in pouch of Douglas.

Before Dr Arpit Chopra Modern Homoeopathy treatment

Digital X-Ray • Pathology • Sonography • Target Scan • Colour Doppler • EMG • NCV • ECG • EEG • PPT • Allergy Test

314, Zodiaq Mall, Opp. Agrawal Public School, Pipiyahana, INDORE - 452 010 (M.P.)
 For Appointment & Reports ☎: 9302297440
 Note: This report is not valid for read on legal purposes.

SODANI DIAGNOSTIC CLINIC
(A Unit of Sodani Hospitals & Diagnostics Pvt. Ltd.)
 H/O: L.G-1, Morya Centre, Opp. Basket Ball Club, 181, Race Course Road, Indore (M. P.)
 Phone: 0731-4765222, 0731-7770190

IND: 99012015

Patient Name	Mrs. SAJEDA BEE	Sample ID	SI02210474
DOB/Age/Sex	52 years/Female	Organization	DIHCT
Mobile	9289536755	Reported On	Feb 15, 2023, 11:37 a.m.
Referred By	Dr. Chopra Arpit Jain (MD) (Homeo)	Collected On	Feb 15, 2023, 04:16 p.m.
		Approved On	Feb 15, 2023, 04:24 p.m.

SONOGRAPHY

WHOLE ABDOMEN SONOGRAPHY

Hepatic contour is smooth & spin is normal. Parenchymal echoes are high. No focal lesion is seen. Intrahepatic biliary radicles are undilated. Complimentary elastography done.

Gall bladder is not seen (No operation).

Portal vein & CBD are normal in caliber.

Pancreas is normal in shape & size. Parenchymal echoes are normal. Duct is undilated.

Spleen is normal (9.9 cm). No focal lesion seen.

Both kidneys are normal in position & size. Right kidney is 10.0 x 4.5 cm & left is 11.0 x 4.0 cm in size. Cortical echoes are normal. Pelvicalyceal system is undilated. Both ureters are undilated. No calculi seen at PUJ & UVJ.

Urinary bladder shows normal walls & echofree lumen. No intra luminal lesion or calculi seen.

Uterus is anteverted. It measures 9.5 x 5.7 x 5.2 cm. No focal myometrial lesion seen.

Cervix is normal in thickness. Endometrium is 6 mm in thickness.

Both ovaries are normal in size. Stroma is normal. No cyst seen.

No free fluid seen in cul-de-sac. No significant Ascites. No pleural effusion.

No significant bowel wall thickening / dilatation or lymphadenes are noted.

After Dr Arpit Chopra Modern Homoeopathy treatment

[Impression]:

- Grade I fatty changes in liver
- Normal renal echotexture with undilated collecting system
- Clinical correlation / followup suggested

Asst. Dr.
DR. SADHNA SODANI
 MBBS (Reg. No. 8926)

DR. R.K. SODANI
 MBBS (D.M.D) (Reg. No. 5765)

e-mail: sodani@sodanidiagnostics.com, www.sodanidiagnostics.com

Indore • Ujjain • Dewas • Sanwer • Khairwah • Khargone • Bakhari • Dhan • Mhow • Shajapur

त्री-रोग-चिकित्सा
GYNAECOLOGY
GYNAECOLOGICAL DISORDERS

HEAVY MENSTRUAL BLEEDING
 6
 5
 1
 2
 VAGINAL INFECTIONS
 PMS

आरोग्य सुपरस्पेशलिटी मॉडर्न होम्योपैथी
 AAROGYA SUPERSPECIALITY MODERN HOMOEOPATHY

आरोग्य सुपरस्पेशलिटी मॉडर्न होम्योपैथी
 आरोग्य सुपरस्पेशलिटी मॉडर्न होम्योपैथी
 आरोग्य सुपरस्पेशलिटी मॉडर्न होम्योपैथी





आरोग्य सुपर स्पेशलिटी मॉडर्न होम्योपैथीक क्लिनिक™

AAROGYA SUPER SPECIALITY MODERN HOMOEOPATHIC CLINIC™

हमारी कोई अन्य शाखा नहीं है
प्रौढ कॉल से सावधान रहें

कैंसर, किडनी फेलियर, अस्पताल में गंभीर रूप से भर्ती मरीज का उपचार, कोमा, शल्य चिकित्सा योग्य ऑटोइम्यून रोग, अल्जाइमिक
दैनिकिया, मस्कुलर डिस्ट्रोफी, जीवन भर दवा लेने वाले रोगीक रोकथाम एवं 300 प्रकार के असाध्य जटिल रोगों की चिकित्सा

Online Consultation Available
☎ 0731-4977076 📞 +91 99075-27914, +91 97130-92737, +91 97130-37737, +91 93404-95872, +91 79999-78894 📞 +91 97130-37737, +91 80451-32033




DR. ARPIT CHOPRA JAIN
(MD HOMOEOPATHY & CRITICAL & SURGICAL DISEASE SPECIALIST)

www.homoeopathycurer.in
www.aarogyahomoeopathyindore.com
www.besthomoeopathydoctorind.com

Address: 101, 102, 103, 104, Krishna Tower, Janjeerwala Square, in front of
Curewell Hospital Road, New Palasia, Indore, Madhya Pradesh 452001

Email: arpitchopra23@gmail.com



Reg. No. NH/5007/Apr-2022

SANJEEVANI HOSPITAL, ALOT

📍 Near Bus Stand, ALOT (M.P.) Ph.: 07410 - 230221 • (M) 90745 - 84125

PT NAME	MRS. SANA BEE	AGE/SEX/	23 YEARS / FEMALE
REF BY	SELF	DATE	26/10/2024

ULTRASOUND WHOLE ABDOMEN

Liver is normal in size normal in shape with bright echotexture with posterior aquastic attenuation. Portal & hepatic venous system appear normal. No focal lesion is seen. Intra and extra hepatic biliary radicles are not dilated.

Gall bladder is contracted in size & normal shape. Its lumen is filled with multiple echogenic lesions collectively measure 1.01 cm emitting clear cut posterior acoustic shadow. Portal vein and CBD are normal in caliber.

Pancreas is normal in size outline & echo pattern.

Spleen is normal in size and echo pattern.

Right kidney is normal in size, shape and echogenicity with smooth outline. Central pelvicalyceal sinus and corticomedullary ratio are normal. No calculus.

Left kidney is normal in size, shape and echogenicity with smooth outline. Central pelvicalyceal sinus and corticomedullary ratio are normal. No calculus.

Urinary bladder is normal in shape & contour. Its wall is normal.

Uterus is anteverted, appears normal in size (measures 8.46x4.55x4.50 cm) and shape. Myometrial echotexture appears normal. No focal lesion seen. Cervix appears normal. Endometrium measures - 9.0 mm.

Left ovary is normal in size, shape & echotexture.

Right ovary - medium size non septet thin wall 6.22x3.74 cm ovarian cyst.


No free fluid is seen in Pouch of Douglas, No evidence of intra abdominal lymphadenopathy. No evidence of ascites is seen.

IMPRESSION: -----

- CHOLELITHESIS (MULTIPLE GALL STONE).
- RIGHT SIDE OVARIAN CYST.
- GENERALISED FATTY INFILTRATION OF LIVER OF GRONE.

Sonography is an interpretation drawn from images. It is not a final diagnosis in case of any discrepancy please repeat / or evaluate by MRI/CT/Clinical examination.

DR. N.P. AGRAWAL
M.B.B.S. (D) RADIOLOGIST
SONOLOGIST



AL-HAYAT DIAGNOSTICS

TREATMENT WITHIN YOUR REACH

NAME	MRS. SANA AGWAN	AGE/SEX:- 23/F
REFERRED BY	DR. ARPIT CHOPRA MD	
DATE :-	15/02/2025	

USG WHOLE ABDOMEN(F)

Liver is normal in size 12.4 cm with smooth contour echotexture mildly raised. Intra hepatic biliary radicals are not dilated. Portal & splenic veins are normal in caliber.

Approx 7.9 mm size calculus seen in the gall bladder lumen.

Gall bladder is normal in size with thin walls. CHD & CBD are not dilated.

Pancreas is normal shaped with homogenous echotexture. Spleen is normal in size 11.1 cm and echotexture.

Kidneys are normal in size (Rt 10.6 X 4.5 Lt. 10.5 X 5.1 cms), contour, position and show normal cortical echogenicity & CMJ. No evidence of calculus or calcification on either sides. Pelvicalyceal systems & ureters are undilated. No abdominal/ pelvic lymphadenopathy is seen.

Urinary bladder is adequately filled with anechoic contents. Mucosa is smooth and wall thickness measures normal.

Uterus is normal in size, contour & antverted. Myometrium is homogenous in echostructure. Endometrial echo is central. Cervix appears to be normal. Uterus Size 8.2 x 3.7 x 5.6 cm. Endometrium is 8.5 mm.

Bilateral ovaries are enlarged size and volume, multiple small follicle seen at peripheral site of both ovaries.

No dominant follicle seen in either ovary.

Right ovary: 4.2 x 2.3 x 2.4 cm (vol 12.7 cc)

Left ovary: 4.0 x 2.1 x 2.9 cm (vol. 13.4 cc)

IMPRESSION: POLYCYSTIC OVARIES, GALL BLADDER CALCULUS, MILD FATTY LIVER.

During Dr Arpit Chopra Jain Modern Homoeopathy

DR. VIJAY BHURIYA
M.B.B.S (D) RADIOLOGIST

PATHOLOGY | DIGITAL X-RAY | SONOGRAPHY

Note: Please Correlate reports with clinical findings & other investigations

☎ Lab: 0731-259343, 93011 7492
☎ Hospital: +91 70696 00681
✉ alhayat.pat@albe@gmail.com
Lab Timing: 8:00 AM to 3:00 PM
Sunday 9:00 AM to 2:00 PM

डॉ. अरपित चोपड़ा (डीन) मॉडर्न होम्योपैथीक स्पेशलिटी मॉडर्न होम्योपैथीक क्लिनिक का सफल इलाज



आरोग्य सुपर स्पेशलिटी मॉडर्न होम्योपैथीक क्लिनिक

डॉ. अरपित चोपड़ा (डीन) मॉडर्न होम्योपैथीक स्पेशलिटी मॉडर्न होम्योपैथीक क्लिनिक का सफल इलाज



आरोग्य सुपर स्पेशलिटी मॉडर्न होम्योपैथीक क्लिनिक

स्त्री-रोग-चिकित्सा

आरोग्य सुपर स्पेशलिटी मॉडर्न होम्योपैथीक क्लिनिक



DR. ARPIT CHOPRA JAIN

महिलाओं से सम्बंधित गंभीर बीमारियों का सफल इलाज



DR. ARPIT CHOPRA JAIN

3:03

ALL TYPES OF GYNAECOLOGICAL DISORDERS CURED BY DR ARPIT CHOPRA JAIN'S MODERN HOMOEOPATHY

FEMALE GYNAECOLOGY DISEASE महिलाओं स्त्री रोग संबंधी CURED BY DR ARPIT CHOPRA ...

PATIENT NAME :Mrs. MAYA TANK
:FEMALE REG NO. :16005316
:16C01006727
REFERRED BY :Dr. ARPIT CHOPRA JAIN

AGE :40 Y 0 M 0 D

SEX
REC NO.

REC. DATE :05/08/2016

Before Treatment

Follow up case of left breast collection. Previous details not available.

- Left breast low kV high MAS CR (Digital) X-Ray mammography performed.
- Both Medio - lateral 45 - degree oblique and CC views taken. Compression applied.
- Size and shape of left breast is normal.
- Radio-density is mixed type normal for her age.
- Illdefined radio density noted in the inner lower quadrant with no abnormal calcification.
- Skin, Nipple - areola and axilla free. Vasculature is normal.
- Complimentary screening USG reveals a well-defined thick walled irregular collection of size approx 4 x 2.2 cms suggesting benign fluid collection.

IMPRESSION :- X-Ray Mammographic appearance & complimentary USG screening of left breast in concern falls in BI-RADS Assessment Category 2 (Fluid collection). Most category 2 breast are benign & have 2/10000 chances of cancer. Continue annual screening mammography.

PATIENT NAME :Mrs. MAYA TANK
:FEMALE REG NO. :16004126
:16C01009028
REFERRED BY :Dr. ARPIT CHOPRA JAIN

AGE :40 Y 0 M 0 D

SEX
REC NO.

REC. DATE :18/10/2016

After Treatment

IMPRESSION:- Dense breasts thus mammographic sensitivity is poor, however no evident spiculated mass or suspicious pleomorphic micro calcification seen. Category 1 (ACR-BIRADS) Negative.

- SONOGRAPHY • E.C.G.
- COLOUR DOPPLER
- PATHOLOGY • B.M.D.
- DIGITAL X-RAY & O.P.G.

UNIQUE
DIAGNOSTIC CENTRE

45-B, Jaora Compound,
Opp. M.Y. Hospital,
Indore - 452 001 (M.P.)
Ph. : 2704118, 4082228

MRS. PRIYA JAIN.

40 Yrs./F.

DR.(MRS.) K.BHAGWAT. M.S.,FICS.
DR.NEETA NATU. M.S.

20th Oct, 2015

PELVIC SONOGRAPHY

Uterus is mildly enlarged in size, bulky [measures 10 x 8 x 6 cms. in diam.] and is globular in shape. The uterine outlines are smooth & regular. There is diffuse thickening of the myometrium seen with heterogenous echostructure - Adenomyosis, with the possibility of a small 2.1 cms. intramural fibroid at posterior myometrium in upper body region. Endometrial echoes are central and 4 mms. in thickness.

Both ovaries are normal in size, shape and echostructure. A small 1.8 x 1.2 cms., slightly thick walled cyst with internal echoes is seen in left ovary, appears to be Small Haemorrhagic cyst.

MRS. PRIYA JAIN

41 Yrs./F.

SELF

24th Aug, 2016

PELVIC SONOGRAPHY

Uterus is mildly enlarged in size, is bulky [measures about 11.5 x 7 x 5.5 cms. in diam.] and is globular. The uterine outlines are smooth & regular. The myometrium is slightly heterogenous in echostructure. Endometrial echoes are 12 mms., are smooth & are central. Uterine cavity is empty. No definite mass lesion could be visualized.

Both ovaries are normal in size, shape and echostructure.

No adnexal / pelvic mass or cyst.

No localised or free pelvic collection.

PATIENT NAME : Mrs. RAMA SHRIVASTAVA AGE : 46 Y O M O D SEX
: FEMALE REG NO. : 13010984 REC. DATE : 25/12/2013 REC NO.
: 13C01014406
REFERRED BY : Dr. ARPIT CHOPRA JAIN

Uterus is anteverted, Bulky in size. Measuring 12.6 x 5.4 x 6.7 cm. There is an ill defined hypochoic lesion of size 2.5 x 2.5 cm seen in the anterior myometrium.
Endometrial echoes are central & thickness app 10 mm. Cervix is normal.

PATIENT NAME : Mrs. RAMA SHRIVASTAVA AGE : 49 Y O M O D SEX
: FEMALE REG NO. : 14004861 REC. DATE : 14/06/2014 REC NO.
: 14C01006343
REFERRED BY : Dr. ARPIT CHOPRA JAIN

Bilateral kidneys are normal in size and echotexture. Corticomedullary differentiation is maintained
Rt. Kidney : 10.2 x 5.2 cm Lt. Kidney : 7.8 x 4.2 cm
Left kidney shows two calculi of size 7.8 & 4.2 mm in upper & mid pole calyx. No caliectasis seen at present.

Urinary bladder is distended, shows thin walls and is nonlithiasic.

Uterus is anteverted and measures 9.3 x 5.3 x 5.9 cm, shows homogenous myometrial echotexture.
No evidence of focal myometrial lesion Endometrium is normal. Cervix is normal.

Pt. Name: MRS RANA KHAN

Age/Sex: 47 Years /Female

Ref. By: DR. [MRS.] BHORASKAR VAIJAYANTI
MBBS MD

Date: 23/Jan/2016

ULTRA SONOGRAPHY OF PELVIS + T.V.S.

Before Treatment

Uterus is bulky anteverted & reveals normal shape & smooth outline. One large ovoid echogenic area of about 8.0cm x 3.5cm size is seen in the endometrial cavity, occupying the endocervical canal & the lower segment. Increased vascular supply is observed on color flow imaging. Moderate amount of anechoic fluid in the Endometrium is noted in its fundal part. Myometrium appears normal.

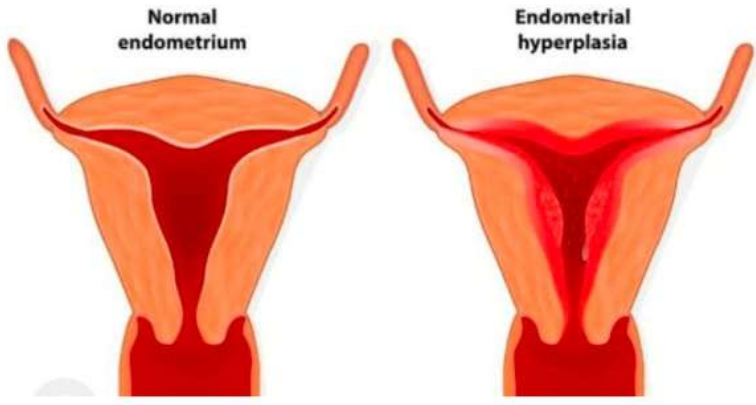
PATIENT NAME :Mrs. RANA KHAN
:FEMALE REG NO. :16001940
:16C01002567
REFERRED BY :Dr. ARPIT CHOPRA JAIN

AGE :47 Y O M O D SEX
REC. DATE :22/03/2016 REC NO.

After 2 months

USG PELVIS

Uterus is bulky & anteverted it measures 12.7 x 5.4 x 3 cm in size, shows homogenous myometrial echotexture. No evidence of focal myometrial lesion. There is approx 5.0 x 2.4 cms sized echogenic focal round mass with small cystic area is noted in the endometrial cavity, it is seems to be arising from endometrium. Increased vascular supply is noted on colour doppler. Endometrium is noted in its fundal part. Cervix is normal.



Overview. Endometrial hyperplasia is a precancerous condition in which there is an irregular thickening of the uterine lining. This may cause uncomfortable symptoms for women, including heavy menstrual periods.

CHHABRA DIAGNOSTIC CENTRE
 For Appointments & Inquiries: Ph: (0731) 4229066, Mob: 77239-42022, Email: chhabradiagnosticsindore@gmail.com, Web: www.chhabradiagnostics.in
 Address: D-33, HIG, Near Shopping Complex, A.B. Road, Indore - 452 011

Timings: Monday to Saturday - 8.00 a.m to 8.00 p.m Sunday & National Holidays - 9.00 a.m. to 1.00 pm

Pt Name: MRS. REENA GIRWAL
 Ref. By: DR PRIYANKA JAIN MBBS D.G.O.
 Age/Sex: 33 Years / Female
 Date: 10/Apr/2024

SONOGRAPHY PELVIC REGION (TVS)

Uterus is retroverted, normal in size, shape & outlines. Myometrial echotexture is smooth & homogenous. **Endometrium is 16 mm thick echogenic.**
 Two cysts seen in endocervix of about 6 mm & 7 mm size.

Both ovaries are normal in size, shape & echotexture. No dominant follicle is observed. No cyst/mass.

No adnexal mass or cyst is seen. **Before Treatment**

No free fluid is observed in pouch of Douglas.

IMPRESSION:
 Hyperplastic endometrium.
 Nabothian cysts endocervix.

Dr. Harish Chhabra
 M.D. (Radio Diagnostics)
 Diploma Musculoskeletal Ultrasonography
 Consultant Radiologist & Sonologist

Dr. Madhu Chhabra
 MBBS, DGO, Fellowship Colposcopy
 PG Diploma Sonography
 PG Diploma Gynaecologist
 Consultant Gynaecologist & Sonologist

CENTRE FOR: SONOGRAPHY DIGITAL X-RAY PATHOLOGY COLOR DOPPLER ECG
 258, Satyadev Nagar, CAT Road, Near Hawa Bungalow, INDORE (M.P.)
 Mob. 78793-81761, 0731-3592099

Pt Name: Mrs. REENA GIRWAL, 34 Y/F, 31/08/2024
 Ref by: - Dr. ARPIT CHOPRA

USG WHOLE ABDOMEN

Liver is normal in size (12.4 cm) and shape. Its echogenicity is normal. Margins are smooth and regular. No focal lesion seen. The portal vein and biliary radicals are normal in calibre.

GB is well distended. Wall thickness is normal. No evidence of calculus or echoes within the lumen. CBD is within normal limits.

Pancreas is normal in size, shape and echo pattern.

Spleen is normal in size (10 cm) and echo pattern.

Rt. Kidney: 10.4 x 4.6 cm Lt. Kidney: 10.3 x 4.8 cm

Bilateral kidneys are normal in shape, size and echo texture. Corticomedullary differentiation is maintained. No evidence of any calculus or hydronephrosis. Both ureter undilated and VUJ clear.

Urinary bladder is normally distended with normal wall thickness. Its lumen is free from echoes or calculus.

Uterus is Anteverted normal size (8.0 x 4.2 x 3.8 cm). Shape & contour maintained. Myometrial echo texture is normal. No focal lesion seen. Endometrium is 6.1 mm in thickness.
 Cervix is mildly bulky its measures 3.1 cms is maximum AP dimensions. A few small nabothian cyst are seen in cervix.

Both ovaries are normal in shape, size and echo texture.

No obvious adnexal lesion noted.
 No free fluid seen in Pouch of Douglas.

The bowel appear undilated and shows normal peristalsis.

No evidence of ascites / significant lymphadenopathy/pleural effusion.

IMPRESSION: Anteverted uterus with bulky cervix & a few small nabothian cysts in cervix.
 No significant abnormality is seen in USG upper abdomen.

DR. BHARTI VERMA MD (Consulting RADIOLOGIST) Regd. No. MP-7546
 Investigations have their limitations, solitary radiological and other investigations never confirm the diagnosis of the disease. They are only of the disease in correlation to the clinical symptoms and other related tests are required. This is a professional opinion, not a

10/4/24

- Nabothian Cyst:- 6mm & 7mm :: Squamous (10/4/24)

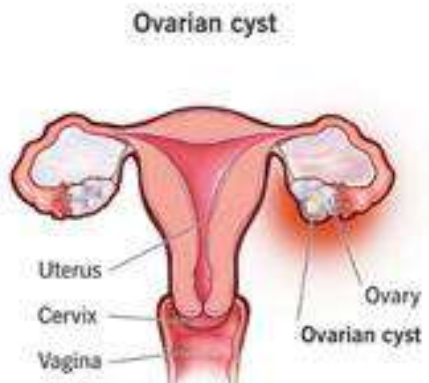- Low Grade Squamous Cell Endocervical polyp? in Colposcopy

हमारी कोई दूसरी ब्राँच नहीं है

डॉ. अर्पित चौपडा (जेन)
 एम. डी. होम्योपैथी
 जटिल, असाध्य एवं शल्य रोग विशेषज्ञ

आरोग्य सुपर स्पेशलिटी माईन होमियोपैथी
 कम्पलिट, परमानेन्ट, ईजी, सेफ, फास्ट एण्ड कॉस्ट इफैक्टिव

102, प्रथम मंजिल, कृष्णा टॉवर, क्योरवेल हॉस्पिटल के सामने, जंजीरवाला चौराहा, न्यू पलासिया, इन्दौर म.प्र.
 99075 27914 संपर्क : 0731-4977076, 79999 78894



WARNING SIGNS OF OVARIAN CYSTS

WOMEN SHOULD NOT IGNORE

- PELVIC PAIN
- PAINFUL INTERCOURSE
- PAIN DURING BOWEL MOVEMENTS
- BREAST TENDERNESS
- VAGINAL BLEEDING OR BLOODY DISCHARGE
- FREQUENT OR URGENT NEED TO URINATE
- STOMACH BLOATING
- NAUSEA OR VOMITING



Handwritten medical notes on a circular stamp from 'SODANI DIAGNOSTIC CLINIC'.

Rt. Ovarian Haemorrhagic Cyst : 16/Nov/22
 W/O : 34x36cm
 15/Nov/22
 Mild pits
 Typhoid (10/11/22)
 Abdomen pain ; LMP : 24/08/22
 5 days flow
 profuse bleeding
 Migraine (headache & vom Nausea)
 Choking & expectoration
 Constipation

Shukati Sonography

Name : Miss. Sheelika Rathore
 Ref. by : Dr. M.S. Solanki Sr M.B. (Medicine) Age: 28 yr

USG - WHOLE ABDOMEN

LIVER : Normal 13.2 cm in Size & Shape. Parenchymal Echotexture & Homogeneity intact & Extrahepatic Biliary Radicals Are Normal. Portal vein & C.B.D. are Normal in Caliber. No Focal Lesions.

GB : Normal Size wall & in Contact w/ Gallbladder.

SPLEEN : Normal in Size (10.7 cm), Shape & Echotexture.

PANCREAS : Normal in Size, Shape & Echotexture. Peripancreatic Dust Unaltered.

KIDNEY : Rt. Normal in Size, Shape, Position & Echotexture. Left Kidney - Difficult to Visualize. Maintained & Normal Size/Position for Normal Size Ovary.

ADRENAL GLANDS : Normal in Size, Shape & Echotexture.

BLADDER : Normal in Size, Shape & Echotexture. No Focal Lesions. Post Void Residual Urine is Normal.

OVARY : Approx. 3.8x2.8 cm Size Well-defined Anecchoic Cystic lesion with Thin Internal Septations Seen in Rt. Ovary. However Vascularity Appears Normal in Rt. Ovary. Lt. Ovary Normal. Mod Amount of Free Fluid Seen in Pouch of Douglas.

IVC & AORTA : Normal in Caliber. No Aortic Wall Thickening. No Pericardial Effusion.

BOWEL : Visualized Bowel Loops Appear Normal in Caliber & Shows Normal Peristalsis on USG. Peristalsis Not Visualized.

IMPRESSION : Rt. Ovarian Haemorrhagic Cyst with Mild Pits.
 Clinicopathological Co-relation & Follow up after 4 to 6 week.

SODANI DIAGNOSTIC CLINIC

ULTRASOUND REPORT

WHOLE ABDOMEN SONOGRAPHY

General abdomen
 Hepatic contour is smooth & size is normal. Parenchymal echotexture is normal. No focal lesion is seen. Extrahepatic biliary radicals are normal.
 Gall bladder is normally distended. Size is 10 cm. No stones & sludge seen. No per GB collection is seen.

Portal vein & CBD are normal in caliber.
 Pancreas is normal in shape & size. Peripancreatic echogenicity is normal. Duct is unaltered. Spleen is normal in size. No focal lesion seen.

Both kidneys are normal in position & size. Right kidney is 10.2 x 4.2 x 4.2 cm. Left kidney is 11.4 x 4.2 x 4.2 cm. Cortical-medullary junction is well defined. No focal lesion is seen. No hydronephrosis is seen. No pericardial effusion is seen.

Uterus is anteverted. It measures 11.7 x 3.8 x 3.8 cm. No focal mass or lesion seen. Cervix is normal in thickness. Endometrium is 2.2 cm thick.

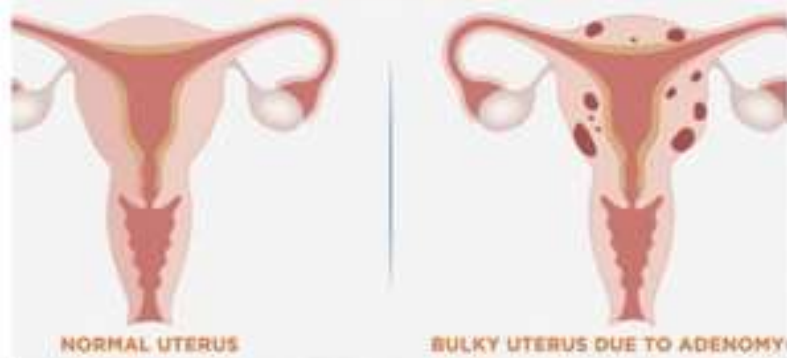
Both ovaries are normal in size. Right ovary is 3.8 x 2.8 cm & left ovary is 3.8 x 2.8 cm. Both ovaries are normal. No cyst seen.

No free fluid seen in peritoneal. No significant ascites. No pleural effusion. No significant bowel wall thickening. Distal or sigmoid colon is not seen.

Impression
 - No hepatobiliary lesion seen.
 - Normal sized echogenicity with unaltered peristalsis.
 - Constipation / indigestion suggested.

After Dr ARPIT Chopra Modern Homeopathy

BULKY UTERUS



NORMAL UTERUS

BULKY UTERUS DUE TO ADENOMYOSIS

कैंसर, किडनी फेलिचर, अस्पताल में गंभीर रूप से पती बरिनो का उपचार, झोपा, शल्य चिकित्सा योग्य रोग, अटो इम्यून रोग, जीवनभर दवाई लेने वाले रोगों की रोकथाम एवं 300 प्रकार के असाध्य जटिल रोगों की चिकित्सा।

आरोग्य सुपर स्पेशलिटी मॉडर्न होमियोपैथी
कम्प्लिट, परप्रापेच, इंटी, सेक, फास्ट एण्ड कॉस्ट इफेक्टिव

122, इण्डियन कॉलेज, कृष्ण टॉवर, न्यूरोसेल इंडिया के बिल्डिंग, जयवीरवाडी रोड, न्यू प्लानिंग, इन्डियन प.क. (कलकत्ता-700044) फोन: 033-2477074, 70888 70888
www.homiotherapy.com, www.surgery.homiotherapy.com Email: ap@hiotherapy@gmail.com

पुर्विमो हॉस्पिटल
एंड रिसर्च सेंटर
ULTRASONOGRAPHY REPORT

WHOLE ABDOMEN

Liver is normal in size parenchymal echotexture homogeneous. Gall & extrahepatic biliary channels is normal. Spleen is normal in size shape & echotexture. Both kidneys are normal in size, shape, echotexture with normal calyces. Pelvic/ovarian system of both kidneys are unremarkable. Both ovaries are unremarkable. Uterus is normal in size, shape & echotexture. Endometrium is normal in size, shape, echotexture & echotexture. No adnexal mass seen. No free fluid seen in pouch of Douglas.

Diagnosis: Bulky Uterus with Endometrium hyperplasia.

Dr. RENU PUNJABI
Diagnostic Centre

PL. Name: MKS. ROSHNI NAVEEN SATLE
Ref: DR. ARPIT CHOPRA (MD) MD (HOMEOPATHY)
Age/Sex: 42 Year / F
Date: 28.07.2021

SONOGRAPHY - WHOLE ABDOMEN

This examination was performed as an overall examination during the course of 18 patients with all precautions & inherent limitations as usual.

This examination demonstrates mild diffuse hepatomegaly (about 15.1cm in width/upper line) & shows mild parenchymal echotexture with fatty infiltration grade I. The focal lesion seen. Intra hepatic biliary radicles unremarkable. Portal & hepatic veins appear normal.

Gall bladder is contracted (gastrointestinal status). CBD is unremarkable, normal in caliber. Pancreas is normal in size and echotexture. Spleen is normal in size and echotexture.

Right kidney measures 8.7 x 3.8 cm and left kidney measures 8.1 x 4.5 cm in size. Both kidneys are normal in size, shape, echotexture with normal calyces. Pelvic/ovarian system is unremarkable on both sides. There is no evidence of swelling or obvious calculus shadow seen on either side. Corticomedullary differentiations & mild normal kidneys are normal. Both ureters are unremarkable and not visualized.

Abdominal aorta is normal in caliber. No evidence of intrabdominal lymphadenopathy is seen. Urinary bladder is well distended, normal in shape & unremarkable with a normal wall thickness is normal.

Uterus is normal in size, shape & echotexture. Measures 8.2 (anteroposterior length) x 4.6 x 4.1 cm in size. Myometrial echotexture is unremarkable & homogeneous. Endometrial echo is normal. TV measures 4 mm. Cervix & adnexal mass are normal. Both ovaries are normal in size, shape & echotexture. No free fluid is observed in pouch of Douglas. Post void vesicle is unremarkable.

IMPRESSION: USG suggests: Mild Hepatomegaly secondary to fatty infiltration.

Dr. RENU PUNJABI
MBBS, D.M.D. (P.H.D. M.D.)
RADIOLOGIST & SONOLOGIST

Adenomyosis

A condition in which endometrial tissue exists within and grows into the **uterine wall**.

Symptoms may include

- Painful intercourse
- Menstrual cramps
- Abdominal pain

BULKY UTERUS / ADENOMYOSIS July 12

Handwritten notes in Hindi describing the condition and treatment. The text is dense and difficult to read due to cursive handwriting.

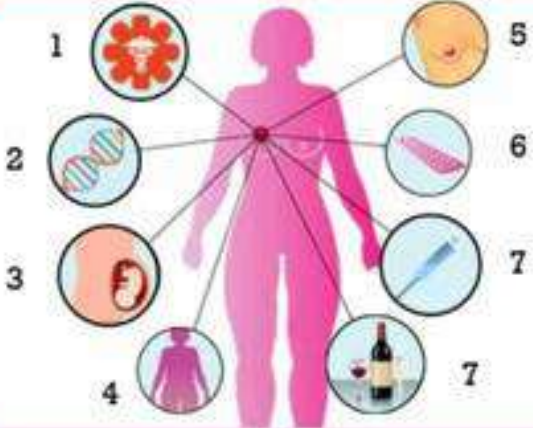
Dr. Arpit Chopra (MD) MD (HOMEOPATHY)
RADIOLOGIST & SONOLOGIST

Complete, Permanent, Easy, Safe, Fast & Cost Effective Cure



ONLINE CONSULTATION AVAILABLE : WWW.HOMOEOPATHYCURE.IN / WWW.AAROGYAHOMOEOPATHYINDORE.COM

Causes and Risk Factors of Breast Cancer



- Family history
- Gene mutation
- Late childbearing
- Early Menstruation & Late Menopause/ Obesity
- Increased breast density
- Prolonged use of oral contraceptives
- Hormone replacement therapy after menopause
- Alcohol intake/ tobacco

BREAST CANCER SYMPTOMS

Early diagnosis of cancer generally increases the chances for successful treatment.

Breast cancer

- Overview
- Symptoms
- Treatments

कैंसर, किडनी फेलियर, अस्पताल में गंभीर रूप से भर्ती मरिजों का उपचार, कोमा, शल्य चिकित्सा योग्य रोग, ऑटो इम्यून रोग, जीवनभर दवाई लेने वाले रोगों की रोकथाम एवं 300 प्रकार के असाध्य जटिल रोगों की चिकित्सा।

आरोग्य सुपर स्पेशलिटी मॉडर्न होमियोपैथी
कम्प्लिट, परमानेंट, ड्रूजी, रोफ, फास्ट एण्ड कॉस्ट इफिक्टिव

102, प्रथम मंजिल, कृष्ण टॉवर, इकोलेव हॉस्पिटल के सामने, नजीरवाला रोड, न्यू फ्लोरिडा, इन्डोर म.प्र.

* कैंसर * किडनी फेलियर * अस्पताल में गंभीर रूप से * भर्ती मरिजों का उपचार * कोमा * शल्य चिकित्सा योग्य रोग आँटो इन्फ्यून रोग * जीवनभर दवाई लेने वाले रोगों की रोकथाम एवं 300 प्रकार के असाध्य जटिल रोगों की चिकित्सा ।

आरोग्य सुपर स्पेशलिटी मॉडर्न होम्योपैथिक क्लीनिक
 कम्प्लिट * परमानेन्ट * इंडी * सेफ * फास्ट एण्ड कॉस्ट इफेक्टिव
 102, प्रथम मंजिल, कुण्डल टॉवर, क्वींसरोड होस्पिटल के सामने, अंजीरवाला बौराहा, न्यू पल्लिका, इन्दौर (म.प्र.)
 फोन : 0731-4977076, मो. : 97130-92737, 97130-37737, 79999-78894, 99078-27914
 www.homoepathycure.in, www.aarogyahomeopathyindore.com Email : arpitchopra23@gmail.com



डॉ. अर्पिता चोपड़ा (वैद्य)
 एम. डी. होम्योपैथी
 जर्मन, अमेरिकन एवं
 अन्य देश विदेश

Dr. Ravindra K. Kadamkar
KRUTI DIAGNOSTIC & MRI CENTRE
 231, Jewahar Marg (Medhar Mandir), Newraj Sagar Chauraha, INDORE - 472
 Phone : 0731-2542839, 2430595
 * MRI * Whole Body Spine/CT Scan * Digital X-Ray / EEG / ECG
 * 4D Sonography / Echocardiography / Colour Doppler * Digital DPG

Mrs. Meena Pagarani 49 y F
 Dr. Samita Singh 05/07/21
 Reg No :

Sonography Abdomen

The liver is mildly enlarged in size measuring 16.9cm in MCL. The margins are smooth. It is more echogenic than normal. The portal vein & CBD are normal.

The gall bladder is physiologically distended & non lithiasic.

The pancreas & spleen are normal.

Both kidney are normal in position size contour & cortical echotexture is normal. The corticomedullary differentiation is fair. The pelvicalyceal system & ureters are not dilated.

The urinary bladder is normal.

The uterus is anteverted normal in size measuring 8.5 cms in long axis & 6.2 cms transversely. The margins are smooth. The myometrial echotexture is normal. The endometrial echo is thickened (14-15mm) with a clot in endometrial cavity.

Ovaries are normal.
 No pelvic mass/collection. No ascites.
 No obvious collection seen in RIF at present.

CONCLUSION

Enlarged echogenic liver suggest Gt 1 fatty changes.
 Normal gall bladder pancreas spleen.
 Structurally normal kidneys bladder & ovaries.
 Normal sized anteverted uterus with thickened endometrium.
 Endometrial hypoplasia with a clot in endometrial cavity.

before modern homoeopathy treatment

Dr. Ravindra K. Kadamkar
KRUTI DIAGNOSTIC & MRI CENTRE
 231, Jewahar Marg (Medhar Mandir), Newraj Sagar Chauraha, INDORE - 472
 Phone : 0731-2542839, 2430595
 * MRI * Whole Body Spine/CT Scan * Digital X-Ray / EEG / ECG
 * 4D Sonography / Echocardiography / Colour Doppler * Digital DPG

Mrs. Meena Pagarani 49 y F
 Dr. Samita Singh 05/07/21
 Reg No :

Sonography Abdomen

The liver is mildly enlarged in size measuring 16.9cm in MCL. The margins are smooth. It is more echogenic than normal. The portal vein & CBD are normal.

The gall bladder is physiologically distended & non lithiasic.

The pancreas & spleen are normal.

Both kidney are normal in position size contour & cortical echotexture is normal. The corticomedullary differentiation is fair. The pelvicalyceal system & ureters are not dilated.

The urinary bladder is normal.

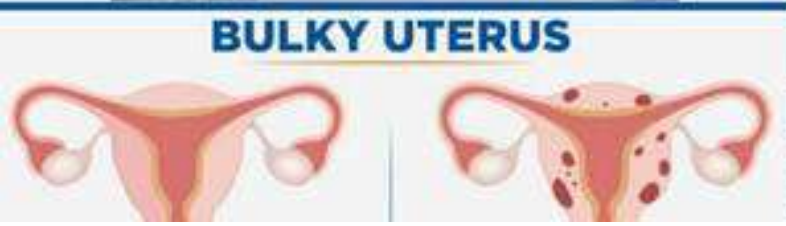The uterus is anteverted normal in size measuring 8.5 cms in long axis & 6.2 cms transversely. The margins are smooth. The myometrial echotexture is normal. The endometrial echo is thickened (14-15mm) with a clot in endometrial cavity.

Ovaries are normal.
 No pelvic mass/collection. No ascites.
 No obvious collection seen in RIF at present.

CONCLUSION

Enlarged echogenic liver suggest Gt 1 fatty changes.
 Normal gall bladder pancreas spleen.
 Structurally normal kidneys bladder & ovaries.
 Normal sized anteverted uterus with thickened endometrium.
 Endometrial hypoplasia with a clot in endometrial cavity.

after modern homoeopathy treatment



Menorrhagia : 8 days + 6 mm
 Intermittent bleedings
 Refuse

Cervical Cancer
RECENTLY DIAGNOSED
CHRONIC
PROBLEM CURED

Dr. Arpit Chopra Jain
MD Homoeopathy
Cancer & Surgical

Success Story 25:35

क्या आप सर्वाइवल
कैंसर से रोशन हैं

सर्वाइवल कैंसर को
कैसे घटा कर

33:40

Patient - Jansika Hood

Cancer Cured

सर्वाइकल
कैंसर का
सफल
इलाज

Success Story 16:44

Dr. Arpit Chopra Jain
MD Homoeopathy
(Cancer & Surgical)

गर्भाशय
लक्षण
CERV
Dr Arp

bulky Uterus
छोटीदानी में सूजन

सफलता

Endometrium
Thickness
30 mm to 4 mm

20:21

रसदीप्त गंधैर वीमडियाँ का राकल इलाज

आज सुनें अगर मैं 4:12:2 क्या भी सुनूँ...
(Viraladenoma) के बारे में बात कीजिये...
जिनके बारे में सुनें, उन्हें फिर
से रोशन हो जायेंगे।
जिनके बारे में सुनें, उन्हें फिर
से रोशन हो जायेंगे।
जिनके बारे में सुनें, उन्हें फिर
से रोशन हो जायेंगे।

Dr. Arpit Chopra Jain (MD) Homeopathy

OVARIAN CYST CURED IN 1 MONTH
In both ovary | Dr. Ar...
Dr Arpit Chopra's Super...

Ovarian Cyst cure Treatment without surgery Dr A...
Dr Arpit Chopra's Super...

Multiple diseases Cured होम्योपैथी से
Piles Ovarian
Thyroid
Diabetes
Success Story By Patient 4:33

Patient Success Story | Piles | Ovarian Cyst | Diabetes | Hy...
Dr Arpit Chopra's Super...

Ovarian Cyst cure |

Cancer Cured

ओवेरियन
कैंसर
का सफल
इलाज

Success Story 14:22

Dr. Arpit Chopra Jain
MD Homoeopathy
(Cancer & Surgical)

OVARIAN CANCER METASTATIC TO OMENTUM of Nisha...
Dr Arpit Chopra's Super...

आरोग्य सुपर स्पेशलिटी मॉडर्न होम्योपैथिक क्लिनिक

डॉ. अर्पित चोपड़ा

www.homoeopathycare.in, www.arpitforhomoeopathy.com

5.2 x 4.8 CM
UTERINE FIBROID LARGE SIZED CASE
Dr Arpit Chopra's Super...

UTERINE
ENDOMETRIUM
POLYP 2.5 x 2.2 CM ...
Dr Arpit Chopra's Super...

UTERINE
ENDOMETRIUM
POLYP 2.5 x 2.2 CM ...
Dr Arpit Chopra's Super...

AAROGYA SUPERSPECIALITY MODERN HO...
Complete, Safe, Fast & Cost Effective Modern Homoeopathy Care
Phone: 0711-487696, Mobile: 97130-07137, 97130-07137, 79999-788

MEOPATHIC CLINIC, COMPLETE

INFE DUE TO PCOS (
Dr Arpit

FALL TUBE B CORNU
Dr Arpit

Ovarian cyst issue cured ...
Ovarian cyst & Kidney stone cured by Dr A...
Dr Arpit Chopra's Super...

Cervical Cancer
RECENTLY DIAGNOSED
CHRONIC
PROBLEM CURED

Dr. Arpit Chopra Jain
MD Homoeopathy
Clinical & Surgical
Success Story

सफल 25:35

पॉसट-ऑपरेटिव कैंसर

क्या जखम सहीकर
कैंसर से परेशान है

सर्घाकृत कैंसर को
कैसे खत्म करें

33:40

Patient - Jansika Jain

Cancer Cured

सुबाइकल
कैंसर का
सफल
इलाज

Success Story 16:44

Chopra Jain
MD Homoeopathy
& Surgical

गर्भाश
लक्षण
CERV
Dr Arp

Uky Uterus
स्वेदनी में वृद्धन

सफलता

20:21

सम्बन्धित गर्भरोगों का सफल इलाज

जब कुछ वर्षों में CA 125 का स्तर बढ़ता है तो इसका मतलब है कि कैंसर (Ovarian Cancer) के कारण है। यह कैंसर कोशिकाओं के अत्यधिक बढ़ने से होता है।

Dr. Arpit Chopra (MD) की मदद से

OVARIAN CYST CURED IN 1 MONTH
In both ovary | Dr. Ar...

Dr Arpit Chopra's Super...

19:55

Ovarian Cyst cure Treatment
without surgery Dr A...

Dr Arpit Chopra's Super...

21:24

Patient Success Story | Piles | Ovarian Cyst | Diabetes | Hy...

Dr Arpit Chopra's Super...

19:53

Success Story By Patient

Cancer Cured

ओवैरियन
कैंसर
का सफल
इलाज

Success Story 14:22

Dr. Arpit Chopra Jain
MD Homoeopathy
Clinical & Surgical

OVARIAN CANCER METASTATIC TO OMENTUM of Nisha...

Dr Arpit Chopra's Super...

आरोग्य सुपर स्पेशलिटी मॉडर्न होम्योपैथिक क्लिनिक

कृत्रिम वृद्धन के लिए वृद्धन के लिए वृद्धन के लिए वृद्धन के लिए

Dr. Arpit Chopra Jain
MD Homoeopathy
Clinical & Surgical

5.2 x 4.8 CM UTERINE FIBROID LARGE SIZED CASE

Dr Arpit Chopra's Super...

1:00

UTERINE ENDOMETRIUM POLYP 2.5 x 2.2 CM

Dr Arpit Chopra's Super...

14:21

UTERINE ENDOMETRIUM POLYP 2.5 x 2.2 CM

Dr Arpit Chopra's Super...

16:23

AAROGYA SUPERSPECIALITY MODERN HO

Competition, Safe, Fast & Cost-Effective Modern Homoeopathy Care

Home: 011-45111111, Mobile: 91100-80191, 91100-80192, 7966-108

MEOPATHIC CLINIC COMPLEX

INFE DUE TO PCOS

Dr Arpit

0:52

FALL TUBE B CORNU

Dr Arpit

0:23

n cyst issue cured via...

Chopra's Team Homoeopathy

0:14

Ovarian cyst & both issues cured by Dr. Arpit Chopra's Super...

Title

Breast Cyst Abscess Mastitis 8.1x 3.4 cm Cured without surgery by Dr Arpit Chopra

👉 BREAST ABSCESS 8 1x3.4CM WITH
MASTITIS NODULE large sized
DISSOLVED & CURED SUCCESSFULLY
WITHOUT SURGERY BY MODERN
HOMOEOPATHY TREATMENT TO SAVE
SURGERY, FURTHER COMPLICATION &
RECURRENCE. Patient had successfully

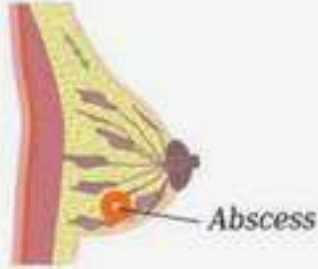
आरोग्य सुपर स्पेशलिटी मॉडर्न होम्योपैथिक क्लीनिक

कंप्यूटिड * परमावेर * इंजी * लेक * फास्ट एण्ड कॉस्ट इफेक्टिव

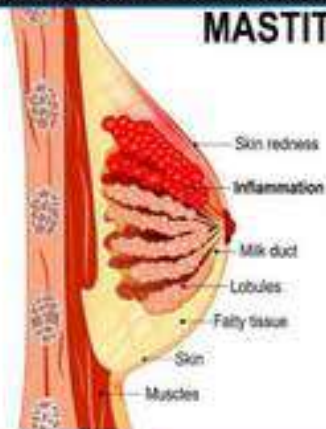* कैंसर * किडनी फेलियर * अस्पताल में गंभीर रूप से भर्ती मरीजों का उपचार * कोषा *
 * शत्रु चिकित्सा चोप्य रोग * आँटो इन्फ्यू रोग * जीवनभर दवाई लेने वाले रोगों की चिकित्सा
 एवं 100 प्रकार के असाध्य जटिल रोगों की चिकित्सा।

111, 114 प्रथम मंजिल, दुमरा टोला, मकोदर हस्पिटल के सामने, जडीबाला रोड, न्यू पारमिया, इन्दौर (म.प्र.)
 फोन : 0731-4577076, मो. : 97130-82737, 97130-37737, 79999-78894, 99075-27514
 www.homeopathycure.in, www.sarogyahomeopathyindore.com Email : apichopra23@gmail.com

An abscess in the breast



MASTITIS



Handwritten notes on a piece of paper. The text is in Hindi and appears to be a medical history or treatment notes for a breast condition. It includes dates like 'November 12' and mentions 'Breast Abscess/Mastitis'.

Handwritten medical notes on a piece of paper. It includes sections for 'TREATMENT GIVEN', 'HISTORY REPORT', 'INVESTIGATION', and 'CONDITION ON DISCHARGE'. The text is in Hindi and describes a breast condition, mentioning 'Breast Abscess/Infective etiology' and 'pus filled abscess'.

SODANI DIAGNOSTIC CLINIC

SODAL OR X-RAY MAMMOGRAPHY REPORT

- Biopsy, see my file, see CD Digital & Ray mammography performed.
- Both MLO & lateral MLO - Degree of Mass and CC views taken. Compression applied.
- Biobasal breast per compression with fatty - granular parenchyma.
- No evidence of suspicious opacified mass formally seen.
- No architectural distortion seen.
- No evidence of abnormal cluster of pleomorphic microcalcification in seen.
- Skin, nipple - clearly complex shadow appears normal.
- No evidence of significantly enlarged axillary lymphatics.

IMPRESSION: Mammographic appearance of breast in current file is **BI-RADS Assessment Category 2** (benign category 2) (breast see Group 2) (see 21000) (breast of current Clinical annual screening mammography).

FINAL ASSESSMENT: Benign. (benign, non-malignant). (benign, non-malignant, benign, non-malignant, benign, non-malignant).

2/3

after modern homoeopathy treatment

Printed medical report from Mahatma Gandhi Memorial Medical College & Mahatma Jyotibai Phule Hospital. The report is titled 'CYTOLOGY REPORT' and includes sections for 'ANALYSIS', 'REPORT', 'COMMENT', and 'DISCUSSION'. The text is in Hindi and describes the findings of a cytology examination.

before treatment

BULKY UTERUS

SURGICAL ADVISED CASE CURED

क्रिटिकल केस का सफल ईलाज



Mrs. Meena Pagrani

Cervical Cancer
RECENTLY DIAGNOSED
CRONIC PROBLEM CURED
सर्वप्रकार का सफल इलाज
सर्वप्रकार का सफल इलाज
Success Story 25:35

एक जगत् सर्वप्रकार का सफल इलाज
सर्वप्रकार का सफल इलाज
Success Story 33:40

Cancer Cured
सर्वांगिक कैंसर का सफल इलाज
Success Story 16:44

गर्भाशय लक्षण CERV
Dr Arp

Bulky Uterus
गर्भाशय में सूजन
सफल इलाज
Success Story 20:21

सम्बन्धित गंभीर बीमारियों का सफल इलाज

जब कोई रोग में 6x2.2 का भी सफल इलाज का केस है तो यह बीमारियों का इलाज करने में सफलता के लिए एक अच्छा संकेत है।
Cervical/Cervix Cancer को 3 में 4 तक तक भी सफल इलाज करने में सफलता के लिए एक अच्छा संकेत है।
Dr. Arpit Chopra (MD) ने 1000 से अधिक गंभीर बीमारियों का सफल इलाज किया है।
Dr. Arpit Chopra (MD) ने 1000 से अधिक गंभीर बीमारियों का सफल इलाज किया है।



Ovarian Cyst CURED IN 1 MONTH
In both ovary | Dr. Ar...
Dr Arpit Chopra's Super...

Ovarian Cyst cure Treatment without surgery
Dr A...
Dr Arpit Chopra's Super...

Piles Ovarian Thyroid Diabetes
Success Story By Patient

Ovarian Cyst cure |

Cancer Cured
ओवैरियन कैंसर का सफल इलाज
Success Story 14:22

OVARIAN CANCER METASTATIC TO OMENTUM of Nisha...
Dr Arpit Chopra's Super...

आरोग्य सुपर स्पेशलिटी मॉडर्न होम्योपैथिक क्लिनिक
होम्योपैथिक इलाज के लिए एक नया आयाम
Dr. Arpit Chopra (MD) ने 1000 से अधिक गंभीर बीमारियों का सफल इलाज किया है।

5.2 x 4.8 CM UTERINE FIBROID LARGE SIZED CASE
Dr Arpit Chopra's Super...

UTERINE ENDOMETRIUM POLYP 2.5 x 2.2 CM
Dr Arpit Chopra's Super...

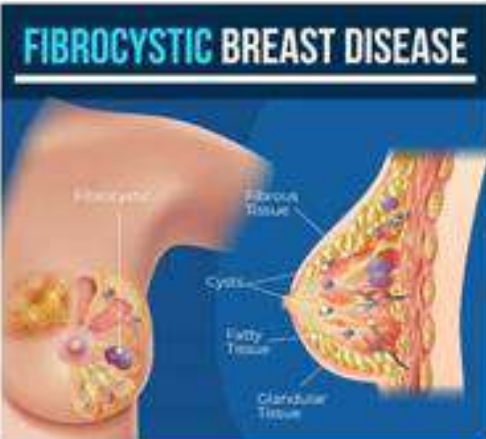UTERINE ENDOMETRIUM POLYP 2.5 x 2.2 CM
Dr Arpit Chopra's Super...

आरोग्य सुपरस्पेशलिटी मॉडर्न होम्योपैथिक क्लिनिक
होम्योपैथिक इलाज के लिए एक नया आयाम
Dr. Arpit Chopra (MD) ने 1000 से अधिक गंभीर बीमारियों का सफल इलाज किया है।

INFE DUE TO PCOS (
Dr Arpit

FALL TUBE B CORNU
Dr Arpit

ovarian cyst issue cured
Success Story 14:22



आरोग्य

कैंसर, किडनी फेलियर, अस्पताल में गंभीर रूप से भर्ती मरीजों का उपचार, कोमा, शल्य चिकित्सा योग्य रोग, ऑटो इम्यून रोग, जीवनभर दवाई लेने वाले रोगों की रोकथाम एवं 300 प्रकार के असाध्य जटिल रोगों की चिकित्सा।

आरोग्य सुपर स्पेशलिटी मार्टन होमियोपेथी
 कम्प्लिट, परमानेंट, ईजी, सेफ, फास्ट एंड कॉस्ट इफेक्टिव

102, प्रथम मंजिल, गुणगा टॉवर, गवर्नेर हॉस्पिटल के सामने, वजीरगंजा गौराहा, न्यू एलाहिया, इन्दौर म.प्र.
 09875 27914 संपर्क : 0731-4977076, 79669 78864
www.homoecosthycure.in, www.aarogyahomeopathyindore.com, Email : arpitchopra23@gmail.com

Malwa Diagnostics
 102, Pratham Manjil, Gunaga Tower, Govind Hospital, Vajirganja, Indore, M.P.

Patient's Name: Mrs. Zarish, Age: 28 Yrs, F
 Ref Consultant: Dr. Mrs. Madhu Bora, Date: 12.01.2016

DIGITAL MAMMOGRAPHY

Modern day mammography is performed in both craniocaudal & medio-lateral views. The breasts are placed in solar and upper coil respectively. Compression applied.

There are cysts and fibrous changes seen on right. The left breast is normal.

IMPRESSION: Mammography suggests mild fibrocystic changes on right.

before Modern Homeopathy Treatment of 10 years

ACCURATE DIAGNOSTICS
 Digital Mammography • Ultrasound • CT • Ultrasound • Colonoscopy • Sigmoidoscopy • Colonoscopy • Endoscopy • Colonoscopy • Endoscopy

Patient's Name: Mrs. Zarish, Age: 28 Yrs, F
 Ref Consultant: Dr. Jyotsna Halkar, Date: 07.11.2016

DIGITAL MAMMOGRAPHY

Modern X-ray mammography is performed in both craniocaudal & medio-lateral views. The breasts are placed in solar and upper coil respectively. Compression applied.

The breast parenchyma shows very minimal mild fibrocystic changes both the sides.

No significant mass lesion or microcalcifications are seen.

The skin and subcutaneous tissues are normal.

The nipples and axilla are free.

IMPRESSION: The Mammographic appearance suggest mild fibrocystic changes and no areas of microcalcifications are seen.

before Modern Homeopathy Treatment of 6 years

Visesh Jupiter Hospital

102, Pratham Manjil, Gunaga Tower, Govind Hospital, Vajirganja, Indore, M.P.

MAMMOGRAPHY (DIGITAL MAMMOGRAM) & THERAPEUTIC RECOMMENDATIONS

Clinical History: Screening bilateral breast lump on right.

Observations:
 - Bilateral breasts are contracted with mild skin-glandular appearance.
 - No visible significant suspicious mass lesion seen.
 - No obvious cluster or pleomorphic microcalcification seen.
 - No architectural distortion seen.
 - Skin & nipple structures are normal.
 - Clear axillary lymphatics with no axilla seen.

IMPRESSION:
 No abnormal digital mammographic and ultrasonographic appearance observed in view of suspicious calcifications or architectural distortion seen in bilateral breasts. Category I (BI-RADS) No lesion.

After Dr Arpit Chopra Aarogya Modern Homeopathy Treatment of 6 months

Fibroids

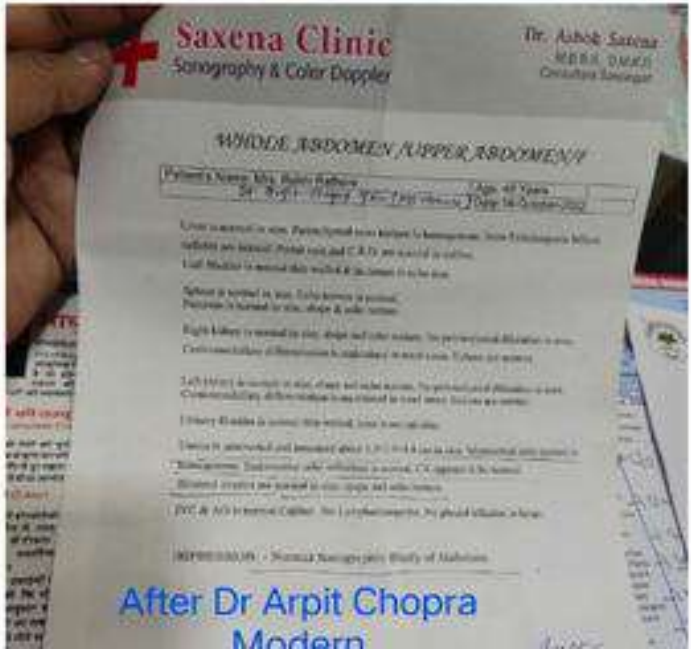
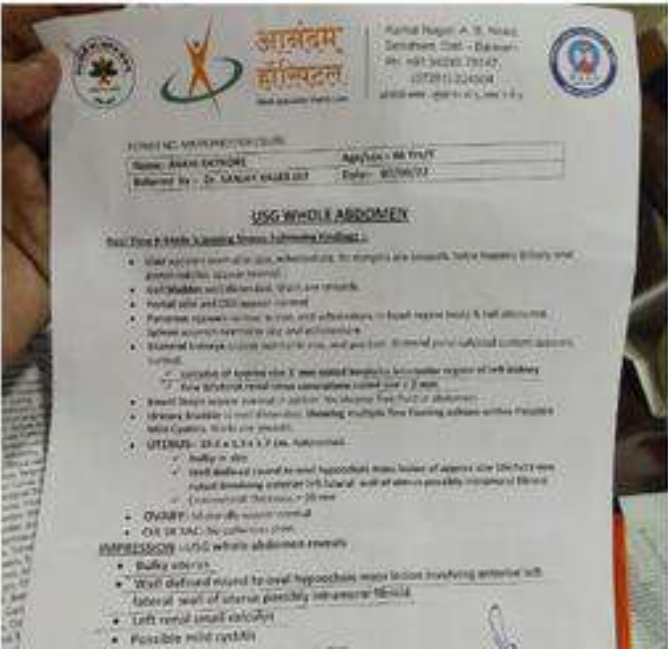
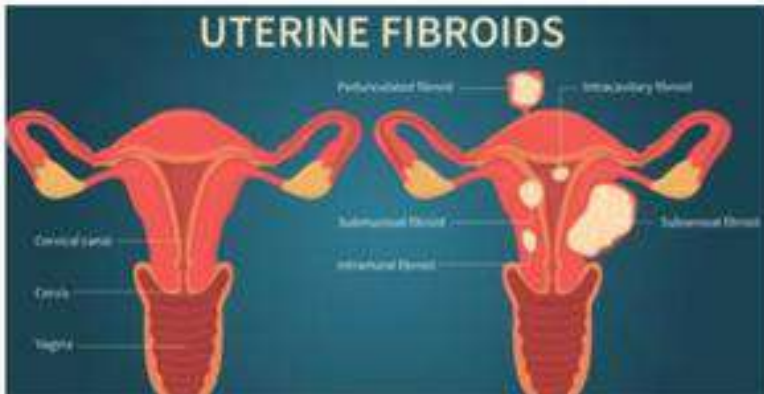
Also called: Uterine myoma

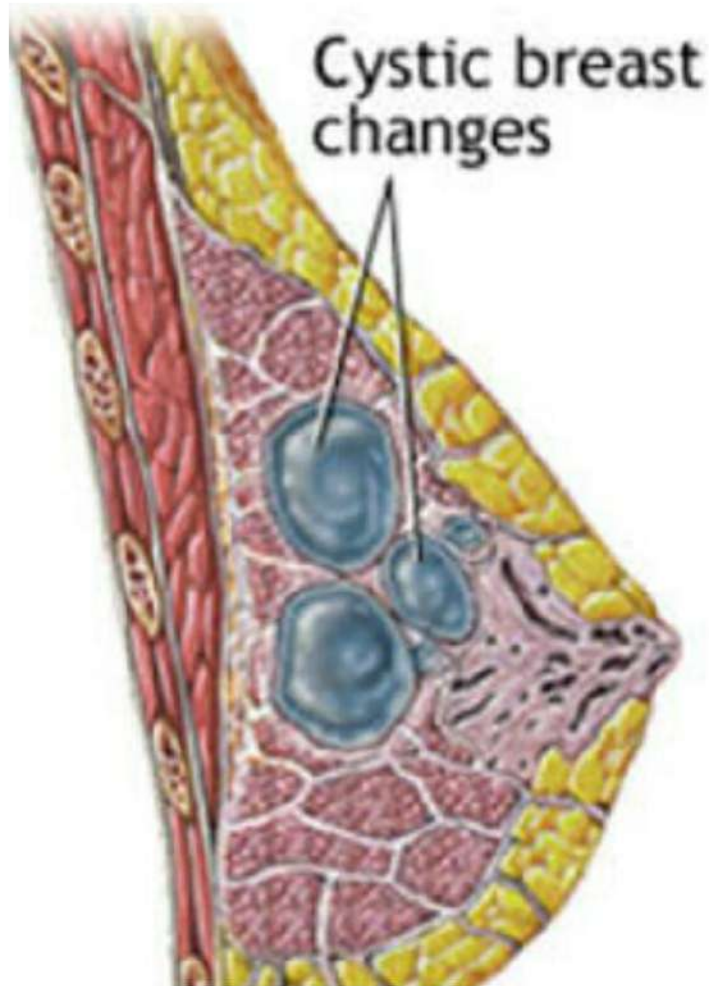
- Overview
- Symptoms
- Treatment

Non-cancerous growths in the uterus that can develop during a woman's childbearing years.

The cause of fibroids isn't well understood. Risk factors include a family history of fibroids, obesity or early onset

Uterine Fibroid (Intramural) 7/9/22
 10x7x18mm
 → Bulky uterus 10.6x8.3x5.7cm
 → Endometrial thickness 10mm
 → Left renal small calculus (3mm)
 → Bil Renal sinus calcifications <2mm
 → Mild cystitis
 → Bloating of Abdomen & backache





Cystic breast changes

Δ FIBROADENOSIS

Wednesday
3rd Week • 017-348

17

JANUARY 2018

10:00 मे रेखा चौधरी इंदौर मे रहती है
11:00 मे बरत मे गठान को पुसका
मुपेक्षत एवु नरु करना निमाया
12:00 लीला नार मे करे से वन राया
डोकर नरु निरु उपेक्षत क निरु
13:00 वरुन लीला मतु हो. अपित चौधरु
को गठान देखनेपेय से परामुशरु
14:00 किया एवु इंदौरु करवाया एवु कि
ए गठान मे निरुन ठिक हो राया।

14:00 धान्यवद सर

15:00 Rekha choudhary
Address - Khandwa Naka Indore
16:00 Mob No - 8750476718

ACCURATE DIAGNOSTICS
625, Khairwala Tank, Indore, Phone : 0731 - 2470005, 4001821, 9893577955

Digital Mammography • Digital X-ray • 21 Channel EEG • Colour Doppler • Sonography
• Echo-cardiography • Pathology • ECG

Patient's Name: Miss. Rekha 22
Age: 47 Yrs.F
Ref. Consultant: Dr. Tulsi Patil Date: 01.05.2017

DIGITAL MAMMOGRAPHY

Bilateral X-ray mammography is performed in both cranio-caudal & medio-lateral views. The markers are placed in outer and upper side respectively. Compression applied.

The breast parenchyma show increased density and severe congestion all over.

No definite mass lesion is seen separable from dense breasts. No microcalcifications are seen.

The nipples and areola are free.

The skin and subcutaneous tissues are normal.

No lymph node enlargement is seen.

IMPRESSION: - Mammographic appearances are suggestive of Fibroadenosis both sides while no separable lesion seen.

Adv: Clinical follow up and FNAC if a clinical lump is palpable.

Note :- There is no mammographic abnormality of cancer in 5% of the patients diagnosed as benign breast disease or normal by this method.

DR. ASHOK TYAGI.

ACCURATE DIAGNOSTICS
625, Khairwala Tank, Indore, Phone : 0731 - 2470005, 4001821, 9893577955

Digital Mammography • Digital X-ray • 21 Channel EEG • Colour Doppler • Sonography
• Echo-cardiography • Pathology • ECG

Patient's Name: Ms. Rekha Choudhary Age: 24 Yrs.F
Ref. Consultant: Dr. Tulsi Patil Date: 21.12.2017

DIGITAL MAMMOGRAPHY

Bilateral X-ray mammography is performed in both cranio-caudal & medio-lateral views. The markers are placed in outer and upper side respectively. Compression applied.

The breast parenchyma show slight increased density all over and no altered architecture seen.

No definite mass lesion is seen separable from dense breasts. No microcalcifications are seen.

Limited sonography of right breast suggest significant dilatations of lactiferous ducts in outer upper and outer middle quadrant at around 9 and 10o'clock positions. The ducts show smooth walls and no intraductal pathology is seen. The larger duct is 5mm size.

The nipples and areola are free.

The skin and subcutaneous tissues are normal.

No lymph node enlargement is seen.

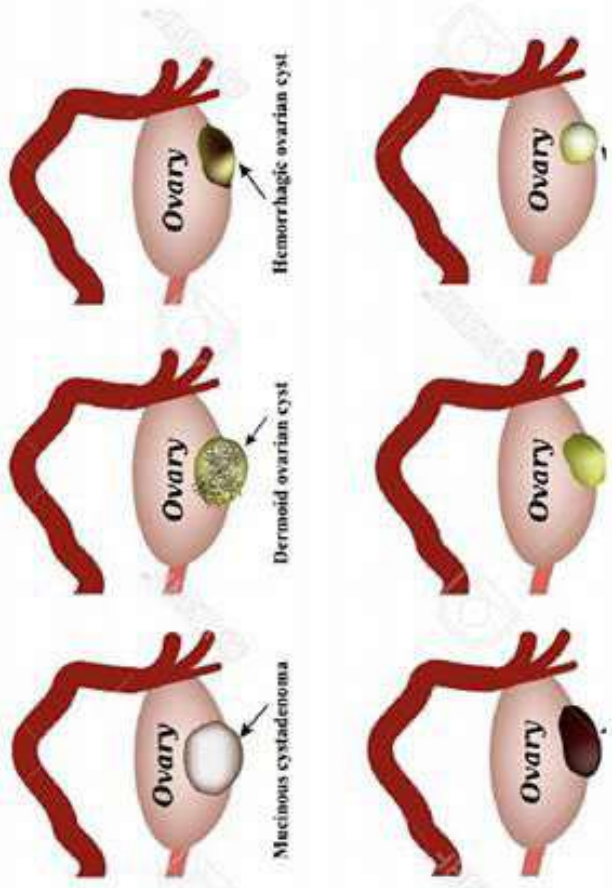
IMPRESSION: - Mammographic appearance of breast is normal for the age. Sonography for right breast reveals significant dilatations of lactiferous ducts in upper, outer and outer middle quadrant and dilated ducts show clear lumen and clear fluid content. No mass lesion is seen.

Adv: Clinical follow up and FNAC if a clinical lump is palpable.

Note :- There is no mammographic abnormality of cancer in 5% of the patients diagnosed as benign breast disease or normal by this method.

Dr. Ashok Tyagi
 Radiologist

TYPES OF OVARIAN CYSTS



17 HAEMORRHAGIC OVARIAN CYST.

Tuesday
29th Week + 19th Day

Dr. Arpit Chopra (Jain)
MD - Hematology (Postgraduate)
RADIOLOGY SUPER SPECIALITY
Special Hematology Clinics (Gandhinagar)
20th Floor, Post Box, Indore Road
20th Floor, Indore, M.P. 462018

I was diagnosed with
- ovarian cyst of 4.3x4x3.6cm
with heterogeneous internal
- echoes Haemorrhagic cyst.
When other doctors suggested
me for the operation.

- Then my uncle suggested me to
consult with Dr. Arpit Chopra
and within 20 DAYS,
- the cyst dissolved and now
- I am so thankful to him
that he saved me from
operation. Thanku
so much Sir.

Poornima Agrawal
7674 91 74 10
Tulsi Vihar Road,
Bhawarkuan,
Indore.

Love!

ALAG - 4
2018 08 20

Dr. Sarika Malik Ek D
Shri Sai Baba Hospital & Research Centre

ISPL Cert
DAC
CR-022-MS

Patient's Name: MISS POORNIMA DIO VDAY
Age/Sex: 22 / Female
Consultant Dr.: JYOTI
Date: 15/06/2018 / 62185

WHOLE ABDOMEN (F) SONOGRAPHY

Liver, Spleen, Pancreas are normal in size, shape & echotexture. Biliary channels are normal. C.B.D., Portal vein, major vessels are normal in calibre. Gallbladder is thin-walled with echogenic lumen.

Both kidneys are normal in size, shape & echotexture. Corticomedullary differentiation is maintained.

Both ureters are undilated.

Urinary bladder is thin-walled with echogenic lumen.

Uterus is anteverted size of uterus 7.4 x 3.6 x 3.2 cms. Myometrium is homogeneous in echotexture.

Endometrial thickness is 6 mm.

Right ovary is normal in size.

Left ovary shows a cyst of size 4.3 x 4 x 3.6 cms with heterogeneous internal echoes - ? Haemorrhagic / ? Endometriotic cyst.

No obvious lymphadenopathy.

Mild free fluid in POD.

ADV.: Follow up.

Dr. Danish Qureshi
MD, (RD)

All Imaging studies have technical and biological limitations. Please consider clinically as well as with other investigations findings. A review should be provided in case of discrepancy. This report is not valid for medico-legal purpose.

CHHATRI BAGH INDORE ☎ : 0731-2341790, 2343772

Dr. Sarika Malik Ek D
Shri Sai Baba Hospital & Research Centre

ISPL Cert
DAC
CR-022-MS

Patient's Name: MISS PUJUMA AGRAWAL
Age/Sex: 21 / Female
Consultant Dr.: ARPIT CHOPRA
Date: 16/07/2018 / 69368

WHOLE ABDOMEN (F) SONOGRAPHY

Liver, Spleen (8.7 cms), Pancreas are normal in size, shape & echotexture. Biliary channels are normal. C.B.D., Portal vein, major vessels are normal in calibre. Gallbladder is thin-walled with echogenic lumen.

Both kidneys are normal in size, shape & echotexture. Corticomedullary differentiation is maintained with compact central sinus echoes.

Size of R.K. 9.7 cms. in long axis.

Size of L.K. 9.2 cms. in long axis.

Both ureters are undilated.

Urinary bladder is thin-walled with echogenic lumen.

Uterus is anteverted size of uterus 6.8 x 2.9 x 3.5 cms. Myometrium is homogeneous in echotexture. No focal lesion seen.

Endometrial strip is 9.5 mm thick.

Both ovaries are normal in size & echotexture.

No adnexal pathology seen.

No ascites. No obvious lymphadenopathy.

RIF is clear.

IMPRESSION: No significant abnormality detected.

Dr. Swati Bhide
MD, (RD)

All Imaging studies have technical and biological limitations. Please consider clinically as well as with other investigations findings. A review should be provided in case of discrepancy. This report is not valid for medico-legal purpose.

CHHATRI BAGH INDORE ☎ : 0731-2341790, 2343772

Nonalcoholic fatty liver disease

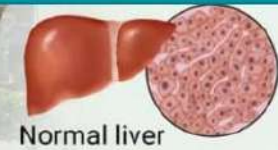
Also called: NAFLD



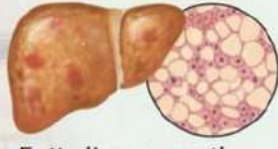
ABOUT

SYMPTOMS

TREATMENTS



Normal liver



Fatty liver: growth of fat cells

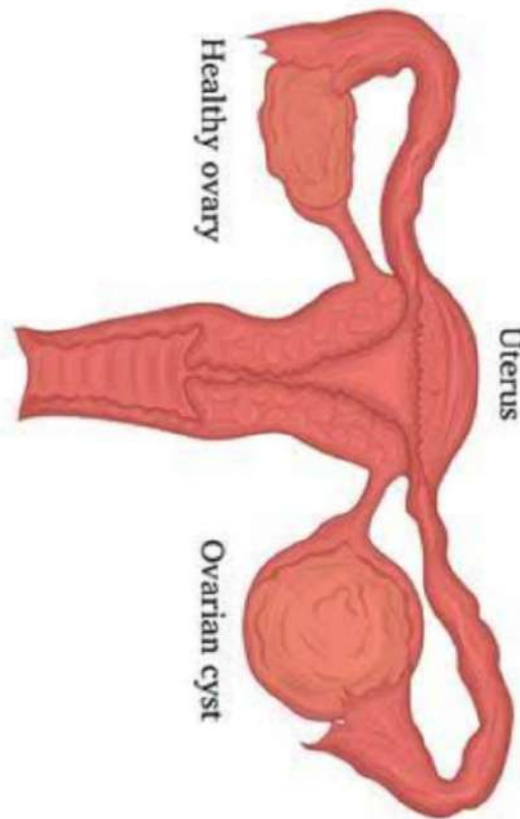
The accumulation of liver fat in people who drink little or no alcohol.

Very common

More than 10 million cases per year (India)



Treatment can help, but this condition can't be cured



Ovarian cyst

SODANI DIAGNOSTIC CLINIC
 ISO : 9001 : 2008
 MD. L.G.-I, Maya Centre, Opp. Basket Ball Club, 16/1, Race Course Road, Indore (M.P.) ☎ 0731-483-4281

Patient's Name : Mrs. Maya Rawley
 Age : 38 Years / FEMALE
 Dr. Chopra Arpit Jain MD(HOMEO)
 Visit Id : 1018038428
 Reg Date : 08/05/2018
 Reported : 08/05/2018 13:54

WHOLE ABDOMEN SONOGRAPHY

Hepatic contour is smooth & span is normal. Parenchymal echoes are high. No focal lesion is seen. Intrahepatic biliary radicles are undilated.

Gall bladder is normally distended. Walls are thin. No sludge & calculi seen. No peri GB collection is noted.

Portal vein & CBD are normal in caliber. Pancreas is normal in shape & size. Parenchymal echoes are normal. Pancreatic duct is undilated.

Spleen is normal. No focal lesion seen.

Both kidneys are normal in position & size. Right kidney is 9.5 x 3.5 cm & left is 9.5 x 4.2 cm in size. Cortical echoes are normal. Pelvicalyceal system is undilated.

Both ureters are undilated. No calculi seen at PUJ & UVJ.

Urinary bladder shows normal walls & echotree lumen. No intraluminal lesion or calculi seen.

Uterus is not seen (post hysterectomy status).

Right ovary shows a 3.0 x 3.0 cm sized clear cyst.
 Left ovary is normal in size & measures 3.5 x 2.3 cm.

No free fluid seen in cul-de-sac.
 No significant Ascites. No pleural effusion.
 No significant bowel wall thickening / dilatation or lymphnodes are noted.

Impression:
 - Grade I fatty changes in liver.
 - Normal renal echotexture with undilated collecting system.
 - Clear cyst right ovary.

Clinical correlation / followup suggested

DR. SACHNA SODANI
 MBBS

DR. R.K. SODANI
 MBBS DMDD

Address: Maya Centre, 16/1, Race Course Road, Indore
 Tel: 08/05/2018 19:34
 e-mail: sodani@sampumadiagnostics.com • www.sampumadiagnostics.com

ANCHES : Indore • Ujjain • Dewas • Sanwer • Khandwa • Kargone • Badwani • Dhar • Mhow • Shujapur
 INCHES : Indore • Ujjain • Dewas • Sanwer • Khandwa • Kargone • Badwani • Dhar • Mhow • Shujapur

apoorva
 DIGITAL X-RAYS

DIGITAL MAMOGRAPHY • DIGITAL O.P.G.
 DIGITAL CEPHALOGRAM • SONOGRAPHY
 3D COLOUR DOPPLER • ECHO CARDIOGRAPHY

MS. MAYA RAWLEY
 DR. JAIN CHOPRA ARPIT, BHMS MD (HOMEOPATHY)

Dr. Sudhir Sharma
 M.B.B.S., M.D.

Dr. Mohini Sharma
 M.B.B.S.

CONSULTANT RADIOLOGIST & ULTRASONOLOGIST

Near Agrasen Chauraha & Morri Sarees, Sapra-Sangeeta Main Road, Indore-452 001 (M.P.) Phone : 0731-2404488, 4094488

39 Years
 21.Sep.2018

USG WHOLE ABDOMEN

Liver is of normal size (10.6 cm). Its contour is smooth. Parenchyma reveals normal homogeneous echotexture. No cystic or solid mass pathology. No IHBRD / IHPRD. CBD & PV are normal in calibre.

Gallbladder is thin walled. Its content are clear. Fat planes in the peri-cholecystic region are preserved.

Pancreas & Spleen (9.3 cm) are of normal size revealing their normal echo-structure.

Both renals are of normal size and shape. Their parenchymal echo texture is normal. CMD is well maintained. No pelvicalyceal dilatation or calculus. Ureters are undilated. Rt kidney - 9.6 x 3.7 cm & Lt kidney - 9.5 x 5.4 cm.

IVC & Abdominal aorta are normal. No lymphadenopathy or ascites. No thick walled bowel loop. Bilaterally the iliac fossae are clear.

Urinary bladder is thin walled. No vesical calculus. Both vesico-ureteric junctions are clear.

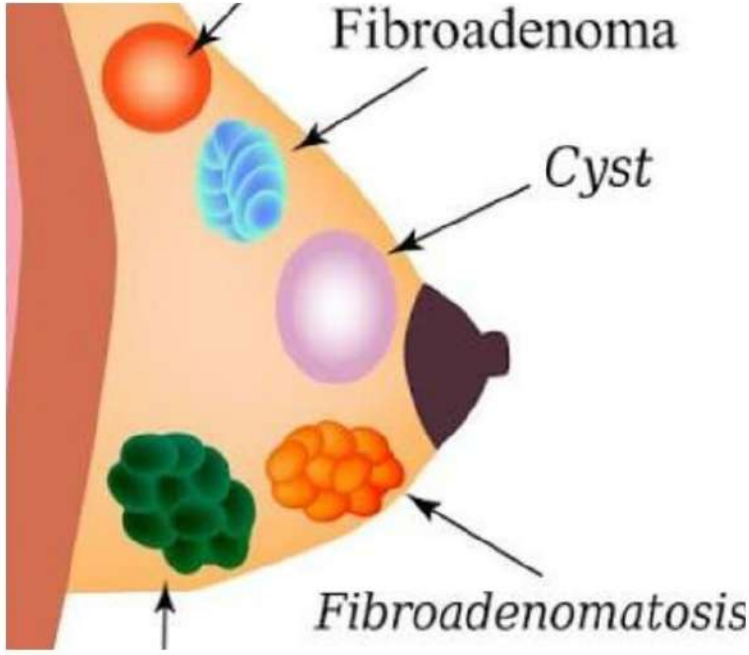
Uterus is not visualized - Surgically resected. Both ovaries are not identified.

IMPRESSION: - No significant abnormality is detected.

Dr. Sudhir Sharma
 Senior Radiologist
 Regd. No MP- 2222

Dr. Apoorva Sharma
 Radiologist
 Regd. No. MP- 2863
 FMP UK (ID) - 106467
 Fellow in fetal medicine (London)
 Fellow in MSK (Hinduja)

Dr. Necty Sharma
 Radiologist
 Regd. No. MP- 2161
 YMF UK (ID) - 171540
 Fellow in mammography (TATA)
 Fellow in fetal medicine (London)



Fibroadenoma

ABOUT SYMPTOMS TREATMENTS

A non-cancerous breast tumour that most often occurs in young women.

Common

More than 1 million cases per year (India)

- Requires a medical diagnosis
- Lab tests or imaging often required
- Chronic: can last for years or be lifelong

Consult a doctor for medical advice

आरोग्य सुपर सोलिसिटी मॉडर्न होमोपैथिक सिस्टम (आरोग्यसुपर)

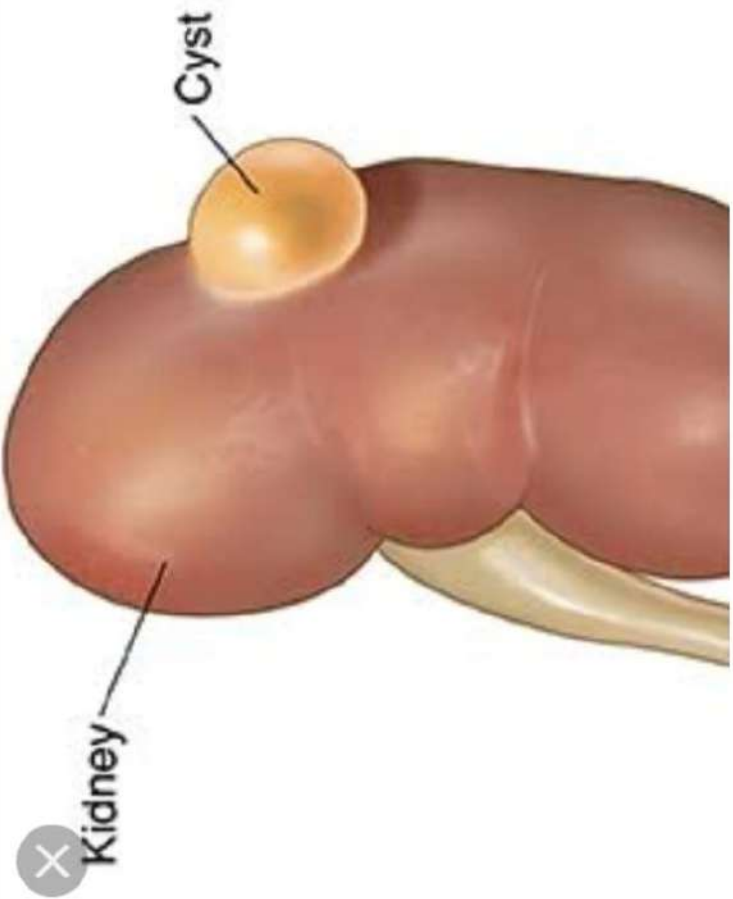




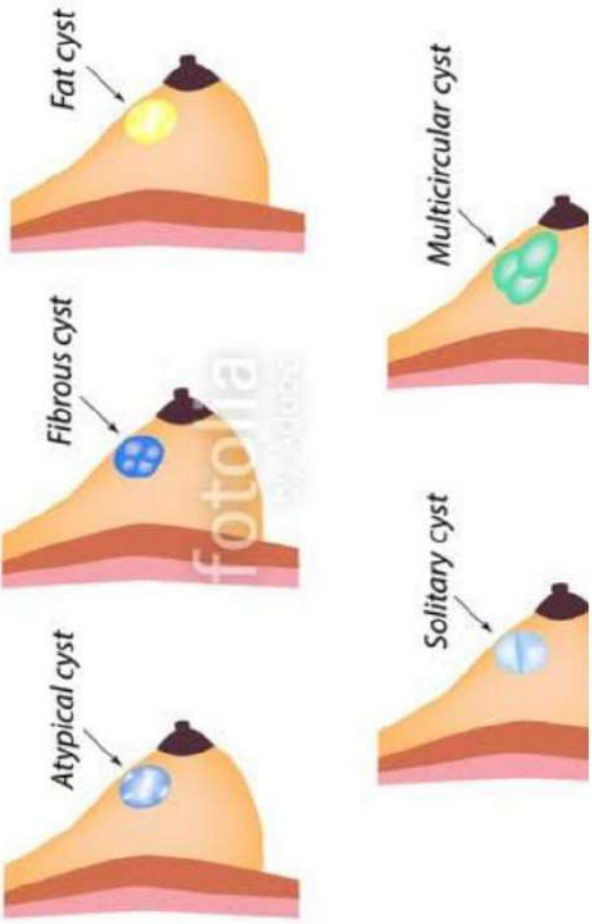
31, भागतजी मार्केट (डी.डी.)
 465001 (उज्जैन)

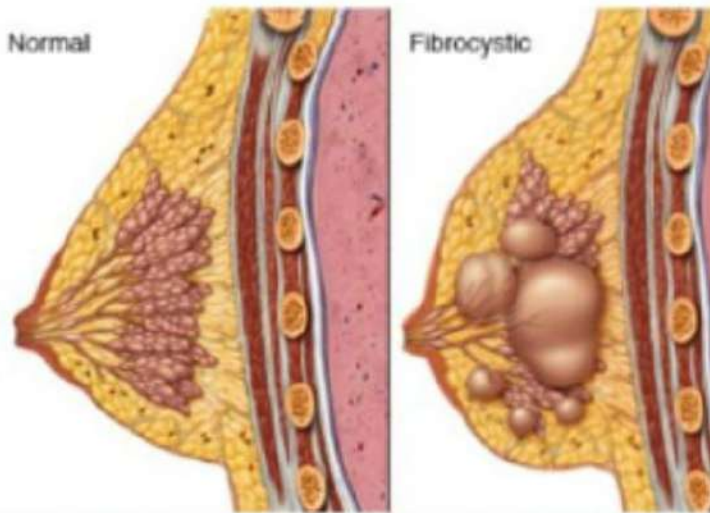
Phone: 0731-4077076, 2527237
 Mobile: 97330 52237, 97108-37237
 Website: www.homopathyindia.com

Complete Early Self-Test
 1. आरोग्य सुपर सोलिसिटी मॉडर्न होमोपैथिक सिस्टम (आरोग्यसुपर) का उपयोग करने से पहले आपको अपने डॉक्टर से परामर्श करना चाहिए।
 2. यह टेस्ट केवल एक संकेतक है और इसे निश्चय के लिए नहीं माना जा सकता है।
 3. यदि आपको कोई भी लक्षण है, तो आपको तुरंत डॉक्टर से मिलना चाहिए।
 4. इस टेस्ट का उपयोग केवल एक संकेतक के रूप में करना चाहिए।
 5. यदि आपको कोई भी लक्षण है, तो आपको तुरंत डॉक्टर से मिलना चाहिए।

Handwritten notes:
 Fibroadenoma
 ममोग्राफी
 31/09/18
 31/10/18
 31/11/18
 31/12/18
 31/01/19
 31/02/19
 31/03/19
 31/04/19
 31/05/19
 31/06/19
 31/07/19
 31/08/19
 31/09/19
 31/10/19
 31/11/19
 31/12/19
 31/01/20
 31/02/20
 31/03/20
 31/04/20
 31/05/20
 31/06/20
 31/07/20
 31/08/20
 31/09/20
 31/10/20
 31/11/20
 31/12/20
 31/01/21
 31/02/21
 31/03/21
 31/04/21
 31/05/21
 31/06/21
 31/07/21
 31/08/21
 31/09/21
 31/10/21
 31/11/21
 31/12/21
 31/01/22
 31/02/22
 31/03/22
 31/04/22
 31/05/22
 31/06/22
 31/07/22
 31/08/22
 31/09/22
 31/10/22
 31/11/22
 31/12/22
 31/01/23
 31/02/23
 31/03/23
 31/04/23
 31/05/23
 31/06/23
 31/07/23
 31/08/23
 31/09/23
 31/10/23
 31/11/23
 31/12/23
 31/01/24
 31/02/24
 31/03/24
 31/04/24
 31/05/24
 31/06/24
 31/07/24
 31/08/24
 31/09/24
 31/10/24
 31/11/24
 31/12/24
 31/01/25
 31/02/25
 31/03/25
 31/04/25
 31/05/25
 31/06/25
 31/07/25
 31/08/25
 31/09/25
 31/10/25
 31/11/25
 31/12/25
 31/01/26
 31/02/26
 31/03/26
 31/04/26
 31/05/26
 31/06/26
 31/07/26
 31/08/26
 31/09/26
 31/10/26
 31/11/26
 31/12/26
 31/01/27
 31/02/27
 31/03/27
 31/04/27
 31/05/27
 31/06/27
 31/07/27
 31/08/27
 31/09/27
 31/10/27
 31/11/27
 31/12/27
 31/01/28
 31/02/28
 31/03/28
 31/04/28
 31/05/28
 31/06/28
 31/07/28
 31/08/28
 31/09/28
 31/10/28
 31/11/28
 31/12/28
 31/01/29
 31/02/29
 31/03/29
 31/04/29
 31/05/29
 31/06/29
 31/07/29
 31/08/29
 31/09/29
 31/10/29
 31/11/29
 31/12/29
 31/01/30
 31/02/30
 31/03/30
 31/04/30
 31/05/30
 31/06/30
 31/07/30
 31/08/30
 31/09/30
 31/10/30
 31/11/30
 31/12/30
 31/01/31
 31/02/31
 31/03/31
 31/04/31
 31/05/31
 31/06/31
 31/07/31
 31/08/31
 31/09/31
 31/10/31
 31/11/31
 31/12/31
 31/01/32
 31/02/32
 31/03/32
 31/04/32
 31/05/32
 31/06/32
 31/07/32
 31/08/32
 31/09/32
 31/10/32
 31/11/32
 31/12/32
 31/01/33
 31/02/33
 31/03/33
 31/04/33
 31/05/33
 31/06/33
 31/07/33
 31/08/33
 31/09/33
 31/10/33
 31/11/33
 31/12/33
 31/01/34
 31/02/34
 31/03/34
 31/04/34
 31/05/34
 31/06/34
 31/07/34
 31/08/34
 31/09/34
 31/10/34
 31/11/34
 31/12/34
 31/01/35
 31/02/35
 31/03/35
 31/04/35
 31/05/35
 31/06/35
 31/07/35
 31/08/35
 31/09/35
 31/10/35
 31/11/35
 31/12/35
 31/01/36
 31/02/36
 31/03/36
 31/04/36
 31/05/36
 31/06/36
 31/07/36
 31/08/36
 31/09/36
 31/10/36
 31/11/36
 31/12/36
 31/01/37
 31/02/37
 31/03/37
 31/04/37
 31/05/37
 31/06/37
 31/07/37
 31/08/37
 31/09/37
 31/10/37
 31/11/37
 31/12/37
 31/01/38
 31/02/38
 31/03/38
 31/04/38
 31/05/38
 31/06/38
 31/07/38
 31/08/38
 31/09/38
 31/10/38
 31/11/38
 31/12/38
 31/01/39
 31/02/39
 31/03/39
 31/04/39
 31/05/39
 31/06/39
 31/07/39
 31/08/39
 31/09/39
 31/10/39
 31/11/39
 31/12/39
 31/01/40
 31/02/40
 31/03/40
 31/04/40
 31/05/40
 31/06/40
 31/07/40
 31/08/40
 31/09/40
 31/10/40
 31/11/40
 31/12/40
 31/01/41
 31/02/41
 31/03/41
 31/04/41
 31/05/41
 31/06/41
 31/07/41
 31/08/41
 31/09/41
 31/10/41
 31/11/41
 31/12/41
 31/01/42
 31/02/42
 31/03/42
 31/04/42
 31/05/42
 31/06/42
 31/07/42
 31/08/42
 31/09/42
 31/10/42
 31/11/42
 31/12/42
 31/01/43
 31/02/43
 31/03/43
 31/04/43
 31/05/43
 31/06/43
 31/07/43
 31/08/43
 31/09/43
 31/10/43
 31/11/43
 31/12/43
 31/01/44
 31/02/44
 31/03/44
 31/04/44
 31/05/44
 31/06/44
 31/07/44
 31/08/44
 31/09/44
 31/10/44
 31/11/44
 31/12/44
 31/01/45
 31/02/45
 31/03/45
 31/04/45
 31/05/45
 31/06/45
 31/07/45
 31/08/45
 31/09/45
 31/10/45
 31/11/45
 31/12/45
 31/01/46
 31/02/46
 31/03/46
 31/04/46
 31/05/46
 31/06/46
 31/07/46
 31/08/46
 31/09/46
 31/10/46
 31/11/46
 31/12/46
 31/01/47
 31/02/47
 31/03/47
 31/04/47
 31/05/47
 31/06/47
 31/07/47
 31/08/47
 31/09/47
 31/10/47
 31/11/47
 31/12/47
 31/01/48
 31/02/48
 31/03/48
 31/04/48
 31/05/48
 31/06/48
 31/07/48
 31/08/48
 31/09/48
 31/10/48
 31/11/48
 31/12/48
 31/01/49
 31/02/49
 31/03/49
 31/04/49
 31/05/49
 31/06/49
 31/07/49
 31/08/49
 31/09/49
 31/10/49
 31/11/49
 31/12/49
 31/01/50
 31/02/50
 31/03/50
 31/04/50
 31/05/50
 31/06/50
 31/07/50
 31/08/50
 31/09/50
 31/10/50
 31/11/50
 31/12/50
 31/01/51
 31/02/51
 31/03/51
 31/04/51
 31/05/51
 31/06/51
 31/07/51
 31/08/51
 31/09/51
 31/10/51
 31/11/51
 31/12/51
 31/01/52
 31/02/52
 31/03/52
 31/04/52
 31/05/52
 31/06/52
 31/07/52
 31/08/52
 31/09/52
 31/10/52
 31/11/52
 31/12/52
 31/01/53
 31/02/53
 31/03/53
 31/04/53
 31/05/53
 31/06/53
 31/07/53
 31/08/53
 31/09/53
 31/10/53
 31/11/53
 31/12/53
 31/01/54
 31/02/54
 31/03/54
 31/04/54
 31/05/54
 31/06/54
 31/07/54
 31/08/54
 31/09/54
 31/10/54
 31/11/54
 31/12/54
 31/01/55
 31/02/55
 31/03/55
 31/04/55
 31/05/55
 31/06/55
 31/07/55
 31/08/55
 31/09/55
 31/10/55
 31/11/55
 31/12/55
 31/01/56
 31/02/56
 31/03/56
 31/04/56
 31/05/56
 31/06/56
 31/07/56
 31/08/56
 31/09/56
 31/10/56
 31/11/56
 31/12/56
 31/01/57
 31/02/57
 31/03/57
 31/04/57
 31/05/57
 31/06/57
 31/07/57
 31/08/57
 31/09/57
 31/10/57
 31/11/57
 31/12/57
 31/01/58
 31/02/58
 31/03/58
 31/04/58
 31/05/58
 31/06/58
 31/07/58
 31/08/58
 31/09/58
 31/10/58
 31/11/58
 31/12/58
 31/01/59
 31/02/59
 31/03/59
 31/04/59
 31/05/59
 31/06/59
 31/07/59
 31/08/59
 31/09/59
 31/10/59
 31/11/59
 31/12/59
 31/01/60
 31/02/60
 31/03/60
 31/04/60
 31/05/60
 31/06/60
 31/07/60
 31/08/60
 31/09/60
 31/10/60
 31/11/60
 31/12/60
 31/01/61
 31/02/61
 31/03/61
 31/04/61
 31/05/61
 31/06/61
 31/07/61
 31/08/61
 31/09/61
 31/10/61
 31/11/61
 31/12/61
 31/01/62
 31/02/62
 31/03/62
 31/04/62
 31/05/62
 31/06/62
 31/07/62
 31/08/62
 31/09/62
 31/10/62
 31/11/62
 31/12/62
 31/01/63
 31/02/63
 31/03/63
 31/04/63
 31/05/63
 31/06/63
 31/07/63
 31/08/63
 31/09/63
 31/10/63
 31/11/63
 31/12/63
 31/01/64
 31/02/64
 31/03/64
 31/04/64
 31/05/64
 31/06/64
 31/07/64
 31/08/64
 31/09/64
 31/10/64
 31/11/64
 31/12/64
 31/01/65
 31/02/65
 31/03/65
 31/04/65
 31/05/65
 31/06/65
 31/07/65
 31/08/65
 31/09/65
 31/10/65
 31/11/65
 31/12/65
 31/01/66
 31/02/66
 31/03/66
 31/04/66
 31/05/66
 31/06/66
 31/07/66
 31/08/66
 31/09/66
 31/10/66
 31/11/66
 31/12/66
 31/01/67
 31/02/67
 31/03/67
 31/04/67
 31/05/67
 31/06/67
 31/07/67
 31/08/67
 31/09/67
 31/10/67
 31/11/67
 31/12/67
 31/01/68
 31/02/68
 31/03/68
 31/04/68
 31/05/68
 31/06/68
 31/07/68
 31/08/68
 31/09/68
 31/10/68
 31/11/68
 31/12/68
 31/01/69
 31/02/69
 31/03/69
 31/04/69
 31/05/69
 31/06/69
 31/07/69
 31/08/69
 31/09/69
 31/10/69
 31/11/69
 31/12/69
 31/01/70
 31/02/70
 31/03/70
 31/04/70
 31/05/70
 31/06/70
 31/07/70
 31/08/70
 31/09/70
 31/10/70
 31/11/70
 31/12/70
 31/01/71
 31/02/71
 31/03/71
 31/04/71
 31/05/71
 31/06/71
 31/07/71
 31/08/71
 31/09/71
 31/10/71
 31/11/71
 31/12/71
 31/01/72
 31/02/72
 31/03/72
 31/04/72
 31/05/72
 31/06/72
 31/07/72
 31/08/72
 31/09/72
 31/10/72
 31/11/72
 31/12/72
 31/01/73
 31/02/73
 31/03/73
 31/04/73
 31/05/73
 31/06/73
 31/07/73
 31/08/73
 31/09/73
 31/10/73
 31/11/73
 31/12/73
 31/01/74
 31/02/74
 31/03/74
 31/04/74
 31/05/74
 31/06/74
 31/07/74
 31/08/74
 31/09/74
 31/10/74
 31/11/74
 31/12/74
 31/01/75
 31/02/75
 31/03/75
 31/04/75
 31/05/75
 31/06/75
 31/07/75
 31/08/75
 31/09/75
 31/10/75
 31/11/75
 31/12/75
 31/01/76
 31/02/76
 31/03/76
 31/04/76
 31/05/76
 31/06/76
 31/07/76
 31/08/76
 31/09/76
 31/10/76
 31/11/76
 31/12/76
 31/01/77
 31/02/77
 31/03/77
 31/04/77
 31/05/77
 31/06/77
 31/07/77
 31/08/77
 31/09/77
 31/10/77
 31/11/77
 31/12/77
 31/01/78
 31/02/78
 31/03/78
 31/04/78
 31/05/78
 31/06/78
 31/07/78
 31/08/78
 31/09/78
 31/10/78
 31/11/78
 31/12/78
 31/01/79
 31/02/79
 31/03/79
 31/04/79
 31/05/79
 31/06/79
 31/07/79
 31/08/79
 31/09/79
 31/10/79
 31/11/79
 31/12/79
 31/01/80
 31/02/80
 31/03/80
 31/04/80
 31/05/80
 31/06/80
 31/07/80
 31/08/80
 31/09/80
 31/10/80
 31/11/80
 31/12/80
 31/01/81
 31/02/81
 31/03/81
 31/04/81
 31/05/81
 31/06/81
 31/07/81
 31/08/81
 31/09/81
 31/10/81
 31/11/81
 31/12/81
 31/01/82
 31/02/82
 31/03/82
 31/04/82
 31/05/82
 31/06/82
 31/07/82
 31/08/82
 31/09/82
 31/10/82
 31/11/82
 31/12/82
 31/01/83
 31/02/83
 31/03/83
 31/04/83
 31/05/83
 31/06/83
 31/07/83
 31/08/83
 31/09/83
 31/10/83
 31/11/83
 31/12/83
 31/01/84
 31/02/84
 31/03/84
 31/04/84
 31/05/84
 31/06/84
 31/07/84
 31/08/84
 31/09/84
 31/10/84
 31/11/84
 31/12/84
 31/01/85
 31/02/85
 31/03/85
 31/04/85
 31/05/85
 31/06/85
 31/07/85
 31/08/85
 31/09/85
 31/10/85
 31/11/85
 31/12/85
 31/01/86
 31/02/86
 31/03/86
 31/04/86
 31/05/86
 31/06/86
 31/07/86
 31/08/86
 31/09/86
 31/10/86
 31/11/86
 31/12/86
 31/01/87
 31/02/87
 31/03/87
 31/04/87
 31/05/87
 31/06/87
 31/07/87
 31/08/87
 31/09/87
 31/10/87
 31/11/87
 31/12/87
 31/01/88
 31/02/88
 31/03/88
 31/04/88
 31/05/88
 31/06/88
 31/07/88
 31/08/88
 31/09/88
 31/10/88
 31/11/88
 31/12/88
 31/01/89
 31/02/89
 31/03/89
 31/04/89
 31/05/89
 31/06/89
 31/07/89
 31/08/89
 31/09/89
 31/10/89
 31/11/89
 31/12/89
 31/01/90
 31/02/90
 31/03/90
 31/04/90
 31/05/90
 31/06/90
 31/07/90
 31/08/90
 31/09/90
 31/10/90
 31/11/90
 31/12/90
 31/01/91
 31/02/91
 31/03/91
 31/04/91
 31/05/91
 31/06/91
 31/07/91
 31/08/91
 31/09/91
 31/10/91
 31/11/91
 31/12/91
 31/01/92
 31/02/92
 31/03/92
 31/04/92
 31/05/92
 31/06/92
 31/07/92
 31/08/92
 31/09/

TYPES OF CYSTS IN THE BREAST





© MAYO FOUNDATION FOR MEDICAL EDUCATION AND RESEARCH. ALL RIGHTS RESERVED.

Fibrocystic breast changes

Fibrocystic breast changes lead to the development of fluid-filled round or oval (cysts) and more prominent scar-like (fibrous) tissue, which can make breasts tender, lumpy or ropy.

Also called: fibrocystic breasts

TREATMENTS

SYMPTOMS

ABOUT

Non-cancerous changes that give a breast a lumpy or ropelike texture.

Very common
More than 10 million cases per year (India)

Treatment can help, but this condition can't be cured

SHIVANI AGGARWAL, 40 Y/F, Reg.No:-1811287, Date:-28/11/2018 11:20AM

MAMMOGRAPHY RIGHT SIDE

Unilateral mammogram obtained using a low radiation dose technique, CC and ML views are obtained.

RIGHT BREAST

The study reveals fibro-fatty breast parenchymal pattern.

There is evidence of asymmetrical radio-density area noted in the upper-middle quadrant of right breast.

No definite mammographically demonstrable clustered calcification seen in breast. Nipple and retroareolar area are unremarkable.

No obvious axillary lymphadenopathy seen. No evidence of skin thickening/nipple retraction seen.

CORRELATIVE BREAST SONOGRAPHY DONE

Scanning scheme used: Longitudinal, transverse, radial and an orthogonal antiradial scan plane obtained using a high resolution probe (10 MHz).

There is evidence of an irregularly outlined area of heterogeneously hypochoic echotexture, measuring approx. 2.2 x 0.7 cms, seen in the upper-middle quadrant of right breast (12 o'clock radian), underneath the outer margin of areola. It shows no significant intralobular vascularity. There is suggestion of heterogenous thick fluid echogenicity in the centre of the lesion.

Right breast parenchymal echogenicity appears normal (as expected for patient's age). No evidence of any architectural distortion seen.

IMPRESSION:-

- IRREGULARLY OUTLINED RIGHT BREAST LESION ? THICK COLLECTION (? INFECTIVE).

Advise: Clinical correlation, follow up 3 monthly and HPE if further required.

JEHA HOSP

Agar/Sex : 41 Yrs/Female
Order Date : 26/12/2018 13:26
Report Date : 26/12/2018 15:42
Ordered By : Dr. Anupama Mane

BREAST ULTRASOUND

High resolution ultrasonography of right breast is performed.

Parenchyma: No solid /cystic masses noted. Normal architecture. No obvious calcifications

Skin and Subcutaneous tissues appear normal.

Nipple and retroareolar tissue appear normal.

Ducts: Two thick walled ducts with internal echoes are seen at 11- 12 o'clock position periareolar region. These are seen extending towards nipple. Total extent measures 3.6 cm in length and 0.7 cm in thickness. No obvious solid lesion seen.

Retro mammary zone and pectoral muscles appear normal.

Axilla: No suspicious lymph nodes seen.

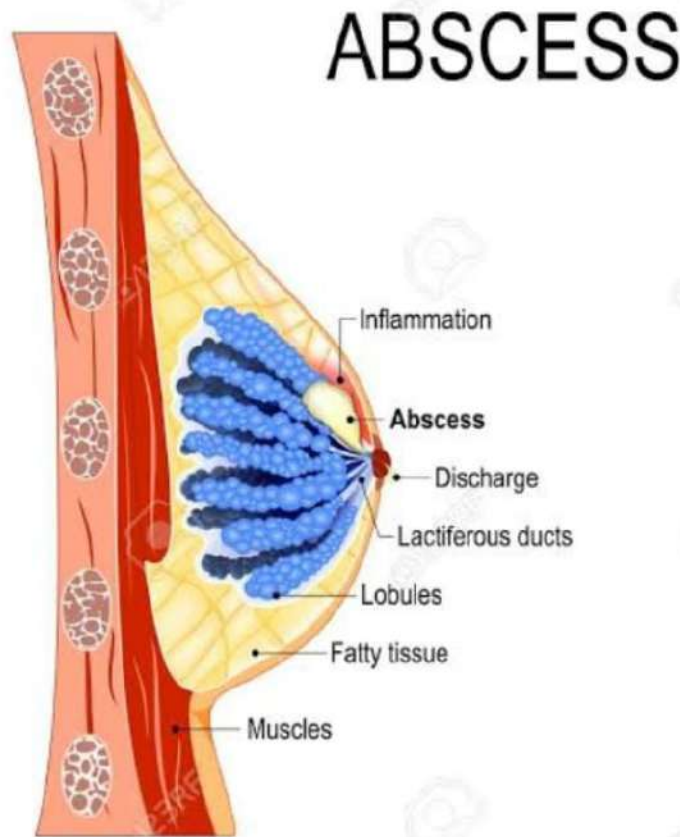
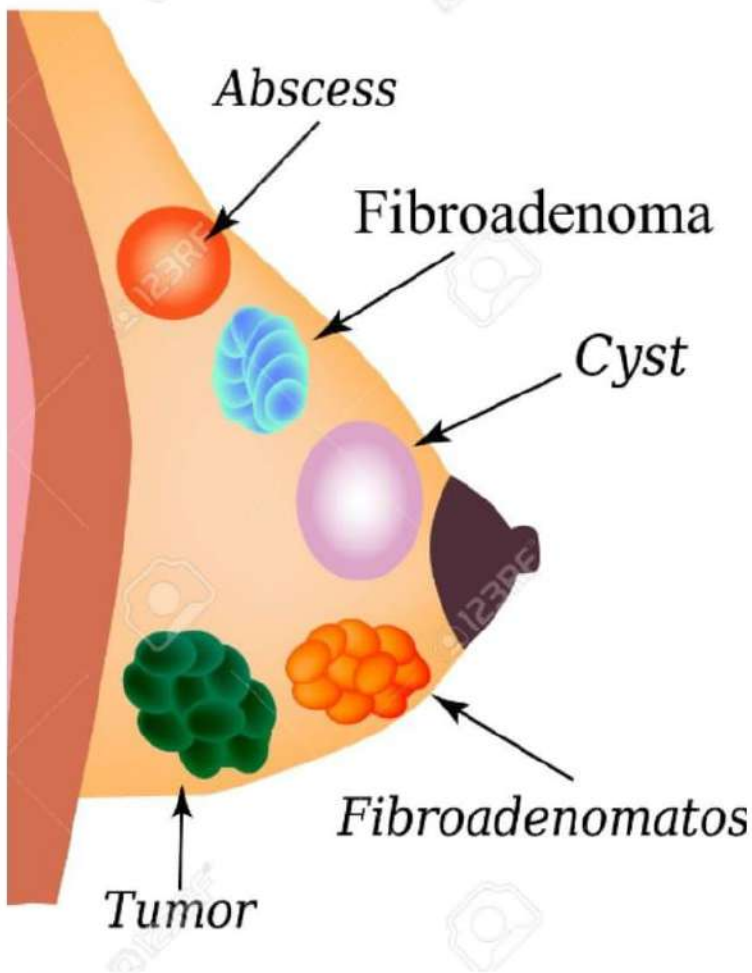
IMP

Two thick walled ducts with internal echoes at 11- 12 o'clock position periareolar region. These are seen extending towards nipple. No obvious solid lesion seen.

Dr. Shilpa Kajale
DNB, DMR (RADIOLOGY)
CONSULTANT

Order By : E00434

-----End Of Report-----



SARAL
DIAGNOSTIC & IMAGING CENTER

NAME: MRS. NASREEN, 35Y/F
REF/BY: DR. DIPESH YADAV
DATE: 05/12/19

ULTRASONOGRAPHY OF RIGHT BREAST

Technique
Ultrasonographic study of right breast was using high frequency linear array in various plain.

Imaging findings:-
Large fungating neoplastic growth right breast measuring 54x35mm with ulceration of overlying skin and infiltration of adjacent skin.
Enlarged axillary lymph nodes.

Dr. Chandras Prakash (MD)
Consultant Radiologist

Our Motto - "Commitment & Quality"
CHAWLA DIAGNOSTIC CENTRE
Mirza House, Opposite Thana Talalya, Kali Mandir,
Band Master Chauraha, Sultanis Road, Bhopal

Dr. Rajesh Chawla
MBBS, DNB-1
Consultant Radiologist, Sonologist,
C.T. Scan & Color Doppler Specialist

Centre of Advanced Sonography Equipped With:
• Medison-Samsung Color Doppler with ELASTOGRAPHY (First in M.P.)
• Medison-Samsung 3D/4D Most Advanced Color Doppler • Logic 400 MD-Pro with Advanced 4D software

OTHER FACILITIES:
• Transvaginal Sonography (T V S) • TRUS • Mamo-Sonograms • Cardiac Dopplers • Echo-Cardiography
• Digital X-Rays • Special Investigations (H.S.G., I.V.P., M.C.U., Barium) • OPG (Dental X-Ray) • HS-Tech Pathology

REPORT

Name: Mrs. Nasreen Age: 33yrs Sex: F
Consultant: Incharge Dr. Arpit Date: 11/02/19
Indication: OLD CASE OF RIGHT BREAST ABSCESS

MAMMO- SONOGRAPHY WITH ELASTOGRAPHY & COLOR DOPPLER RIGHT BREAST

Real time high frequency color doppler study of RIGHT Breast region reveals:

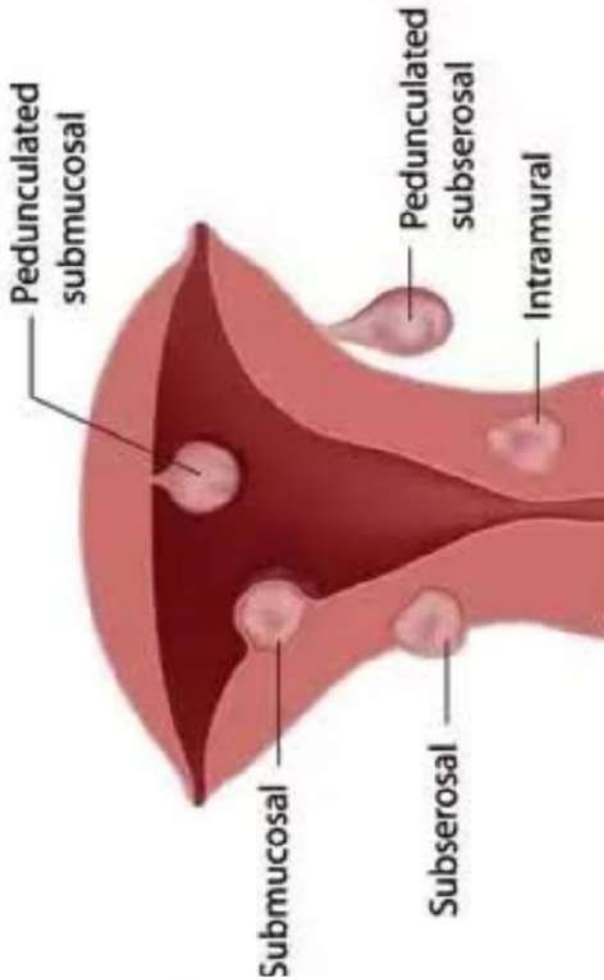
- Evidence of minimal very small hypoechoic areas seen in superior quadrant of right breast.
- Rest of breast appears to be normal.
- No abnormal ductal dilation seen.
- No evidence of any fibrosis seen.
- Evidence of multiple enlarged lymph-nodes of (2cm in sizes) seen in right axilla. They are 3 to 4 in numbers.
- No evidence of any calcification seen.

IMPRESSION:
- FINDINGS ARE SUGGESTIVE OF:-
- MINIMAL SMALL RESIDUAL ABSCESS SEEN IN SUPERIOR QUADRANT OF RIGHT BREAST WITH MULTIPLE ENLARGED LYMPH-NODES SEEN IN RIGHT AXILLA (— INFLAMMATORY ETIOLOGY)

[ADVISE-- F.N.A.C. IF REQUIRED]

Dr. Rajesh Chawla
(Consultant Radiologist)
(Reg. No 10949)

Uterine fibroids



10.00 मुझे डॉ. श्वेता जैन से सलाह मिली है कि मैं
 11.00 उताड़पी रंग कापरेसन का लेना
 12.00 था लेकिन मुझे डॉ. अमित जैन
 13.00 से होमोपैथी के अलावा करवाया
 14.00 मुझे किन माद में पूरा कापरेस होना
 15.00 तथा गडक बिल्ट गडकी अत
 16.00 मुझे कोई परेशानी नहीं है
 17.00 इसके लिये मैं डॉ. अमित जैन को
 18.00 विस्तार से सलाह देना हूँ

UTERINE FIBROID.

प्रीती जैन
 वकील प्रो-एन-एन
 मो. 9754818274

Dr. Arpit Chopra (Jain)
 M.D. HOMOEOPATHY
 Contact: 9907527914, 9713037737

Dr. Shweta Jain Sonography & Diagnostic Centre

डॉ. श्वेता जैन
 M.B.B.S., D.M.D. (Gold Medalist)
 Consultant Radiologist & Ultrasonologist
 M.: 9424456153

Ex. Consultant: • ASIAN Heart Institute, Mumbai
 • BMRC, Bhopal
 Worked at: • Naravati Hospital, Mumbai

Expertise: Conventional (2D), 3D, 4D (Target Scan) USG, Colour Doppler, Breast & Transvaginal Sonography

Pat Name Mrs. Preeti Jain Age: 46 Yrs/ Female
 Ref. by: Dr. Mrs. Archana Dubey Date: 04.02.2019

USG WHOLE ABDOMEN/TVS

Liver is normal in size normal in shape and outline, & shows normal echotexture. No focal lesion seen. Intra and extra hepatic biliary radicals are not dilated. Portal vein & CBD is normal in caliber.

Gall bladder - shows clear lumen with normal wall thickness
 Spleen is normal in size and normal in shape and echotexture
 Pancreas is normal in size and echogenicity.

Both kidneys are normal in size, renal parenchymal echotexture homogenous. Cortico-medullary differentiation is maintained. No e/o hydronephrosis, calculi, scarring.
 Right Kidney: 9cm x 4.7cm Left Kidney: 9.9cm x 3.8cm

UB-wall normal with clear lumen

Uterus is anteverted, bulky in size (9.1cm x 4.4cm x 5.8cm) normal in shape. Myometrial echos are heterogenous, App 12mmx6mm & app 15mmx6mm size intramural fibroid at left lateral wall of uterus. Endometrium - 10mm (echogenic)

Both ovaries are normal in size, normal in shape & echotexture.
 RTO: 2.9cmx2cmx1.6cm (app5.2cc) LTO: 2.82x1.6cm (app4.8cc)

No e/o pleural effusion/ascites.

- Impression- Bulky uterus with mild diffuse adenomyosis.
- App 12mmx6mm & app 15mmx6mm size intramural fibroid at left lateral wall of uterus.
- Both ovaries are close to uterus.
- Mild free fluid in POD with raised adnexal vascularity/PID.
- Cervix heterogenous with nabothian cyst.

Dr. Shweta Jain
 M.B.B.S., D.M.D.
 Address: Survey Residency, Main Road Opposite to Badwani Plaza, 5/1 Old Pratisia, Indore-1.
 Clinic Ph.: 0731-4021469 / 91740 77710

समर्पण
 Imaging & Diagnostics

12-20, Ground Floor, Yashwant Plaza,
 Opp. Railway Station, Indore (M.P.)
 0731- 4068123, 4967633, 88899-33684
 samarpanimagingolutions@gmail.com
 www.samarpanimaging.com

Pt. Name: MRS. PREETI JAIN
 Ref. By: DR. ARPIT CHOPRA
 Age/Sex: 47 Years /Female
 Date: 06/May/2019

WHOLE ABDOMEN SONOGRAPHY

Hepatic contour is smooth & span (11.4 cm) is normal. Parenchymal echotexture is normal. No focal lesion is seen. Intrahepatic biliary radicals are undilated.

Gall bladder is normally distended. Walls are thin. No sludge or calculus is seen.
 CBD & Portal vein are normal in caliber.

Pancreas is normal in shape & size. Parenchymal echos are normal. Pancreatic duct is undilated.

Spleen is normal (7.7 cm). No focal lesion seen.

Both kidneys are normal in position & size. Renal contour is smooth. Cortical echos are normal. Pelvic/lyceal system is undilated.
 Right kidney is 9.3 x 3.8 cm and left kidney is 9.5 x 3.5 cm in size.

Urinary bladder shows normal walls & echo free lumen.
 Pre-void urine = 287 ml (approx), post-void residual urine = Nil.

Uterus is anteverted & normal in size. It measures 7.8 x 4.4 x 5.0 cm.
 No focal myometrial lesion seen. Endometrial is measuring 8 mm.

Nabothian cyst of size 4.7 mm seen lower cervix region.

Dominant follicle of size 15 x 13 mm seen in left ovary.

Right ovary appears normal measuring 1.9 x 1.0 cm.

No significant retroperitoneal lymphadenopathy seen.

No free fluid seen in peritoneal cavity. The dependent pleural recess are normal.

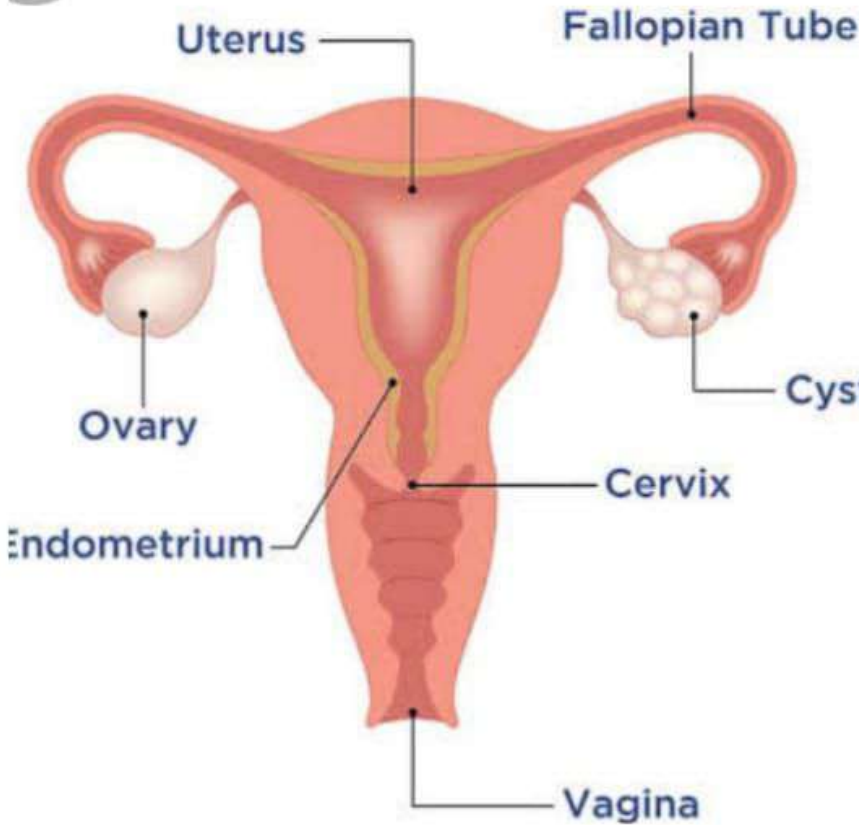
IMPRESSION:- ESSENTIALLY NORMAL USG FINDINGS.

Clinical Correlation.

DR. KMIT KUMAR TIWARI,
 MD, RADIOLOGIST
 Reg. No. MP-11308

SAMARPAN IMAGING SOLUTIONS
 DIGITAL X-RAY | 3D/4D SONOGRAPHY
 DIGITAL MAMMOGRAPHY | ECHOCARDIOGRAPHY
 4K SLICE BY SCAN (HIGH QUALITY)

TYPES OF OVARIAN CYSTS



-  Corpus Luteum
-  Follicular Cyst
-  Endometrioma
-  Dermoid Cyst
-  Paraovarian Cyst
-  Hemorrhagic Cyst
-  Possibly Malignant

Hemorrhagic Ovarian Cyst
 March 2016
 I was diagnosed with a hemorrhagic ovarian cyst. The doctor said it was a functional cyst and would go away on its own. I was prescribed painkillers and told to rest. After 2 weeks, the pain subsided. I went back to the doctor for a follow-up. He said the cyst had resolved. I am grateful to Dr. Arpit Chopra for his expertise and care.

Dr. Arpit Chopra (Jain)
 M.D. (Gynecology)
 M.Ch. (Gynecology)
 FRCOG (UK)
 FRCR (UK)
 FRCR (Ireland)
 FRCR (Singapore)
 FRCR (Australia)
 FRCR (New Zealand)
 FRCR (Canada)
 FRCR (USA)
 FRCR (Japan)
 FRCR (South Korea)
 FRCR (Taiwan)
 FRCR (Thailand)
 FRCR (Vietnam)
 FRCR (Philippines)
 FRCR (Malaysia)
 FRCR (Indonesia)
 FRCR (Singapore)
 FRCR (Australia)
 FRCR (New Zealand)
 FRCR (Canada)
 FRCR (USA)
 FRCR (Japan)
 FRCR (South Korea)
 FRCR (Taiwan)
 FRCR (Thailand)
 FRCR (Vietnam)
 FRCR (Philippines)
 FRCR (Malaysia)
 FRCR (Indonesia)
 FRCR (Singapore)

Ulcerative Colitis
 Monday 08
 I have been suffering from ulcerative colitis for several years. The symptoms are chronic diarrhea with blood and mucus, abdominal pain, and weight loss. I have tried various treatments, but nothing has worked. I was referred to Dr. Arpit Chopra. He diagnosed me with ulcerative colitis and started me on medication. After a few weeks, my symptoms improved significantly. I am very grateful to Dr. Chopra for his expertise and care.

Dr. Arpit Chopra (Jain)
 M.D. (Gynecology)
 M.Ch. (Gynecology)
 FRCOG (UK)
 FRCR (UK)
 FRCR (Ireland)
 FRCR (Singapore)
 FRCR (Australia)
 FRCR (New Zealand)
 FRCR (Canada)
 FRCR (USA)
 FRCR (Japan)
 FRCR (South Korea)
 FRCR (Taiwan)
 FRCR (Thailand)
 FRCR (Vietnam)
 FRCR (Philippines)
 FRCR (Malaysia)
 FRCR (Indonesia)
 FRCR (Singapore)

Hemorrhagic Ovarian Cyst
 I was diagnosed with a hemorrhagic ovarian cyst. The doctor said it was a functional cyst and would go away on its own. I was prescribed painkillers and told to rest. After 2 weeks, the pain subsided. I went back to the doctor for a follow-up. He said the cyst had resolved. I am grateful to Dr. Arpit Chopra for his expertise and care.

Dr. Arpit Chopra (Jain)
 M.D. (Gynecology)
 M.Ch. (Gynecology)
 FRCOG (UK)
 FRCR (UK)
 FRCR (Ireland)
 FRCR (Singapore)
 FRCR (Australia)
 FRCR (New Zealand)
 FRCR (Canada)
 FRCR (USA)
 FRCR (Japan)
 FRCR (South Korea)
 FRCR (Taiwan)
 FRCR (Thailand)
 FRCR (Vietnam)
 FRCR (Philippines)
 FRCR (Malaysia)
 FRCR (Indonesia)
 FRCR (Singapore)

Hemorrhagic Ovarian Cyst
 I was diagnosed with a hemorrhagic ovarian cyst. The doctor said it was a functional cyst and would go away on its own. I was prescribed painkillers and told to rest. After 2 weeks, the pain subsided. I went back to the doctor for a follow-up. He said the cyst had resolved. I am grateful to Dr. Arpit Chopra for his expertise and care.

Dr. Arpit Chopra (Jain)
 M.D. (Gynecology)
 M.Ch. (Gynecology)
 FRCOG (UK)
 FRCR (UK)
 FRCR (Ireland)
 FRCR (Singapore)
 FRCR (Australia)
 FRCR (New Zealand)
 FRCR (Canada)
 FRCR (USA)
 FRCR (Japan)
 FRCR (South Korea)
 FRCR (Taiwan)
 FRCR (Thailand)
 FRCR (Vietnam)
 FRCR (Philippines)
 FRCR (Malaysia)
 FRCR (Indonesia)
 FRCR (Singapore)

Fibrocystic breast disease

Also called: fibrocystic breasts

OVERVIEW

SYMPTOMS




TREATMENTS

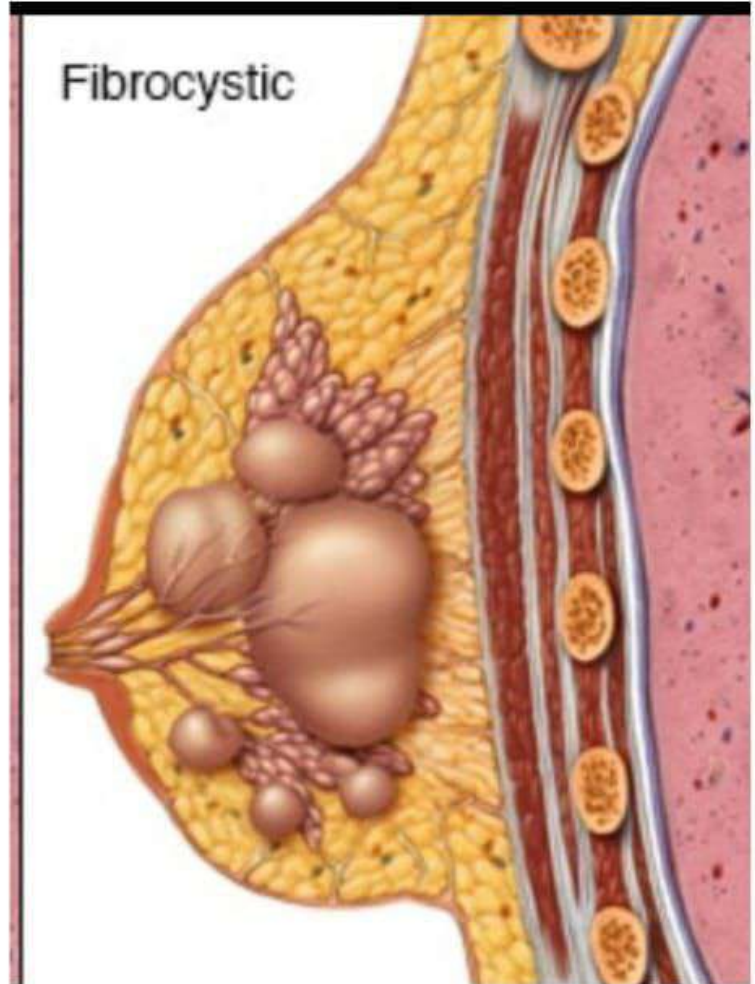
Non-cancerous changes that give a breast a lumpy or ropelike texture.

The condition is likely to be due to hormone changes during the menstrual cycle that affect breast tissue.

Very common

More than 10 million cases per year (India)

-  Treatment can help, but this condition can't be cured
-  Requires a medical diagnosis
-  Lab tests or imaging often required



ACCURATE DIAGNOSTICS
625, Khatiwala Tank, Indore. Phone : 0731 - 2479005, 4001821

- Digital Mammography
- Digital X-Ray
- 21 Channel EEG
- Colour Doppler
- Sonography
- Echo-cardiography
- Pathology
- ECG

Patient's Name: Mrs. Nisha Yadav Age : 44 Yrs. F
Ref. Consultant: Dr. Geeta Sharma Date: 11.07.2019

DIGITAL MAMMOGRAPHY

Bilateral X-ray mammography is performed in both cranio-caudal & medio-lateral views. The markers are placed in outer and upper side respectively. Compression applied.

The right breast parenchyma show increased density in few areas and feathery pattern.

The left breast is normal all over.

No definite cystic solid mass lesion or microcalcifications are seen.

The nipples and areola are free.

The skin and subcutaneous tissues are normal.

No lymph node enlargement is seen.

IMPRESSION: - Mammographic appearances are suggestive of fibroadenosis/mastitis right side. No definite mass lesion is seen.

Adv: Clinical follow up and FNAC if a clinical lump is palpable.

Note - There is no mammographic abnormality of cancer in 5% of the patients diagnosed as benign breast disease or normal by this method.

समर्पण
www.samarpanimaging.com

12-20, Ground Floor, Vashward Plaza,
Opp. Railway Station, Indore (M.P.)
0731- 4068123, 4907633, 98099-35684
samarpanimaging@gmail.com
www.samarpanimaging.com

Pt. Name: MRS. NISHA YADAV Age/Sex: 44 Years /Female
Ref. By: DR. ARPIT CHOPRA Date: 26/Jul/2019

MAMMOGRAPHY OF BOTH BREASTS

Clinical Impression: Pain in right breast.

Low kV, high MAS CR (Digital) X-Ray mammography performed. Medio-lateral 45-degree oblique (MLO) and cranio-caudal (CC) views of both breast taken after adequate compression of the breast parenchyma.

Bilateral breast parenchyma reveals mixed fibro glandular component normal for her age.

Skin, Nipple and subareolar region appears normal.

No obvious calcification or architectural distortion seen.

No evidence of pleomorphic or micro-calcification is noted.

Bilateral axilla - No significant lymph node is seen.

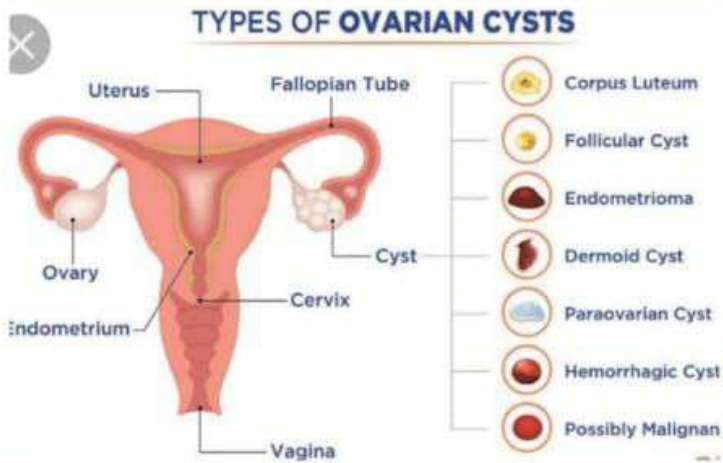
High resolution screening sonography of both breasts reveals normal fibro fatty and glandular tissue.

IMPRESSION:- THE APPEARANCE OF LESION IS INCONSPICUOUS ABNORMALITY AND FALL IN BIRADS ASSESSMENT CATEGORY-I

Note : Not all breast abnormalities show up on mammography. The false negative rates of mammography are approximately 10 % . If you detect a lump or any other change in your breast before your next screening mammogram, consult your doctor immediately.

Triple test, mammography, tissue sampling & clinical breast examinations, has been advocated to evaluate breast abnormalities.

DR. HEMLATA MCGALDA,
MBBS, MD, RADIOLOGIST



Handwritten notes on lined paper, including a list of symptoms and a small diagram of the reproductive system. The notes mention 'Cyst', 'PCOD', and 'Icthyosis vulgaris'.

CRITICAL CASE SPECIALIST
 Reg. No. 14357
 Phone: 0731-4977076, 2532737
 Mobile: 97130 92737, 97130-37737
 79999-78894, 99075 27914
 Website: www.homoeopathy.care.com

102, First Floor, Krishna Tower
 In front of Carewell Hospital
 Janjira Wala Square, INDORE (M.P.)
 Time: Morning 10 am to 3 pm, 5 pm to 10 pm
 Sunday: 11 am to 2 pm
 Email: aptchopra23@gmail.com
 anagyanmodhomoeopathy@gmail.com

Name: Yashika Madi Age: 20 Sex: F Date: 05/09/19
 Address: Ujjain Mob: _____ Ref No: 1708193

Complete, Easy, Safe, Fast & Cost-effective Permanent Modern Homoeopathy Cure With Advanced Lifestyle

They feature & Renal issues, Cancer, Critical & Late stage diseases, ICU & hospitalized Patients, Muscular (Fracture), Thyroid disorder, infertility, Surgical Cases, Impotence, Sexual disorders, Rheumatism, Backache, Sciatica, Migraine, Knee Pain, Diabetes, Breast Tumour & Uterine Fibroid, Prostate & Urological diseases, Renal & Gastrointestinal, Haecditric, Unstable disorder, Mental, Psychiatry & Mood disorder, Accidents & Emergency, Allergic, Homoeopathic, Preventive & Prophylaxis, Tetanus, Allergy (skin diseases, Eczema, Psoriasis, Leucoderma, Acne, Cosmetic disorders, Low Weight, Obesity, Under Weight, Hair Fall, Baldness, Dandruff, Acidity, Gas, indigestion, Piles, Fissure, Hemorrhoids, Gynec. Vices, Worms, Parasitic & Respiratory Disorders, Sinus, Psoriasis, Eczema, Protein, Weakness of memory, Sinusitis, Menstruation, Paediatric, Cardiac, Dentition, Urinary, Rheumatic disorders, Anemia, Weakness, Debility, Anorexia, Tuberculosis, PCOD, Menstrual disorders, Chronic Disorders, Excessive Sweating, Restlessness, Blood Pressure & Heart disorders, Hemorrhoidal hemorrhoids, Medicines, Best cure for Acute diseases like Typhoid, Malaria, Cough, Cold, Flu, Dengue, Cholera, Typhoid, Tetanus, Flu etc.

Handwritten notes on the right side of the page include:
 - PCOD ✓
 - Icthyosis vulgaris ✓
 - Dryness ✓
 - 3.5 x 3.2 cm ✓
 - 05/09/19 ✓
 - Bowel ✓
 - Cut Discharge ✓
 - Hair Fall ✓

USG Whole Abdomen
 Icthyosis
 Bowel
 Cut Discharge
 Hair Fall

(Please Take Appointment Before Consultation if Possible on 97130-37737, 0731-4977076, 79999-78894)

VEDANT DIAGNOSTICS
 4, Varahi Veng, Opp. Mathuragar Police Station, Freeranj, Ujjain 456 010 MP
 Ph: 0731-492456 Email: vedantdiagnostics@gmail.com

Patient Name	Miss. Yashika	Age/Sex	19Y/F	Date	04.09.18
Referred by	Dr. R. Chandwani (M.S, DNB)	OPD/Bed No.	OPD		

ULTRASOUND WHOLE ABDOMEN (FEMALE)

Liver appears normal in size, shape and echotexture. No focal lesion / SOL is seen. No Intrahepatic biliary radicals dilatation is seen. Liver is showing smooth surface & shape margins.

Gall bladder appears normal with anechoic lumen. No sizeable calculus / any other focus is noted in gall bladder lumen. Wall of Gall Bladder is normal in thickness. No percholecystic free fluid is noted.

Portal vein & Common Bile Duct show normal caliber & no sizeable lymph node is seen at the porta.

Pancreas is normal in size and echotexture showing smooth & regular outline. Pancreatic duct is not dilated. No obstructive calcification is noted. Peripancreatic vessels appear normal.

Spleen is normal in size and echotexture. No focal lesion / SOL is seen. Spleenic capsule is showing no sizeable underlying collection / hematoma.

Both kidneys appear normal in size, shape and echogenicity. Corticomedullary differentiation maintained on both sides. Central sinus echoes are not seen on either side, suggestive of no appreciable hydronephrosis. No sizeable calculus / mass lesion / cyst is noted on either side. Perinephric spaces appear clear on both sides. Bilateral supra renal areas appear clear. Bilateral ureters are not visualized (not dilated).

Bilateral psoas muscles appear normal with smooth outline & no detectable collection is seen on either side.

Urinary bladder is normal with anechoic lumen. No sizeable calculus / mass lesion / any other echogenic focus is seen in urinary bladder lumen. Wall of urinary bladder is normal in thickness.

Uterus appears normal in size, is anteverted measures 8.1 x 1.5 x 5.2 cm along the long axis. Endometrial echoes are midline and measures 20mm.

A simple right ovarian cyst of 3.5 x 3.2cm seen. Left polycystic ovary seen.

On screening the right side focus on the evidence of any inflamed appendix / no abnormally dilated bowel loops / matted bowel loops / bowel mass / fluid collection is noted.

No appreciable free fluid is seen in the peritoneal cavity or in either pleural cavity.

DR. SAMRAT GHOSH
DMRD

X-RAY • COLOUR DOPPLER • ECG CARDIOGRAPHY • ADVANCED PATHOLOGY • ECG

Clinic : 2514235, 4370376

KARAN X-Rays, Sonography & Color Doppler Clinic

14, Bhagatji Market opp. vijayaraje school, Freeranj Ujjain - 456001

Pt Name: - Miss Yashika
 Ref. By Dr: - Arpit Chopra. Date - 05/09/2019

Ultrasonography of: - WHOLE ABDOMEN. SCREENING.

Liver: Is normal in size, shape and echotexture. Biliary tree and vasculature are normal. No focal or diffuse pathology seen.

Gallbladder: Is normal in size, shape with smooth walls and nonlithatic.

Pancreas: Is normal in size and texture. CBD is 5 mm.

Spleen: Is normal in size and texture.

Kidneys: Both are normal in size, shape and texture with smooth outlines and normal calyces. Cortical thickness and cortico-medullary differentiation is adequate.

Ureters: Both are normal in upper and lower third.

Bladder: Is normal, with smooth walls and nonlithatic.

Uterus: Is anteverted normal in size, shape with smooth homogenous walls and central endometrial echo. Uterus measures 8 x 4.4 x 3 cm in size. Endometrial echo is 6 mm.

Ovaries: Both are normal in size, shape and texture. Ovaries measures 4 cc in volume. Both ovaries are showing 6 to 8 small cysts of 5 to 7 mm in size.

Cul de sac is clear.
 Bowel loops normal
 RIF clear
 No adenopathy or free fluid seen.

MPRESSION: Polycystic ovaries.

Dr. Suresh Sharma.
DMRD.

GYNAECOLOGICAL DISORDERS

6

1

HEAVY MENSTRUAL BLEEDING

VAGINAL INFECTIONS

5

2

PCOS

PMS

4

3

OVARIAN CYST

FIBROIDS

GYNECOLOGICAL PROBLEMS

- Menstrual Disorders
- Pelvic Inflammatory Disease
- Endometriosis
- Polycystic Ovary Syndrome
- Uterine Fibroids
- Vaginitis
- Ovarian Cysts
- Urinary Incontinence
- Cervical Dysplasia

आरोग्य
AAROGYA

आरोग्य सुपर स्पेशलिटी मॉडर्न होम्योपैथीक क्लिनिक

AAROGYA SUPER SPECIALITY MODERN HOMOEOPATHIC CLINIC

DR. ARPIT CHOPRA JAIN

Address: 101, 102, 103, 104, Krishna Tower, Jangpura Square, in front of Convent Hospital Road, New Palasia, Indore, Madhya Pradesh 472002

Email: arpitchopra23@gmail.com

Dr. Shweta Jain Sonography & Diagnostic Centre

डा. श्वेता जैन

Expertise: Conventional (2D, 3D, 4D) Target Scan/ USG, Gynec Doppler, Breast & Transvaginal Sonography

Patients Name: Mrs. Sakina Khatu
Ref. Dr. Dr. Man. Naveen Gird

Dr. Shweta Jain
MBBS, DNB, DGO, DRCOG
Consultant Gynaecologist & Ultrasonologist

(NG) WHOLE ABDOMEN TVS

Liver is enlarged. In size (16.5 cm) normal in shape and contour. It shows mixed echotexture with coarse visualization of vessels. The focal lesions were. Some are hyperechoic. Others are iso and others. Portal vein & CBD is normal in caliber.

Gall bladder - shows clear lumen, with normal wall thickness. Spleen is normal in size and normal in shape and echotexture. Pancreas is normal in size, shape & echotexture.

Both kidneys are normal in size and normal in shape and echotexture. Cortico-medullary differentiation is maintained. No significant hydronephrosis, renal stones.

Right Kidney - 10.4 x 5.3 x 7.2 cm Left Kidney - 10.5 x 4.2 cm

LB - shows clear lumen with normal wall thickness.

Uterus is anteverted, bulky, size (13.5x8.2x7.2 cm). It shows mixed echotexture with focal echogenicity in uterine cavity.

Both ovaries are normal in size, normal in shape & shows normal echotexture. RFO: 2.7cm x 1.7cm (app. 1.7cm x 7mm size focal echogenicity in uterine cavity).

No significant adhesion/ cysts seen.

- Impression - Mild hepatomegaly with fatty infiltration of liver parenchyma.
- Bulky uterus with mildly heterogeneous echotexture.
- App. 1.5cm x 1.7cm size intramural fibroid seen at left lateral wall of uterus.
- App. 1.7cm x 7mm size focal echogenicity in left ovary.
- App. 1.7cm x 7mm size focal echogenicity in uterine cavity. Its vascularity is likely incomplete shedding of endometrium.
- Kindly correlate clinically.

Before treatment

Dr. SHWETA JAIN

Gandhi Diagnostic Clinic

Dr. S.M. Gandhi, DMRD

Gandhi's Mobile : 93294-39448

Sholnagar Main Road, Opp. Bina Nagar, INDORE

PATIENT - MRS. SALIMA KHUJA DATE - 04/08/2025

AGE: 38A - 41 YRS REF. BY: DR. NEERA GOEL

N.B.S. M.D. INDORE

WHOLE ABDOMEN ULTRASONOGRAPHY REPORT (PRINT)

Liver is normal in size, shape and echotexture. Fatty (Grade - I). No focal lesion seen in liver. // Hepatic surface is smooth.

Gall bladder is normal in size and shape and echotexture. // No calculi seen in gall bladder. Gall bladder wall thickness is normal.

Spleen is normal in size, shape and echotexture. Pancreas is normal in size, shape and echotexture.

Both kidneys are normal in size and shape and echotexture.

Right kidney - 10.0 x 4.4 cm and Left kidney - 10.7 x 5.2 cm.

The renal outline are smooth & regular. The cortical thickness is adequate and.

The Pancreas is normal in echotexture.

No calculi / No calyceal dilatation seen in both kidneys.

Both ureters are unobstructed.

Uterus is anteverted and is mildly enlarged. In size and shape and echotexture is normal.

Vagina size - 8.5 x 5.1 x 4.2 cm. // Ends echo is 4 mm.

Both ovaries are normal in size, shape and echotexture.

Urinary bladder is normal in size and contour. // No calculi seen in urinary bladder.

No free fluid seen in abdomen.

After Dr. Arpit Chopra Jain
Hormonal Investigation

IMPRESSION - FATTY LIVER - (GRADE - I)

- SPLEEN, PANCREAS AND BOTH KIDNEYS ARE NORMAL.

- MILDLY ENLARGED UTERUS.

Dr. S.M. GANDHI DMRD

AAROGYA SUPER SPECIALITY MODERN HOMOEOPATHIC CLINIC





DR ARPIT CHOPRA JAIN
MD HOMOEOPATHY, CRITICAL &
SURGICAL DISEASE SPECIALIST

95872, +91 79999-78894, Call - +91 97130-37737, +91 80451-32033, Websites - www.homeoepat

Description

Ovarian Cyst मरीज पूरी तरह ठीक, Patna, Bihar – Dr Arpit Chopra Jain – Modern Homeopathy

Complete, Permanent, Easy, Safe, Fast & Cost Effective Cure

डॉ. अर्पित चोपड़ा (डॉ. आर्पित चोपड़ा) की: महिलाओं सम्बंधित सभी बीमारियों का सफल इलाज




ALL TYPES OF GYNAECOLOGICAL DISORDERS CURED BY DR. ARPIT CHOPRA JAIN'S MODERN HOMOEOPATHY

FEMALE GYNAECOLOGY DISEASE महिलाओं स्त्री रोग संबंधी CURED BY ...

PATIENTS TESTIMONIALS



डॉ. अर्पित चोपड़ा जैन: एक नाम, जो बना भरोसे और सेवा का पर्याय

डॉ. अर्पित चोपड़ा जैन, आरोग्य सुपर स्पेशलिटी मॉडर्न होम्योपैथिक क्लिनिक


एक नाम जो भरोसे का हिस्सा बन गया है। डॉ. अर्पित चोपड़ा जैन की सेवा का पर्याय बन गया है। डॉ. अर्पित चोपड़ा जैन की सेवा का पर्याय बन गया है। डॉ. अर्पित चोपड़ा जैन की सेवा का पर्याय बन गया है।

डॉ. अर्पित चोपड़ा जैन की सेवा का पर्याय बन गया है।

डॉ. अर्पित चोपड़ा जैन की सेवा का पर्याय बन गया है।

डॉ. अर्पित चोपड़ा जैन की सेवा का पर्याय बन गया है।

Size 35x38 inch

आरोग्य सुपर स्पेशलिटी मॉडर्न होम्योपैथिक क्लिनिक

AAROGYA SUPER SPECIALITY MODERN HOMOEOPATHIC CLINIC

कैंसर, किडनी फेलियर, अस्पताल में गंभीर रूप से भर्ती मरीज का उपचार, कोमा, शल्य चिकित्सा योग्य ऑटोइम्यून रोग, अप्लास्टिक ऐनीमिया, मस्क्युलर डिस्टोफी, जीवन भर दवा लेने वाले रोगों की रोकथाम व 300 प्रकार के असाप जटिल रोगों की चिकित्सा

एक ही डॉ. एक नाम बन गया है। डॉ. अर्पित चोपड़ा जैन की सेवा का पर्याय बन गया है।

Online Consultation Available

9791-887979 | +91 97130-37737 | +91 80451-32033 | +91 80451-32033 | +91 80451-32033 | +91 80451-32033

आरोग्य सुपर स्पेशलिटी मॉडर्न होम्योपैथीक क्लिनिक



ओवरीयन सिस्ट
OVARIAN CYST





DR. ARPIT CHOPRA JAIN
(MD HOMOEOPATHY & CRITICAL & SURGICAL DISEASE SPECIALIST)

जीवनीका सिस्ट आरामक रूप से हटाया है जो जीवनशैली और हार्मोनल असंतुलन से जुड़ी होती है। केटी रिपोर्ट में सिस्ट की जांच कराई गई थी। इससे पहले, पाचन समस्या और वजन में वृद्धि का इलाज हो चुका है।

RESPONDED OVARIAN CYST PATIENT FROM INDORE, MADHYA PRADESH

ADDRESS: 101, 102, 103, 104, KRISHNA TOWER, JANJEERWALA SQUARE, IN FRONT CUREWELL HOSPITAL ROAD, NEW PALASIA, INDORE, MADHYA PRADESH 462001

3:05

Title
Ovarian Cyst 6 cm & Cystadenoma में राहत मिली saved surgery – Dr Arpit Chopra Jain Modern Homoeopathy

Sri Sahayog Hospital & Medical Investigation
New Medical, Regal, Sahayog, Sahayog, Indore, India No. 42001000

NAME: NIMHARICA VERMA AGE: 41 Yrs F
REF BY: DR. BHARTI PATIDAR (MD) DATE: 08/09/2025

PELVIC SONOGRAPHY

UTERINE BLADDER IS NORMALLY DISTENDED WHICH ARE WITH A LUMEN OF 3.5 CM.

UTERUS IS ANTEROVERTED AND IN SIZE 8.5 CM X 5.5 CM X 7.5 CM.

ENDOMETRIUM IS 1.2 CM.

NO FREE FLUID SEEN IN P.A.S.

IMPRESSION:
• AT RESONANCE
• NO FREE FLUID SEEN IN P.A.S.

संज्ञा

EXAMINER NAME: DR. ARPIT CHOPRA JAIN PATIENT ID: 10000000000000000000
REF BY: DR. BHARTI PATIDAR DATE: 08/09/2025

PELVIC SONOGRAPHY (T/F)

UTERINE BLADDER IS NORMALLY DISTENDED WHICH ARE WITH A LUMEN OF 3.5 CM.

UTERUS IS ANTEROVERTED AND IN SIZE 8.5 CM X 5.5 CM X 7.5 CM.

ENDOMETRIUM IS 1.2 CM.

NO FREE FLUID SEEN IN P.A.S.

IMPRESSION:
• AT RESONANCE
• NO FREE FLUID SEEN IN P.A.S.

Mrs.Niharika Verma
Dr.Bharti Patidar

41 Yrs F
08-Sep-2025

MRI PELVIS

Multiphasic, multiecho MR imaging of the pelvis was performed with STIR, T1 and T2W images are obtained in sagittal, axial and coronal planes.

Presence of tampon in lower uterus.

The urinary bladder is distended.

An oval well marginated cystic lesion with small nodule is present in the pelvis right anterolaterally..It shows homogenous fluid signal intensity appear hypointense on T1W images and hyperintense on STIR and T2W images.No abnormal wall thickening of soft tissue contents is seen.It measures appx 44x34x56mmcms. in size

The ovaries are not separately identified.

No iliac, obturator or inguinal lymphadenopathy is seen.

Both hip joint shows normal joint space and articular surfaces. No joint effusion is seen.

IMPRESSION:
An oval well marginated cystic lesion with small nodule in the pelvis right anterolaterally..It shows homogenous fluid signal intensity No abnormal wall thickening of soft tissue contents is seen.It measures appx 44x34x56mmcms. in size .possibly papillary cystadenoma .

A papillary cystadenoma is a rare, benign, epithelial tumor that is characterized by cystic spaces with papillary projections growing into the lumen. It most often arises in the salivary glands or the epididymis but can also occur in other organs. The prognosis for patients with this tumor is generally excellent.

आरोग्य सुपर स्पेशलिटी मॉडर्न होम्योपैथीक क्लिनिक
AAROGYA SUPER SPECIALITY MODERN HOMOEOPATHIC CLINIC

INDORE, MADHYA PRADESH

ADDRESS: 101, 102, 103, 104, KRISHNA TOWER, JANJEERWALA SQUARE, IN FRONT CUREWELL HOSPITAL ROAD, NEW PALASIA, INDORE, MADHYA PRADESH 462001

DR. ARPIT CHOPRA JAIN

डॉ. अर्पित चोपड़ा (जैन) मॉडर्न होम्योपैथी: महिलाओ सम्बंधित गंभीर बीमारियों का सफल इलाज



DR. ARPIT CHOPRA JAIN

• डॉ. अर्पित चोपड़ा (जैन) को सेल्फी व अलगाव वाली को सफलता प्राप्तियां प्राप्त करतीं इलाज किया गया।

ALL TYPES OF GYNAECOLOGICAL DISORDERS CURED BY DR. ARPIT CHOPRA JAIN'S MODERN HOMEOPATHY

ONLINE CONSULTATION AVAILABLE : WWW.HOMOEOPATHYCLINIC.IN / WWW.AAROGYAHOMEOPATHYINDORE.COM

Description

मरीज को राहत - Fatty Liver & Ovarian Cyst - Dr Arpit Chopra Jain Homeopathy

Successfull treatment by Modern Homeopathy

Fatty Liver Patient From Indore Treatment at Dr. Ar...

Fatty Liver Grade 3 | Cured by Dr. Arpit Chopra's Supe...

आरोग्य सुपर स्पेशलिटी मॉडर्न होम्योपैथी क्लिनिक

Fatty Liver & Liver diseases यकृत संबंधित Cured Responed by Dr

आरोग्य सुपर स्पेशलिटी मॉडर्न होम्योपैथी क्लिनिक

AAROGYA SUPER SPECIALITY MODERN HOMOEDPATHIC CLINIC

0733-4977076 | 91 78999-78994 | 91 97130-92727 | 91 84904-95872 | 91 97076-27854 | 91 97130-37723, 980451-32138, 91 7828328823

DR. ARPIT CHOPRA JAIN

DR. ARPIT CHOPRA JAIN
M.D. (HOMOEOPATHY) & DIPLOMA IN
HOMOEOPATHY (CONSTITUTIONAL)

3:05

ADDRESS: 101, 102, 103, KRISHNA TOWER, JALJEERWALA SQUARE, IN FRONT
CUREWELL HOSPITAL ROAD, NEW DELHI, INDIA. RAJYTA PRASAD 80083

Title
Ovarian Cyst Patient को मिला Relief
- Dr Arpit Chopra Jain Aarogya
Super Speciality Modern
Homeopathy

डॉ. अर्पित चोपड़ा (जैन) मॉडर्न होम्योपैथी: महिलाओं सम्बंधित गंभीर बीमारियों का सफल इलाज

DR. ARPIT CHOPRA JAIN

ALL TYPES OF GYNAECOLOGICAL DISORDERS
CURED BY DR ARPIT CHOPRA JAIN'S MODERN HOMEOPATHY

ONLINE CONSULTATION AVAILABLE : WWW.HOMEOPTAINDIA.IN/ / WWW.AAROGYAHOMEOPTAINDIA.COM

DR. ARPIT CHOPRA JAIN
M.D. (HOMOEOPATHY) & DIPLOMA IN
HOMOEOPATHY (CONSTITUTIONAL)

Specialty: Diabetes, Asthma, Allergies, Skin Diseases, Gynaecology, Cancer, Stroke & Bone Diseases (Fracture)

Description

मरीज को राहत - Fatty Liver &
Ovarian Cyst - Dr Arpit Chopra

DR. ARPIT CHOPRA JAIN
M.D. (HOMOEOPATHY) & DIPLOMA IN
HOMOEOPATHY (CONSTITUTIONAL)

98472, +91 79990 79994, Call : +91 97130 37727, +91 80491 32933, Website : www.homoeopta.com

Description

Ovarian Cyst मरीज पूरी तरह
ठीक, Patna, Bihar - Dr Arpit
Chopra Jain - Modern
Homeopathy

आरोग्य
सुपर स्पेशलिटी
होम्योपैथिक क्लिनिक

DR. ARPIT CHOPRA JAIN
M.D. (HOMOEOPATHY) & DIPLOMA IN
HOMOEOPATHY (CONSTITUTIONAL)

AAROGYA SUPER SPECIALITY MODERN HOMOEOPATHIC CLINIC

कैंसर, किडनी फेलियर, अस्पताल में गंभीर रूप से भर्ती मरीज का उपचार,
कोमा, शल्य चिकित्सा योग्य ऑटोइम्यून रोग, अप्लास्टिक रैनीमिया,
मस्कुलर डिस्टॉफी, जीवन भर दवा लेने वाले रोगों की रोकधाम
व 300 प्रकार के असाध्य जटिल रोगों की चिकित्सा

जगदी कोर्दे अथवा शायद नहीं है | जीवित रहने में सक्षम रहें | Online Consultation Available

☎ 011-4977076 | C +91 97130 37727, +91 80491 32933
+91 98475 21944, +91 97130 82787, +91 97130 87727, +91 93426 06472, +91 79990 79994

www.homoeopta.com | www.aarogyahomoeopta.com | www.homoeoptaindia.com | [Email: info@aarogyahomoeopta.com](mailto:info@aarogyahomoeopta.com)

101, 102, 103, 104 KRISHNA TOWER, JALJEERWALA SQUARE, NEARBY IN CUREWELL HOSPITAL ROAD NEW DELHI, INDIA - 110011 (IN)

08:54

मॉडर्न होम्योपैथी
Modern Homoeopathy - Complete, Safe, Fast & Cost-Effective



OBESITY

Dr. Arpit Chopra (Jain) **AAROGYA SUPERSPECIALITY MODERN HOMEOPATHY CLINIC**
COMPLETE, SAFE, FAST & COST-EFFECTIVE MODERN HOMEOPATHY CURED WITH ADVANCED LIFESTYLE
Phone: 0731-4977076, Mobile: 97130-92737, 97130-37737, 79999-78094, For Whatsapp: 99075-27914

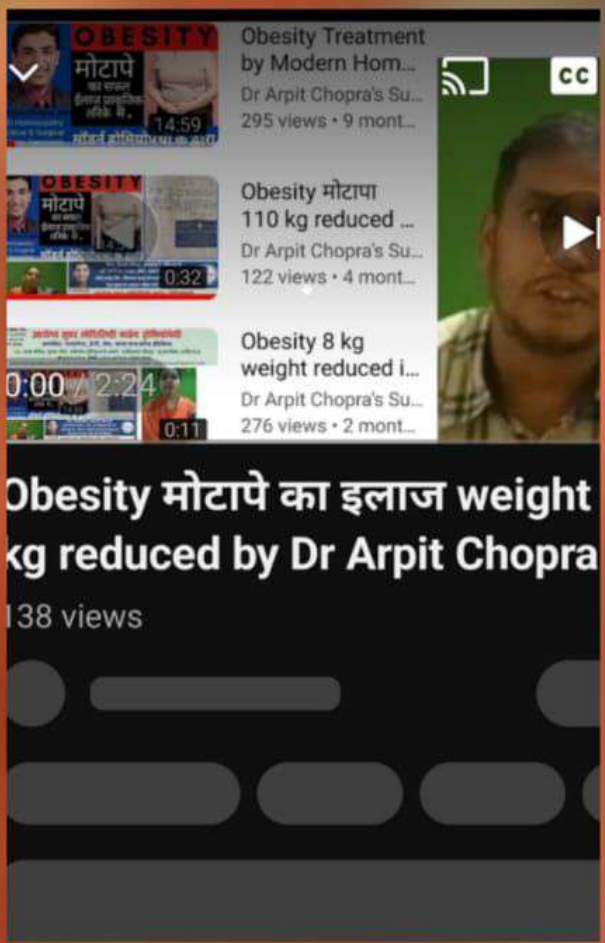
IRITIS, SPINALSTENOSIS, SLIPDISC (PIVD), LIVER CIRRHOSIS

Obesity Treatment मोटापे का इलाज.
 @drarpitchopraiaain 963 views 3 yr ago ...more



first I was very worried about weight gain

Obesity मोटापा 110 kg reduced
 @drarpitchopraiaain 158 views 3 yr ago ...more



OBESITY Obesity Treatment by Modern Hom...
 मोटापे 14:59 295 views • 9 mont...

OBESITY Obesity मोटापा 110 kg reduced ...
 मोटापे 0:32 122 views • 4 mont...

OBESITY Obesity 8 kg weight reduced i...
 0:00 / 2:24 0:11 276 views • 2 mont...

Obesity मोटापे का इलाज weight 110 kg reduced by Dr Arpit Chopra
 158 views



Obesity 8 kg weight reduced in ...
 @drarpit...prajain Analytics
 Public · 519 views

5 Dislike 0 Share Remix



A collage of six photographs showing Dr. Arpit Chopra and his family receiving awards and participating in events. The photos include a group photo with a framed portrait, a man in a suit presenting a plaque, a woman in a red dress, and a group of people on a stage.



आरोग्य
सुपर स्पेशलिटी

आरोग्य सुपर स्पेशलिटी मॉडर्न होम्योपैथिक क्लिनिक
AAROGYA SUPER SPECIALITY MODERN HOMOEOPATHIC CLINIC

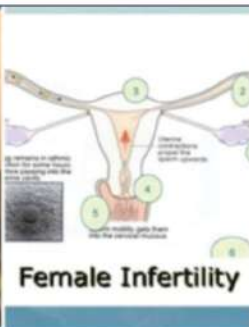
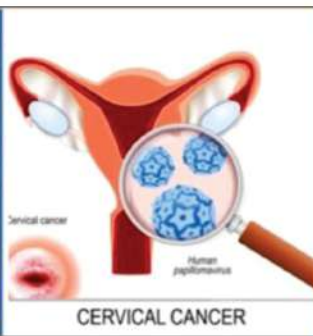
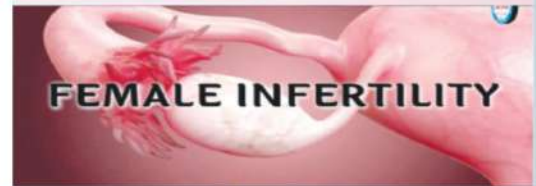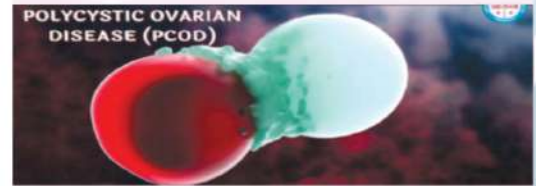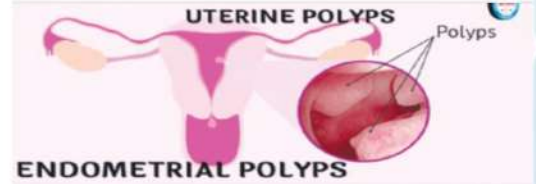
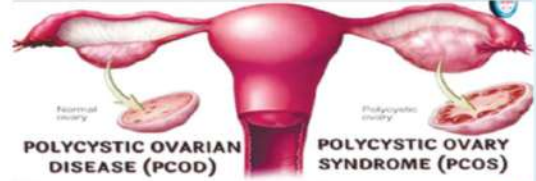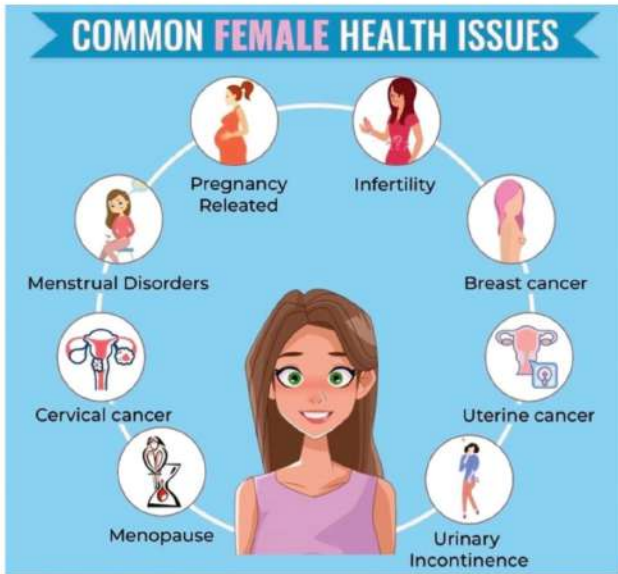
कैंसर, किडनी फेलियर, अस्पताल में गंभीर रूप से भर्ती मरीज का उपचार, कोमा, शल्य चिकित्सा योग्य ऑटोइम्यून रोग, अप्लास्टिक ऐनीमिया, मस्कलर डिस्टॉफी, जीवन भर दवा लेने वाले रोगों की रोकथाम व 300 प्रकार के असाध्य जटिल रोगों की चिकित्सा

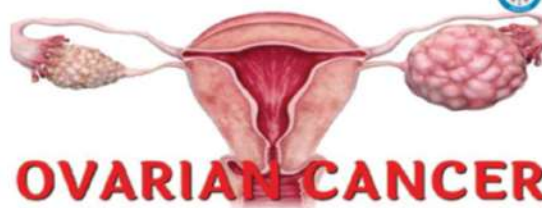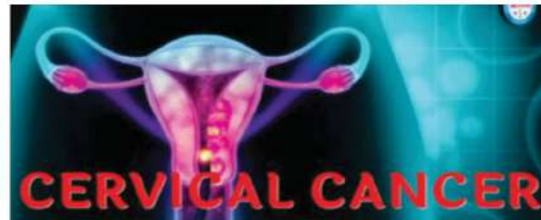
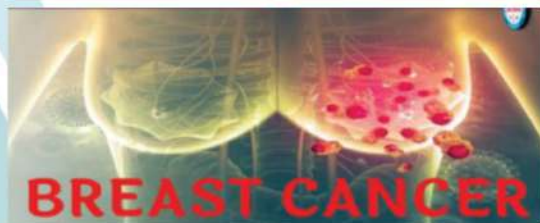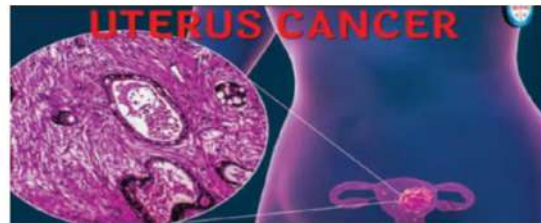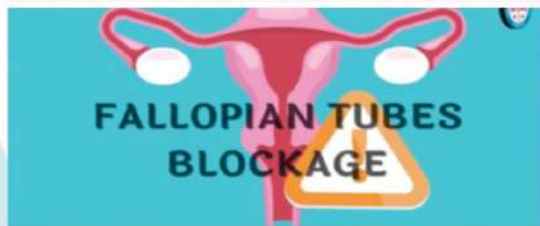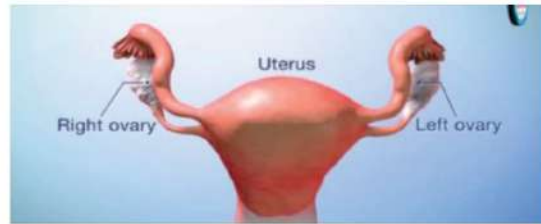
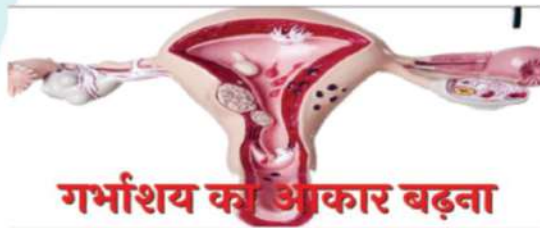हमारी कोई अन्य शाखा नहीं है | डॉ. कॉल से सलाहदान रहे | Online Consultation Available

0731-4977076 | +91 97130-37737, +91 80451-32033
 +91 99075-27914, +91 97130-92737, +91 97130-37737, +91 93404-95872, +91 79999-78094

www.aarogyahomoeopathy.com, www.aarogyahomoeopathyindia.com, www.aarogyahomoeopathyindia.com | Email: arpit@aarogyahomoeopathy.com

101, 102, 103, 104, KRISHNA TOWER, JALJEERWALA SQUARE, INFRONT OF CUREWELL HOSPITAL ROAD, NEW PALASIA, INDORE - 452001 IN





 Khushiwari Sabu Raipur Garhwal, C.G.	 FALLOPIAN TUBE BLOCKAGE	 before treatment after treatment	 Maya Tank Indore (M.P.)	 Fibroadenoma	
 Jasminda Ben Quermah Raipur, M.P.	 UTERINE POLYPS		 Neha Kushwah Dewas, M.P.	 Ovarian Cyst	
 Indu Verma Indore (M.P.)	 UTERINE FIBROIDS		 Sani Bai Indore, M.P.	 CERVICAL CANCER	
 Yashika Laxmi Raipur, M.P.	 Ovarian Cyst		 Rosalini Sarkar Raipur, M.P.	 BULKY UTERUS	



Service Project Infrastructure: Making Medical Care Accessible to All

"Medical facilities should be accessible to the common man in every way." Dr. Arpit Chopra Jain

To make his groundbreaking medical invention available to the general public, Professor Dr. Arpit Chopra Jain has established the Aarogya Super Speciality - Modern Homoeopathy Clinic, equipped with state-of-the-art facilities, at Janjirwala intersection in the heart of Indore city. At this clinic, patients have access to comprehensive consultation, diagnosis, and treatment for various diseases, all under one roof.

In addition, a dedicated consultation room for online patients has been set up to offer virtual consultations. Medicines are delivered through courier services, ensuring that even the most serious conditions can be treated from the comfort of one's home. Dr. Arpit Chopra Jain's initiative ensures that high-quality healthcare is not just limited to in-person visits but is also accessible to those in distant locations.



Dr. Arpit Chopra Jain: A Commitment to Service and Responsibility

Dr. Arpit Chopra Jain, raised in a family of doctors, embodies the true essence of a dedicated medical professional. With a deep sense of responsibility toward human welfare, he has revolutionized healthcare through his groundbreaking invention of Super Speciality Modern Homoeopathy treatment. His work has provided a new direction in treating complex diseases, ensuring that even those who once felt hopeless have found relief.

campaign to combat sickle cell anemia, Dr. Arpit Chopra Jain is also working tirelessly in tribal areas. His efforts contribute significantly to the permanent and successful treatment of this genetic disorder, further reflecting his unwavering commitment to the welfare of humanity.



Dr. Arpit Chopra Jain also organizes medical camps aimed at diagnosing complex diseases, providing free consultations to those in need. His sense of duty was especially evident during the devastating COVID-19 pandemic, where he took extraordinary measures to help his community. Understanding the gravity of the situation, he distributed free Corona prevention medicines to approximately 2,25,000 people, including Corona Warriors, potentially saving many lives.





Dr. Arpit Chopra Jain exemplifies what it means to be a physician who balances medical practice with social responsibility, continuing to make a profound impact on both individual lives and society as a whole.



Recognizing the significance of his role, Dr. Arpit Chopra Jain extends his responsibilities beyond medical practice. He considers it his moral and national duty to contribute to various social service activities. Along with treating complicated medical conditions, Dr. Arpit Chopra Jain is committed to shaping the future of homoeopathy. He actively mentors and educates new students entering the field, helping them gain the knowledge necessary to advance in medical science.





Samman Awards: A Tribute to Responsibility and Service

"Respect received from society increases responsibility." Dr. Arpit Chopra Jain

Dr. Arpit Chopra Jain believes that when one contributes responsibly and at the right time, society offers its respect. However, with that respect comes an even greater sense of responsibility.

Dr. Arpit Chopra Jain, through his groundbreaking invention of the Arogya Super Speciality Modern Homoeopathy medical system and his numerous social contributions, has garnered widespread recognition. His dedication to improving the health and well-being of others has not gone unnoticed. He has been honored by many prominent ministers, intellectuals, and senior artists across various dignified platforms. These awards have been bestowed upon him by social, national, and international institutions, further acknowledging his remarkable contributions to the field of medicine and humanity.

This recognition only fuels Dr. Arpit Chopra Jain's determination to continue serving society with even greater dedication and responsibility.

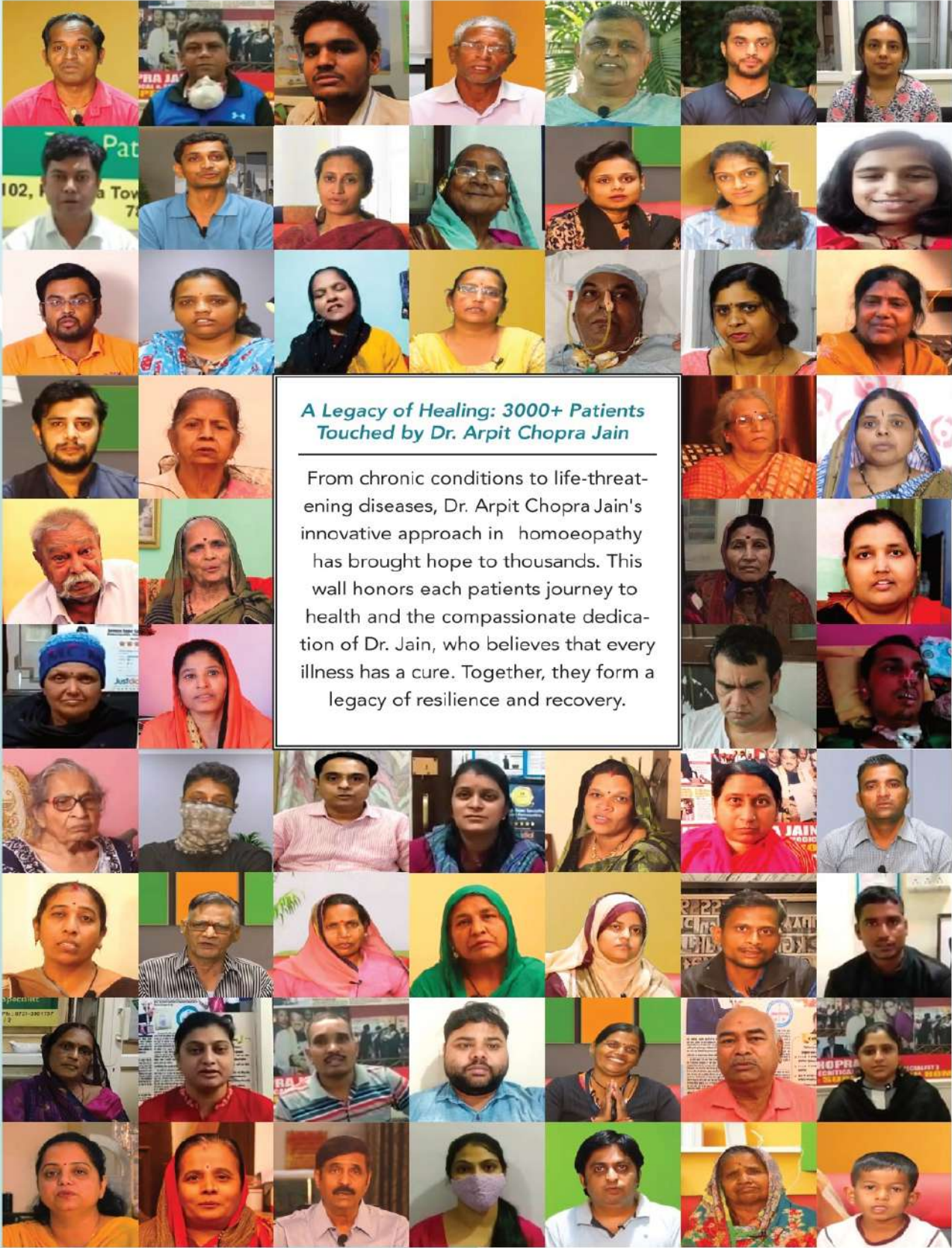











A Legacy of Healing: 3000+ Patients Touched by Dr. Arpit Chopra Jain

From chronic conditions to life-threatening diseases, Dr. Arpit Chopra Jain's innovative approach in homoeopathy has brought hope to thousands. This wall honors each patients journey to health and the compassionate dedication of Dr. Jain, who believes that every illness has a cure. Together, they form a legacy of resilience and recovery.



From Despair to Recovery: Celebrating 3000+ Success Stories

Behind every photo is a story of resilience and recovery made possible through Dr. Arpit Chopra Jain's pioneering work in modern homoeopathy. This wall is a celebration of his innovative treatment approach at Aarogya Super Speciality, which has empowered thousands to reclaim their health and live fuller lives.



Thank
You!



Possible solutions to complex, incurable and impossible diseases. Harmless, quick, economical and permanent treatment system, Homoeopathy of the future, Thank you for giving your valuable time to Super Speciality Modern Homoeopathy treatment system.


May you always live a happy life by staying physically,
mentally and socially healthy and fulfill the WHO standards


This is my wish, This is my effort...

Aarogya Super Speciality Modern Homoeopathy

101-104, First Floor, Krishna Tower, Opposite Curewell Hospital
New Palasia, INDORE (M.P.)

ONLINE CONSULTATION ALSO AVAILABLE

 @ 99075-27914, 79999-78894
@ 97130-92737, 97130-37737

 aarogya101

 [instagram.com/aarogyahomeopathy](https://www.instagram.com/aarogyahomeopathy)

 www.aarogyahomeopathyindore.com

www.aarogyahomeopathyindore.com
www.homoeopathycure.in
besthomoeopapathdoctorind.com

email : arpitchopra23@gmail.com, aarogyamodernhomeopathy@gmail.com

You Tube Link  - [drarpitchopramodernhomeopathic](https://www.youtube.com/channel/UCdrarpitchopramodernhomeopathic)